

## Case Report

# Labile Hypertension Associated with Testosterone Treatment in a Young Female-To-Male Transsexual

Francisco Javier Martinez-Martin<sup>1\*</sup>, Claudia Arnas-Leon<sup>2</sup>, Carmen Acosta-Calero<sup>2</sup> and Esperanza Perdomo-Herrera<sup>3</sup>

<sup>1</sup>Department of Endocrinology, Clinica San Roque, Spain

<sup>2</sup>Department of Endocrinology, Hospital Universitario de Gran Canaria Doctor Negrin, Spain

<sup>3</sup>Department of Family and Community Medicine, Las Palmas de Gran Canaria, Spain

**\*Corresponding author**

Francisco Javier Martinez-Martin, Endocrinology Dpt, Clinica San Roque, Dolores de la Rocha 5, 35001 Las Palmas de Gran Canaria, Spain. Tel: 34 928 012 615, E-mail: dr.j.martinez@gmail.com

Submitted: 04 November 2014

Accepted: 21 November 2014

Published: 26 November 2014

**Copyright**

© 2014 Martinez-Martin et al.

**OPEN ACCESS****Keywords**

- Testosterone
- Cross-sex hormonal treatment
- Female-to-male transsexual
- Hypertension
- Adjustment disorder

**Abstract**

Testosterone treatment in female-to-male transsexuals has been associated with worsened cardiovascular risk factors and more rarely with the onset of hypertension.

We present the case of a 17-year old transsexual patient referred for initiation of testosterone treatment. A low initial dose (20 mg daily as a topical gel) elicited mild transient mood changes (increased libido, occasional aggressive ideation) without blood pressure elevation. After increasing the dose to 40 mg, the patient presented bouts of anger, aggression proneness, and coincidentally headache and hypertensive episodes. Secondary hypertension was ruled out and Ambulatory Blood Pressure Monitoring showed blood pressure peaks up to 192/113 mm Hg, with tachycardia up to 123 bpm and a mean activity blood pressure of 138/87 mm Hg. The patient was diagnosed of Adjustment Disorder, received short-course psychotherapy and testosterone was withdrawn. After one month, the mood disorder had abated, without new episodes of headache and hypertension. A second Ambulatory Blood Pressure Monitoring showed no hypertensive peaks with a mean activity blood pressure of 124/71 mm Hg. According to the patient's wishes, low-dose testosterone treatment was reinstated with a scheduled slow dose progression; So far, the patient remains asymptomatic and normotensive.

In conclusion, our patient suffered hypertensive episodes in the context of an Adjustment Disorder associated with testosterone treatment. Withdrawing testosterone resolved both the Adjustment Disorder and the hypertensive episodes. We consider that the increased blood pressure was not a direct consequence of testosterone, but an indirect result mediated by untoward psychological reactions of the patient.

**ABBREVIATIONS**

ABPM: Ambulatory Blood Pressure Monitoring; EKG: Electrocardiogram; FTMT: Female-To-Male Transsexual; FSH: Follicle-Stimulated Hormone; HDL: High Density Lipoprotein; CI: Confidence Interval; ICD-10: International Classification Of Diseases, 10<sup>th</sup> Revision; LH: Luteinizing Hormone.

**INTRODUCTION**

Testosterone is the recommended cross-sex hormone treatment for female-to-male transsexuals [1] and is generally safe and well-tolerated [1-8]. Besides the expected cosmetic changes (increased facial and body hair, muscle mass, etc.), testosterone

is frequently associated with acne and occasionally male-pattern baldness [9, 10]. Another frequent side effect of the treatment is aggression proneness and aggressive ideation -but rarely actual aggression- and increased libido [4,10]. The cardiovascular risk profile may be worsened [3,6,11] (with increased body mass index and abdominal adiposity, insulin resistance with low HDL-cholesterol and hyper triglyceridemia, increased hematocrit, homocysteine and C-reactive protein, onset or worsening of sleep-apnea) but the risk of mortality and cardiovascular events is reportedly not higher than in the general population [2,7,8]. Androgens may cause mild sodium retention [4] and in some cases, the onset of hypertension has been described [10] but in most patients there is no increase in blood pressure [4,9].

Hereby, we present the case of a young female-to-male transsexual (FTMT) who developed reversible hypertension related to testosterone treatment in the context of an Adjustment Disorder.

## CASE PRESENTATION

A 17 year-old FTMT patient was referred to our Endocrinology Clinic for cross-sex hormone treatment, after his presumptive diagnosis of Gender Identity Disorder (ICD-10 F64.0) had been confirmed and associated psychopathology excluded. The patient had unremarkable personal history, with menarche at 12 years and 6 months and regular menses afterwards. He had never received hormonal treatment previously.

The physical examination revealed a normal development of secondary sexual female characteristics and mild hirsutism without additional findings. The weight was 57 kg, height 166 cm, blood pressure 128/72 mm Hg and heart rate 76 bpm.

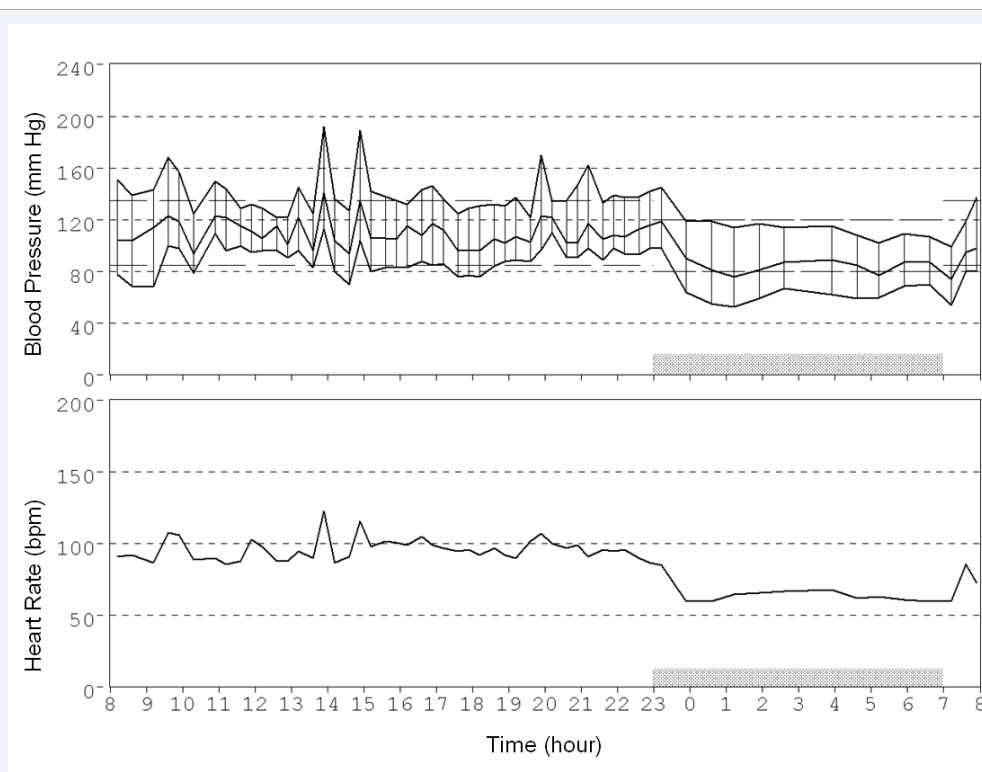
Routine blood chemistry was normal. The hormonal profile, including LH, FSH, 17- $\beta$ -estradiol, dehydroepiandrosterone sulphate, 17- $\alpha$ -hydroxiprogesterone,  $\Delta$ -4-androstendione and prolactin was normal for a female in follicular phase. The karyotype was 46 XX without anomalies.

According to the current guidelines<sup>1</sup>, the patient began testosterone treatment with 20 mg daily, using topical 1% gel. During the first month he noticed increased facial and body hair, but also mild facial acne, increased libido and minor irritability, with occasional hostility and aggressive ideation, but without

inadequate behavior. These symptoms improved after the first month, and three months later the dose was increased to 40 mg daily.

Immediately after starting the higher dose, the patient recounted a worsened irritability, bouts of anger and aggressive ideation, and in a few occasions had inadequate behavior with verbal aggression, which was "quite out of character for himself" in the patient's own words. Additionally, he had episodes of non-pulsatile holocraneal headache without vegetative symptoms, which according to the patient were associated with stressful situations and bouts of anger. During the headache episodes, high blood pressure was recorded twice, with systolic blood pressure in the 170-180 mm Hg range, and diastolic blood pressure about 90-100 mm Hg.

A workup of secondary hypertension was performed, including EKG, chest x-ray, abdominal ultrasonography, plasma renin activity, aldosterone, metanephrine and normetanephrine without any pathological findings. The routine blood chemistry was normal. The hormone profile was LH 1.6 mUI/mL, FSH 1.9 mUI/mL, 17- $\beta$ -estradiol 26 pg/mL, prolactin 18 ng/mL and free testosterone 9.7 ng/dL (concordant with a normal male profile). A 24-hour ABPM was performed (Figure 1) with a Space Labs 90207 device, showing several diurnal blood pressure peaks ranging up to 192/113 mm Hg, with simultaneous tachycardia up to 123 bpm. In the waking period, the mean pressure was 138/87 mm Hg and the mean heart rate was 93 bpm; in the sleep period, they were 116/67 mm Hg and 66 bpm respectively; the circadian profile was dipper. According to the patient's record,



**Figure 1** Systolic, mean and diastolic blood pressure (upper panel) and heart rate (bottom panel) in a female-to-male transsexual patient who reported hypertensive episodes after increasing the testosterone treatment dose from 20 mg to 40 mg daily. As reported by the patient, the observed peaks in blood pressure and heart rate are coincident in time with feelings of anger, hostility and aggressive mood.

the blood pressure peaks were coincident in time with anger and aggressive mood.

The patient was diagnosed of Adjustment Disorder (ICD-10 F43.2) without associated psychopathology. He received brief psychotherapy but no medication; testosterone was temporarily withdrawn. After one month without hormone treatment, the patient felt calmer without aggressive ideation or inadequate behavior.

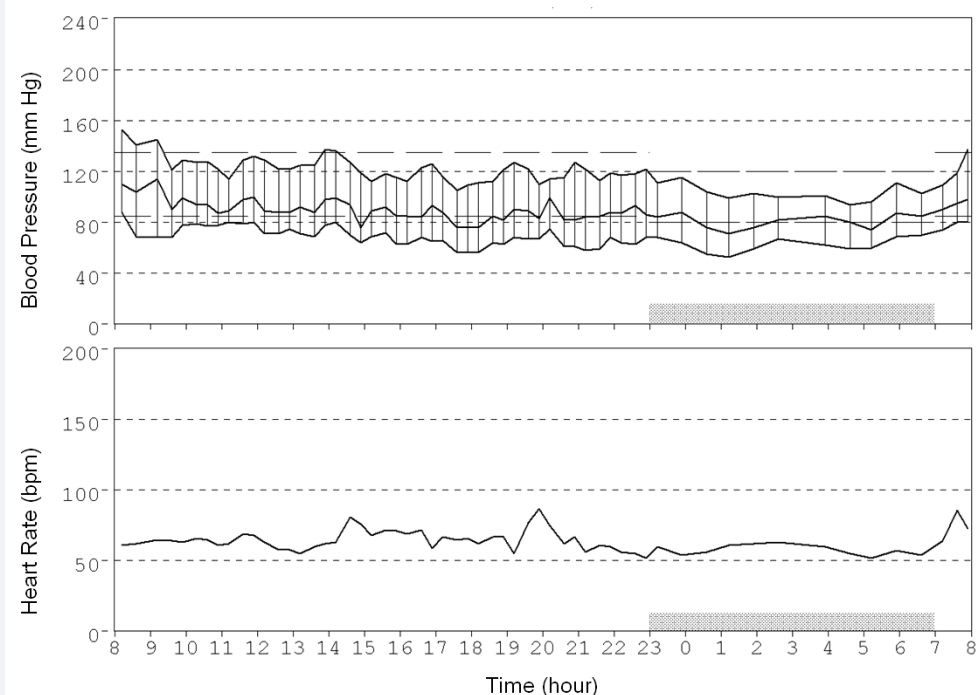
A new ABPM was performed (Figure 2), showing no high blood pressure peaks. In the waking period, the mean pressure was 124/71 mm Hg and the mean heart rate was 65 bpm; in the sleep period, they were 105/64 mm Hg and 58 bpm respectively; the circadian profile was dipper.

However the patient was very keen on reinstating the hormonal treatment. Low-dose testosterone treatment was reintroduced, beginning with 10 mg daily; he was instructed to increase the dose in a slowly progressive fashion according to tolerance, with 10 more mg every two months up to the target dosage of 50 mg daily, but avoiding the dose increase in case of aggressive ideation, inadequate behavior, headache or hypertension. Two months afterwards, the patient felt well adjusted and asymptomatic, and the dose was increased to 20 mg daily. After the increase, he remains normotensive and free from any Adjustment Disorder symptoms.

## DISCUSSION

Men's life expectancy is shorter than women's, in which the adverse effects of testosterone on cardiovascular risk factors might conceivably play a role [12]. A meta analysis of 27 randomized trials of testosterone replacement vs. placebo

in 2,994 (middle-aged or elderly) hypogonadal men reported that treatment resulted in significantly increased cardiovascular morbidity (odds-ratio 1.54, 95 % CI 1.09 - 2.18) [13] and mortality (odds-ratio 1.42; 95 % CI 0.70 - 2.89) [13]. However, a more recent and comprehensive meta analysis [14] including 75 randomized trials and 5464 patients, found that testosterone replacement was not related to any significant increase in cardiovascular events (odds-ratio 1.01, 95 % CI 0.57 - 1.77,  $p = 0.98$ ) or mortality (odds-ratio 1.14, 95 % CI 0.49 - 2.66,  $p = 0.76$ ), and that in trials performed in subjects with metabolic diseases a significant reduction in cardiovascular risk was observed (odds-ratio 0.19, 95 % CI 0.04 - 0.85,  $p = 0.03$ ) [14]. The available data on mortality and cardiovascular morbidity in testosterone-treated FTMT do not support an increased risk [2, 7], and in fact an inverse relationship between testosterone and CVD risk seems to exist in women [15]. On the other hand, the cardiovascular risk of male-to-female transsexuals seems to be increased [8] in spite of the presumed protective role of estrogens [16], mainly due to the increased thrombotic risk associated with this therapy (particularly with oral ethinyl estradiol) [7,8], although non-cardiovascular factors may also be implied. A large recent cohort study reported a significantly increased mortality (1.51 compared to the general population; 95% CI: 1.47-1.55) in estrogen-treated female-to-male transsexuals, but no significant change in testosterone-treated MTFT (1.12; 95% CI: 0.87-1.42) [7]. Extensive data from the British General Practice Research Database and the Health Improvement Network show no increased risk of cardiovascular events (stroke, myocardial infarction, thrombosis) hepatitis or cancer in testosterone-treated women, while the risk of androgenic events (acne, hirsutism, hoarse voice) was increased [17].



**Figure 2** Systolic, mean and diastolic blood pressure (upper panel) and heart rate (bottom panel) in a female-to-male transsexual patient after 1-month withdrawal from testosterone treatment. No episodes of anger, hostility or aggressive mood were reported during the procedure.

Elevated blood pressure has been reported in FTMT treated with testosterone and could be attributed to sodium and fluid retention [4]. The onset of hypertension has occasionally been reported, but only rarely required withdrawal [18]. In one Brazilian cohort study up to 25% of the patients developed hypertension [10], but this is an unusual finding. In most studies the changes in blood pressure were trivial [2, 4- 6, 18] and the incidence of hypertension was not greater than in the general population (12 of 293 subjects with a mean follow-up period over 10 years) [2]. In a recent meta analysis of 16 studies including 651 FTMT subjects, a mean increase of 1.74 mm Hg of systolic blood pressure was reported [6]. In a cohort of 74 FTMT, the mean systolic and diastolic blood pressures were slightly but significantly decreased after 3-4 months of testosterone treatment (by 4.6 and 2.1 mmHg, respectively) [9]. Although it has been suggested [19] that the presentation of male pattern baldness may be associated with higher blood pressure and cardiovascular risk, the available data in MTFT do not confirm this supposition [9].

Mood changes (including increased libido, hostility, anger proneness and aggressive ideation) are common in FTMT patients, but actual aggressive behavior is unusual [3] and only rarely the withdrawal of testosterone treatment is warranted [20]. However, when our patient received a dose of testosterone high enough to reach the hormonal levels of a biological male, he presented an untoward psychological reaction which was diagnosed as Adjustment Disorder. This disease is frequent in adolescents facing sexuality issues, and is marked by untoward mood changes (including sadness, nervousness, anxiety, etc.) and behavioural problems (including fighting, avoiding family and friends, poor performance in school or work, etc.) that occur in response to an identifiable psychosocial stressor [21]. In the context of this reaction, the patient suffered hypertensive episodes which were associated with headache and tachycardia and were coincident in time with bouts of anger and aggressive ideation or verbal aggression. In our opinion, the increase in blood pressure was not directly caused by testosterone, but a consequence of the mood changes (induced at least in part by the hormonal treatment). The episodic character of the blood pressure elevations and the coincidence in the ABPM record of the blood pressure peaks with self-reported bouts of anger support this conclusion; On the other hand, a direct effect of testosterone might presumably have resulted in sustained hypertension.

In conclusion, we present the case of a FTMT patient who suffered hypertensive episodes in the context of an Adjustment Disorder associated with testosterone treatment. The ABPM record supports the diagnosis of hypertension, as his waking blood pressure was > 135/85 mmHg [22], but the key feature in the ABPM tracing are the blood pressure peaks which were coincident with mood alterations. The temporary withdrawal of testosterone treatment resulted in resolution of both the Adjustment Disorder and the hypertensive episodes. We consider that the increased blood pressure was not a direct consequence of testosterone, but an indirect result mediated by the untoward psychological reactions of the patient.

## REFERENCES

1. Hembree WC, Cohen-Kettenis P, Delemarre-van de Waal HA, Gooren LJ, Meyer WJ 3rd, Spack NP, Tangpricha V . Endocrine treatment of transsexual persons: an Endocrine Society clinical practice guideline. See comment in PubMed Commons below J Clin Endocrinol Metab. 2009; 94: 3132-3154.
2. van Kesteren PJ, Asscheman H, Megens JA, Gooren LJ . Mortality and morbidity in transsexual subjects treated with cross-sex hormones. See comment in PubMed Commons below Clin Endocrinol (Oxf). 1997; 47: 337-342.
3. Gooren LJ, Giltay EJ . Review of studies of androgen treatment of female-to-male transsexuals: effects and risks of administration of androgens to females. See comment in PubMed Commons below J Sex Med. 2008; 5: 765-776.
4. Gooren LJ, Giltay EJ, Bunck MC . Long-term treatment of transsexuals with cross-sex hormones: extensive personal experience. See comment in PubMed Commons below J Clin Endocrinol Metab. 2008; 93: 19-25.
5. Traish AM, Gooren LJ . Safety of physiological testosterone therapy in women: lessons from female-to-male transsexuals (FMT) treated with pharmacological testosterone therapy. See comment in PubMed Commons below J Sex Med. 2010; 7: 3758-3764.
6. Elamin MB, Garcia MZ, Murad MH, Erwin PJ, Montori VM . Effect of sex steroid use on cardiovascular risk in transsexual individuals: a systematic review and meta-analysis. See comment in PubMed Commons below Clin Endocrinol (Oxf). 2010; 72: 1-10.
7. Asscheman H, Giltay EJ, Megens JA, de Ronde WP, van Trotsenburg MA, Gooren LJ . A long-term follow-up study of mortality in transsexuals receiving treatment with cross-sex hormones. See comment in PubMed Commons below Eur J Endocrinol. 2011; 164: 635-642.
8. Gooren LJ, Wierckx K2, Giltay EJ2 . Cardiovascular disease in transsexual persons treated with cross-sex hormones: reversal of the traditional sex difference in cardiovascular disease pattern. See comment in PubMed Commons below Eur J Endocrinol. 2014; 170: 809-819.
9. Giltay EJ, Toorians AW, Sarabdjitsingh AR, de Vries NA, Gooren LJ . Established risk factors for coronary heart disease are unrelated to androgen-induced baldness in female-to-male transsexuals. See comment in PubMed Commons below J Endocrinol. 2004; 180: 107-112.
10. Costa EM, Mendonca BB2 . Clinical management of transsexual subjects. See comment in PubMed Commons below Arq Bras Endocrinol Metabol. 2014; 58: 188-196.
11. Elbers JM, Giltay EJ, Teerlink T, Scheffer PG, Asscheman H, Seidell JC, Gooren LJ . Effects of sex steroids on components of the insulin resistance syndrome in transsexual subjects. See comment in PubMed Commons below Clin Endocrinol (Oxf). 2003; 58: 562-571.
12. Wierman ME, Basson R, Davis SR, Khosla S, Miller KK, Rosner W, Santoro N . Androgen therapy in women: an Endocrine Society Clinical Practice guideline. See comment in PubMed Commons below J Clin Endocrinol Metab. 2006; 91: 3697-3710.
13. Xu L, Freeman G, Cowling BJ, Schooling CM. Testosterone therapy and cardiovascular events among men: a systematic review and meta-analysis of placebo-controlled randomized trials. BMC Med. 2013 Apr 18; 11:108.
14. Corona G, Maseroli E, Rastrelli G, Isidori AM, Sforza A, Mannucci E, Maggi M . Cardiovascular risk associated with testosterone-boosting medications: a systematic review and meta-analysis. See comment in PubMed Commons below Expert Opin Drug Saf. 2014; 13: 1327-1351.
15. Davis SR . Cardiovascular and cancer safety of testosterone in women.

- See comment in PubMed Commons below *Curr Opin Endocrinol Diabetes Obes.* 2011; 18: 198-203.
16. Xing D, Nozell S, Chen YF, Hage F, Oparil S. Estrogen and mechanisms of vascular protection. See comment in PubMed Commons below *Arterioscler Thromb Vasc Biol.* 2009; 29: 289-295.
17. van Staa TP, Sprafka JM. Study of adverse outcomes in women using testosterone therapy. See comment in PubMed Commons below *Maturitas.* 2009; 62: 76-80.
18. Mueller A, Kiesewetter F, Binder H, Beckmann MW, Dittrich R. Long-term administration of testosterone undecanoate every 3 months for testosterone supplementation in female-to-male transsexuals. See comment in PubMed Commons below *J Clin Endocrinol Metab.* 2007; 92: 3470-3475.
19. Matilainen V, Koskela P, Keinänen-Kiukaanniemi S. Early androgenetic alopecia as a marker of insulin resistance. See comment in PubMed Commons below *Lancet.* 2000; 356: 1165-1166.
20. Colizzi M, Costa R, Todarello O. Transsexual patients' psychiatric comorbidity and positive effect of cross-sex hormonal treatment on mental health: results from a longitudinal study. *Psychoneuroendocrinology* 2014 Jan; 39:65-73.
21. American Psychiatric Association. *Diagnostic and Statistical Manual of Mental Disorders, Fifth Edition (DSM-5)*, American Psychiatric Association, Arlington, VA 2013.
22. Mancia G, De Backer G, Dominiczak A, Cifkova R, Fagard R, Germano G et al. 2007 Guidelines for the Management of Arterial Hypertension: The Task Force for the Management of Arterial Hypertension of the European Society of Hypertension (ESH) and of the European Society of Cardiology (ESC). *J Hypertens* 2007; 25:1105-1187.

**Cite this article**

Martinez-Martin FJ, Arnas-Leon C, Acosta-Calero C, Perdomo-Herrera E (2014) Labile Hypertension Associated with Testosterone Treatment in a Young Female-To-Male Transsexual. *Ann Clin Exp Hypertension* 2(2): 1013.