

Short Communication

# Application of 3D-Stereotactic Surface Projection Analysis for CT-Perfusion of the Brain

Noriaki Tomura M.D\*

Department of Neuroradiology, Southern Tohoku Research Institute for Neuroscience, Southern Tohoku General Hospital, 7-115 Yatsuyamada, Koriyama, Fukushima, 963-8563, Japan

Corresponding author

Noriaki Tomura, Department of Neuroradiology, Southern Tohoku Research Institute for Neuroscience, Southern Tohoku General Hospital, 7-115 Yatsuyamada, Koriyama, Fukushima, 963-8563, Japan, Tel: +81-24-934-5322; Fax: +81-24-922-5320; E-mail: tomura@bloom.ocn.ne.jp

Submitted: 10 July 2013

Accepted: 10 July 2013

Published: 13 July 2013

Copyright

© 2013 Tomura

OPEN ACCESS

Three dimensional stereotactic surface projection (3D-SSP) analysis methods [1-4] have been used to evaluate cerebral perfusion using single photon emission CT (SPECT). It is a fully automated, user-independent method for data extraction, and it allows pixel-by-pixel analysis, anatomic normalization of individual SPECT data to the standard brain, and comparison of regional voxel data between 2 different groups.

CT-perfusion is useful a method and can give us quantitative perfusion data such as cerebral blood flow (CBF), cerebral blood volume (CBV), mean transit time (MTT), and so forth by multi-detector-row CT (MDCT). CT-perfusion has been used to evaluate cerebrovascular condition in patients with cerebrovascular disorders and neoplasms of the brain. CT-perfusion of the whole brain can recently be performed by widely used 64-row MDCT with dynamic pitch helical reconstruction with advanced table control. 4D-CT (time resolved 3D-CT) can be simultaneously acquired scanning of CT-perfusion. 4D-CT scan depict collateral circulation in stenocclusive diseases, and feeding arteries and draining veins in arteriovenous malformation and neoplasms of the brain [5]. 4D-CT could be partly alternative to intra-arterial digital subtraction angiography. CT-perfusion enables us to evaluate cerebral circulation by widely used MDCT, and it does not need radioisotope pharmaceuticals and equipments. However, to our knowledge, analysis method of CT-perfusion has been usually used as a conventional method using region of interests (ROIs) selected by operators. Its conventional method has many problems such as inadequate reproducibility and poor objectivity.

3D-SSP method was applied for CT-perfusion. The mean value of CBF, CBV, MTT, and so forth is automatically displayed in the cerebral hemisphere, the territory of the anterior cerebral artery (ACA), middle cerebral artery (MCA), posterior cerebral artery (PCA), basal ganglionic region (BG), thalamus, pons, cerebellar hemisphere, and cerebellar vermis (Figures 1 and 2). This method can be applied to evaluate perfusion reserve by performing CT-perfusion before and after the administration of acetazolamide [6]. We can also perform 3D-SSP analysis to compare the mapping of CBF of the patient from that of the normal subjects. The pixel values of the patient image set are normalized to the mean global (GLB), thalamus (THL), cerebellum (CBL), or pons (PNS) CBF

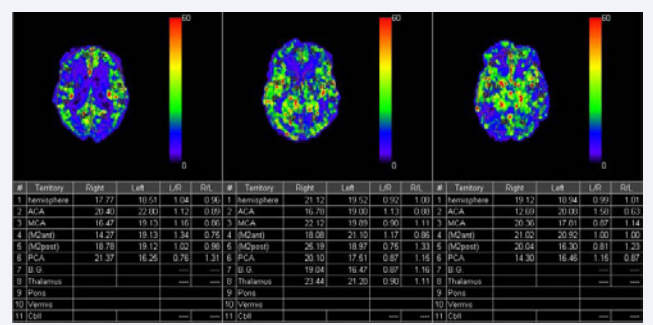


Figure 1 The value of cerebral blood flow (CBF) in each territory on three slices is automatically displayed using 3D-SSP application.

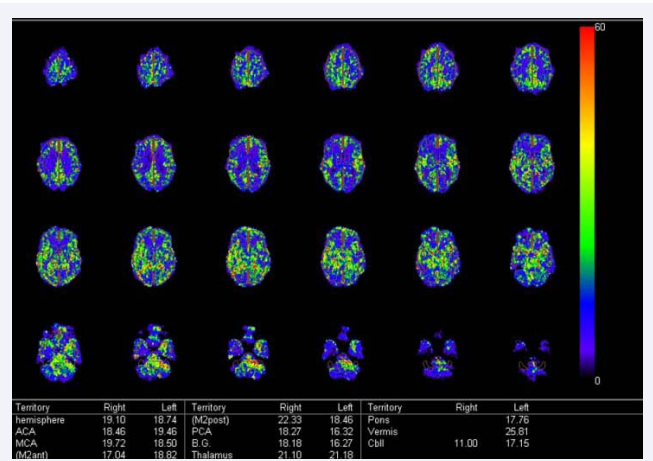
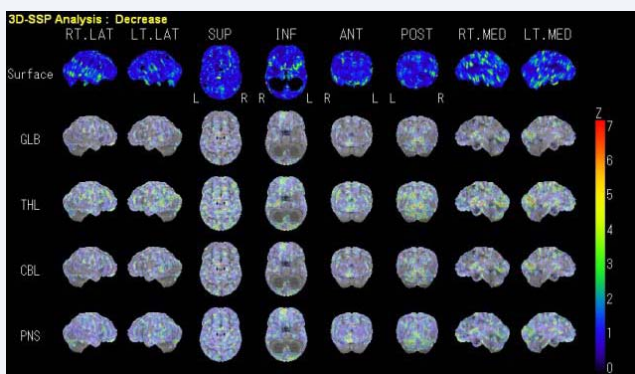


Figure 2 The value of CBF in each territory on all slices is automatically displayed using 3D-SSP application.

before the analysis. To quantify perfusion deficits, pixel-by-pixel z scores are used. Z scores ( [mean value of normal subjects] – [individual value] / SD of normal subjects) are calculated for each surface pixel. A positive z score represents a reduced CBF in the patient relative to normal subjects (Figure 3). Number of normal subjects used in figure 3 is only 4, however, its data could be more confident in more normal subjects.



**Figure 3** Z-score displayed on 3D-normalized brain. The first row is CBF mapping. Z-score mapping normalized by the mean global (GLB), thalamus (THL), cerebellum (CBL), and pons (PNS).

## ACKNOWLEDGEMENT

I thank Mr. Takasi Arai and Mr. Toshikazu Akiyama (Radiological technician in Southern Tohoku General Hospital) and Mr. Yuji Yoshida (GE Healthcare) for technical assistance.

## REFERENCES

1. Mizumura S, Kumita S, Cho K, Ishihara M, Nakajo H, Toba M, et al.

Development of quantitative analysis method for stereotactic brain image: assessment of reduced accumulation in extent and severity using anatomical segmentation. *Ann Nucl Med* 2003; 17: 289-295.

2. Hanyu H, Shimizu S, Tanaka Y, Takasaki M, Koizumi K, Abe K. Differences in regional cerebral blood flow patterns in male versus female patients with Alzheimer disease. *AJNR Am J Neuroradiol* 2004; 25: 1199-1204.
3. Takahashi K, Yamaguchi S, Kobayashi S, Yamamoto Y. Effects of aging on regional cerebral blood flow assessed by using technetium Tc 99m hexamethylpropyleneamine oxime single-photon emission tomography with 3D stereotactic surface projection analysis. *AJNR Am J Neuroradiol* 2005; 26: 2005-2009.
4. Nakashima T, Nakayama N, Miwa K, Okumura A, Soeda A, Iwama T. Focal brain glucose hypometabolism in patients with neuropsychologic deficits after diffuse axonal injury. *AJNR Am J Neuroradiol* 2007; 28: 236-242.
5. Tomura N, et al. 4D-CT in brain tumors: feasibility in hemodynamic depiction. *Internet Radiology* 2011; 13: 1.
6. Tomura N, Otani T, Koga M, Ishiyama K. Correlation between severity of carotid stenosis and vascular reserve measured by acetazolamide brain perfusion single photon emission computed tomography. *J Stroke Cerebrovasc Dis* 2013; 22: 166-170.

## Cite this article

Tomura N (2013) Application of 3D-Stereotactic Surface Projection Analysis for CT-Perfusion of the Brain. *J Neurol Disord Stroke* 1(1): 1001.