

Review Article

Types of Rickets

Al-Mutair Angham* and Alsubhi Rajaa

Department of Pediatrics, Endocrinology Division, King Abdullah Specialist Children Hospital, Kingdom of Saudi Arabia

*Corresponding author

Angham Al Mutair, Department of Pediatrics, Endocrinology Division, King Abdullah Specialist Children Hospital (KASCH), Box 22490, Riyadh 11426, Kingdom of Saudi Arabia, Tel: 9668011111; Email: almutair.angham@gmail.com / mutaira@ngha.med.sa

Submitted: 08 August 2017

Accepted: 09 October 2017

Published: 10 October 2017

Copyright

© 2017 Angham et al.

OPEN ACCESS

Keywords

- Rickets
- Vitamin D
- Calcium
- Phosphate
- Mineralization
- Types

Abstract

Rickets is a disorder that results from decreased mineralization of the growth plate in the growing infant, child and adolescent. Rickets can occur as heritable disorders with multiple genes mutations in different etiologies of types of rickets. There are different ways of classifying types of rickets, the most commonly used is to be classified as calciopenic and phosphopenic rickets. Calciopenic rickets is due to nutritional deficiency of vitamin D and or calcium and rarely due to vitamin D defect in its cellular action or its metabolism to active metabolite-calcitriol or due to excess loss of calcium in urine. Phosphopenic rickets is mainly due to renal phosphate wasting either due to primary renal tubular defect or excess generation of phosphatonin, compounds that inhibit phosphate reabsorption from renal tubules but unusually related to dietary phosphate deficiency that is wide available. Abnormalities in the alkaline phosphate synthesis impaired bone mineralization can be a rare cause of rickets. Serum 25-hydroxyvitamin D concentrations are low in vitamin D deficiency rickets and hereditary form of rickets due to inactivating mutations in CYP2R1 gene while may be normal in other hereditary forms of rickets in these latter disorders, the serum 1,25-dihydroxy vitamin D concentrations are often low or inappropriately in the normal range and can be high in vitamin D-resistant rickets. Treatment of each type of rickets depends on the underlying etiologies.

ABBREVIATIONS

LBW: Low Birth Weight; 25OHD: 25-Hydroxyvitamin D; VDDR: Vitamin D Dependent Rickets; XLHR: X-Linked dominant Hypophosphatemic Rickets; PHEX: Phosphate-regulating Endopeptidase homologue, X-linked; TNSALP: Tissue Nonspecific Alkaline Phosphatase

INTRODUCTION

Rickets is a disorder that results from decreased mineralization of the growth plate in the growing infant, child, and adolescent due to deficiency of vitamin D or defect in its metabolism or functions, deficiency of calcium or phosphate, or decreased activity of alkaline phosphatase [1]. There are different ways of classification of types of rickets, the most commonly used is to be classified as calciopenic (due to deprivation of vitamin D or calcium) or phosphopenic (usually due to renal phosphate wasting) which this classification include the most common etiologies of rickets [1,2]. Rickets can occur as heritable disorders with multiple genes mutations in different etiologies of types of rickets (Table 1).

Rickets can be presented even in newborn period with fractures and hypocalcemia if their mother had severe vitamin D-deficiency. Also it is manifested by skeletal deformities such as delayed closure of the fontanelles, craniotabes (reversible compression of the skull's outer table), frontal bossing (expansion of cranial bones), and occasional craniosynostosis in infants. Genu varum or valgum is common feature in the weight-bearing child while in the preambulatory infant can occur as bowing

of the forearms. Also may have delayed tooth eruption with poor enamel formation; pectus carinatum, prominence of the costochondral junctions, flaring of the lower rib cage; kyphosis, scoliosis and flaring of the metaphyses of the long bones (Figure 1) [1].

Rickets is characterized radiographically initially by epiphyseal widening then cupping, splaying, and fraying of the metaphyses of long bones especially in distal ulna, distal femur, and proximal tibia; long bones deformity, stress fracture lines and diffuse demineralization, and fractures (Figure 2) [1,2].

Typical patterns of laboratory values observed in patients with rickets due to different causes are shown in (Table 2) [1].

TYPES OF RICKETS

There are different ways of classifying types of rickets, the most commonly used is to be classified as calciopenic and phosphopenic rickets [1]. Calciopenic rickets is due to nutritional deficiency of vitamin D and or calcium and rarely due to vitamin D defect in its cellular action or its metabolism to active metabolite-calcitriol or due to excess loss of calcium in urine. Phosphopenic rickets is mainly due to renal phosphate wasting either due to primary renal tubular defect or excess generation of phosphatonin, compounds that inhibit phosphate reabsorption from renal tubules but unusually related to dietary phosphate deficiency that is wide available. An abnormalities in the alkaline phosphate synthesis impaired bone mineralization can be a rare cause rickets [1,2].

Table 1: Common Genetic Causes of Rickets.

Gene/Chromosome/MIM	Disease
A) Disorder of Vitamin D metabolism	
□ CYP2Q1/11P15.2/608713	Vitamin D Hydroxylation – deficient Rickets Type 1B (also termed Vitamin D dependent Rickets Type 1B) AR
□ CYP27B1/12q14.1/609506	25α-HydroxyVitamin D-1α -Hydroxylase defieincey (Vitamin D dependent rickets Type 1A) AR
□ VDR: Vitamin D receptor/12q13.11/601769	Resistance to calcitriol and Vitamin D–dependent rickets Type 2A, AR
B) Disorder of Phosphate metabolism leading to Rickets	
□ SLC34A1 (Sodium phosphate cotransporter family 34 member 1/5q35.3/182309	Hypophosphatemic rickets with nephrolithiasis, Type 1, AD, fanconi syndrome Type 2, AR
□ SLC34A3 Family 34, member 3/9q34/609826	Hypophosphatemic rickets with hypercalciuria,AR
□ SLC9A3R1/Family member 3/17Q25.1/604990	Hypophosphatemic rickets with nephrolithiasis Type2, AD
□ CLCN5: Chloride channel 5/XP11.23-p11.22/300008	X-linked recessive hypophosphatemic rickets, hypercalciuria, nephrocalcinosis, XLR
□ PHEX/XP22.1/300550	X-linked hypophosphatemicrickets, X-linked AD with increase expression of FGF23
□ DMP1/4Q22.1/600980	AR hypophosphatemic rickets with increase synthesis of FGF23
□ ENPP1/6q23.2/173335	AR hypophosphatemic rickets with increase expression of FGF23
□ FGF23/12P13.3/60538	(Gain of function) AD hypophosphatemic rickets associated with decrease degradation of FGF23

Table 2: Laboratory Date in Rickets of Different Etiologies.

Type	Calcium	Phosphate	Alkaline Phosphatase	Calcidol	Calcitriol	PTH
Calcium deficiency	↑↓	↓	↑↑	N	↑	↑
Phosphate deficiency	N, ↑	↓↓	↑↑	N	↑	N, ↓
Vitamin D deficiency						
Mild	N, ↓	N ↓	↑	↓	N	N
Moderate	N, ↓	↓	↑↑	↓	N, ↓↑	↑
Severe	↓	↓	↑↑	↓↓↓	↓	↑↑
Loss-of function <i>CYP2R1</i> (25-hydroylase)	↓	↓	↑	↓	↓	↑
Loss-of-function <i>CYP27B1</i> (25OHD-1x-hydroxylase)	↑↑	↓↓	↑↑↑	N	↓↓↓	↑↑↑
Loss-of-function <i>VDR</i> (resistance to calcitriol)	↓↓	↓↓	↑↑↑	N	↑↑↑	↑↑↑
Loss-of-function <i>PHEX</i> (X-linked hypophosphatemic rickets)	N	↓↓	↑	N	N, ↓	N
Hypophosphatasia	N, ↑	N, ↑	↓	N	N	N, ↓

N - normal, ↓- low, ↑- high

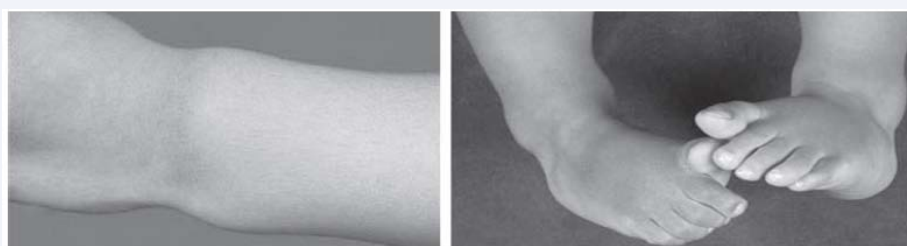

Figure 1 Clinical manifestations of vitamin D-deficient rickets. Note flaring of the distal metaphyses of the long bones.

This classification includes the most common etiologies of rickets:

Calciopenic rickets / Vitamin D related rickets

Calciopenic rickets are due to vitamin D deficiency or defect in its cellular action or its metabolism or due to calcium deficiency as the following:

Vitamin D deficiency or insufficiency: Vitamin D deficiency

is considered as a common disorder of infants, children and adolescents. Deficiency of vitamin D is commonly seen in those whom are at high risk group who are not prophylactically on Vitamin D supplement like infants who are exclusively on breast-feeding [3], infant who are rapidly growing, darkly skinned children who had limited exposure to sunlight [4], vegetarian children and children who are on anticonvulsant medications. Also adolescents with limited intake of milk and multivitamins,

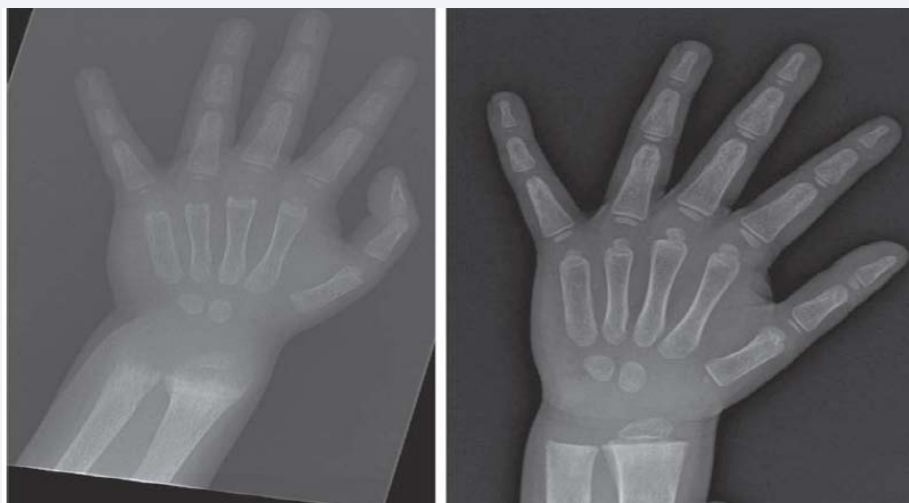


Figure 2 Radiographic manifestations of vitamin D-deficient rickets. Note flaring of the distal metaphyses of the long bones and radiographic response to treatment with vitamin D. Adapted from Sperling M. Pediatric endocrinology.

who is consuming high phosphate containing soft drinks. Patients with intestinal malabsorptive disorders such as celiac or inflammatory bowel diseases, biliary obstruction, or pancreatic exocrine insufficiency (e.g., cystic fibrosis) and post intestinal resection are at high risk of developing calciopenic Rickets.

Biochemically in patients with vitamin D deficiency expect to find low or normal serum concentrations of total calcium that will lead to secondary hyperparathyroidism resulting in low phosphate level and high alkaline phosphatase activity. Low serum concentrations of 25 hydroxyvitamin-D (calcidiol) would confirmed the diagnosis (Table 2).

However the underline etiology that leads to vitamin D deficiency need to be identified and treated. Prevention of vitamin D deficiency is the gold standard in the management. The breast-feeding infants should receive 400 IU of vitamin D daily in those children are not receiving adequate amounts of vitamin D in their prepared formulas or in their diet and those not exposed to sunlight should also receive 400 IU/day of vitamin D [5].

For treatment of nutritional rickets, the minimal recommended dose of vitamin D is 2000 IU/day for a minimum of 12 weeks [6]. Initially need to add elemental calcium (30 to 75mg/kg/day) to vitamin D in order to avoid the hypocalcemia that accompanies rapid bone remineralization and the vitamin D dose should lowered to 400 to 600 IU/day when there is radiographic evidence of healing [5].

Vitamin D metabolism and functions defect: Disorder of vitamin D metabolism and Functions are rare causes of Rickets. Inactivating homozygous or compound heterozygous mutations in CYP2R1 gene, gene encoding 25 hydroxylase, this mutation prevents synthesis of 25-hydroxyvitamin D (25OHD), leading to rickets, hypocalcemia, hypophosphatemia, increased in alkaline phosphatase activity, and low serum levels of 2OHD [7]. This type of rickets has been called Vitamin D Dependent Rickets type 1B (VDDR) (MIM#608713) and these patients partially respond to treatment with calcidiol. VDDR1B usually mimic vitamin D deficiency rickets but they are highly dependent in

vitamin D supplementation and they relapse once vitamin D supplementation is stopped in non-malabsorption disorder.

Until today, five mutations were found to affect CYP2R1 gene. Two mutations were found from Nigeria (c.296T > C [L99P] and c.726A > C [K242N]), another 2 were from Saudi Arabia (c.367+1, G>A and c.768, ins T), and the recent one from France (c.124_138delins CGG) [8-11].

Inactivating mutation in CYP27B1 gene (MIM#609506), gene encoding renal tubular 25OHD-1alpha hydroxylase activity, prevents synthesis of calcitriol (1,25OHD), leading to Vitamin D Dependent Rickets type 1A [12]. VDDR1A is an autosomal recessive disease which can be presented in infancy with delayed motor milestones (walking), bone deformities (bowing of the forearms), growth retardation, muscle weakness, or hypocalcemic seizures and biochemically with hypocalcemia, hypophosphatemia, high alkaline phosphatase, and markedly elevated serum level of PTH, and normal concentrations of 25OHD but very low level of calcitriol that do not increased after administration of vitamin D or calcidiol. The diagnosis of this disorder is confirmed by identification of the mutation in CYP27B1.

Treatment with physiologic doses of calcitriol (10 to 20ng/kg/day) will resolve the clinical, biochemical, and radiographic manifestations of VDDR1A completely [12].

Inactivating homozygous or compound heterozygous mutations of VDR (MIM#601769), the gene encoding the vitamin D receptor called Vitamin D-Resistant Rickets or VDDR type 2A is an autosomal recessive disorder. Infants with this disease have clinical and biochemical findings similar to those who lack 25OHD-1alpha hydroxylase activity additionally have alopecia because vitamin D is essential of growth of epithelial nuclei and those of the outer root sheath cells of the hair follicle. In this type of rickets serum level of calcitriol are markedly elevated which could be used as a clue for diagnosis on rachitic patient after excluding vitamin D intoxication confirmed by identification of the loss function mutation in VDR [12,13]. High doses of

calcitriol (1 to 6mg/kg/day) and supplemental calcium (1 to 3g of elemental calcium daily) has been effective in increasing serum calcium concentrations and healing rickets in mild form but moderate to severe forms need continuous high doses of intravenous calcium infusion that could improve some clinical and biochemical manifestations [14].

Vitamin D-Dependent Rickets, type 2B (VDDR2B), is a second form of resistance to vitamin D which is due to inhibition of binding of the ligand VDR-retinoic X receptor heterodimer to the VDRE in the upstream promoter of vitamin D responsive target genes.

It had a phenotype similar to that of VDDR2A without alopecia and with an intact vitamin D nuclear receptor [12,13].

Calcium Deficiency Rickets: In developing countries where calcium intake is characteristically very low, with minimal or no dairy products, nutritional calcium deficiency is the main cause of rickets among children outside the infant age group [6,10]. Also calcium deficiency rickets can occur due to diminished intestinal absorption of dietary calcium because its bound by fiber or phytate in cereals in infants and children with normal intake of phosphate and serum levels of 25OHD [14]. A child with calcium deficiency rickets is effectively treated by intake of 1000mg of elemental calcium daily for 6 months with provision of normal amounts of vitamin D.

In Nigerian children with rickets have a low intake of calcium and have a better response to treatment with calcium alone or in combination with vitamin D rather than to treatment with vitamin D alone [15].

Phosphopenic rickets

Hypophosphatemia in infants, children and adolescents may be due to hereditary or acquired disorders. Phosphate deficiency occurs in patients with depressed renal tubular reabsorption of phosphate due to different genetic etiologies (Tables 1), in subjects with decreased intestinal phosphate absorption, in those receiving parenteral nutrition with inadequate amounts of phosphorous, in patients ingesting large amounts of phosphate-binding antacids as aluminum containing antacid, and in premature infants receiving only human breast milk [16].

X-linked dominant Hypophosphatemic Rickets (XLHR) is the most frequent form of rickets encountered (1:20,000births) in developed countries [14]. XLHR is due to inactivation mutations in PHEX (PHosphate-regulating Endopeptidase homologue, X-linked) (MIM#300550) encoding a zinc metallopeptidase expressed by bone cells. Physical findings in children with XLHR include short stature with progressive lower extremity deformities which should comanaged with an experienced pediatric orthopedist who may prescribe braces and may benefit from hemiepiphyseodeses [17,18]. The diagnosis of XLHR is established when the typical family history (if the patient does not carry a *de novo* mutation), clinical findings (mainly deformities of the lower extremities and flaring of the metaphyses), roentgenographic (rachitic changes) and laboratory data (hypophosphatemia, hyperphosphaturia, inappropriately low serum level of calcitriol, normal serum concentration of PTH, calcium, creatinine, and 25OHD) are present and when

other causes of hypophosphatemia and hyperphosphaturia have been excluded (Tables 2). The diagnosis of XLHR may be further confirmed by identification of the PHEX mutation in most of patients. Treatment with calcitriol and phosphate before 6 months of age may result in better adult stature than when treatment starts after 1 year of age [19].

Autosomal dominant hypophosphatemic rickets is due to activating mutations in proprotein convertase cleavage site of the FGF23 gene (MIM#605380); these mutations increased serum concentrations of FGF-23 which result in hypophosphatemia and phenotypic presentation similar to XLHR [20]. Patient with this disorder are treated with the cautious administration of calcitriol and phosphate.

Autosomal recessive hypophosphatemic rickets is due to diallelic inactivating mutations in the gene encoding dentin matrix phosphoprotein 1 (DMP1) (MIM#600980); a protein that normally inhibits synthesis of FGF23 which also result in elevated serum concentrations of FGF23 [21,22].

Increased secretion of FGF23 with hypophosphatemic rickets can also occur in children the McCune Albright syndrome due to activating mutation in GNAS and in some mesenchymal tumors [21].

X-linked recessive hypophosphatemic rickets (XLH) is due to inactivating mutations in CLCN5 (MIM#300008), gene encoding a proximal tubular chloride channel 5 [23].

Fanconi syndrome and many disorders with renal tubular acidosis like cystinosis, tyrosinemia, galactosemia, oculo-cerebral-renal syndrome, fructose intolerance, Wilson disease; acquired: renal transplantation, nephrotic syndrome and renal vein thrombosis, can also lead to phosphaturia and resultant rickets [24,25].

In 2016, KRN23, an investigational recombinant fully human monoclonal IgG1 antibody against FGF23, has received therapy designation from FDA for the treatment of XLH in pediatric patients one year of age and older [26,27]. This Breakthrough Therapy Designation is based on interim 40-week data from the first 36 patients enrolled in the ongoing pediatric Phase 2 study of KRN23 for the treatment of XLH and a Phase 3 program of KRN23 in adult patients with XLH is ongoing.

KRN23 is designed to bind to FGF23 and inhibit the excessive biological activity of FGF23, thereby directly act on the phosphate wasting leading to phosphate reabsorption from the kidney and increase the production of vitamin D, which enhances intestinal absorption of phosphate and calcium. In addition to XLH, KRN23 is being developed for tumor-induced osteomalacia, a disease characterized by typically benign tumors that produce excess levels of FGF23, which can lead to severe osteomalacia, fractures, bone and muscle pain, and muscle weakness. KRN23 is a promising treatment for XLH patients. Complete absorption, sustained effect on serum Phosphate beyond 4 weeks, and a direct linear relationship between pharmacokinetics, pharmacodynamics effects supports a subcutaneous treatment regimen of once every 4 weeks for KRN23 in adults with XLH [26,27]. KRN23 was generally safe and well tolerated [28].

Hypophosphatasia

Hypophosphatasia is a rare disorder of bone mineralization due to inactivating mutations of ALPL (MIM#171760), the gene encoding tissue nonspecific alkaline phosphatase (TNSALP). When function of this phosphomonoesterase is impaired, its endogenous substrates-pyrophosphate, pyridoxal 5'-phosphate and phosphoethanolamine increased, coat the surface of hydroxyapatite crystals, and restrict crystal growth [29]. Inability to increase local levels of phosphate to level sufficient to permit formation of hydroxyapatite further decreases bone mineralization.

The autosomal recessive disorders of hypophosphatasia are perinatal and infantile forms due to inactivating mutations in ALPL, whereas the childhood, adult, and odontohypophosphatasia forms may be transmitted as either autosomal recessive or dominant traits.

Seizures can occur in patients with loss-of-function mutations in ALPL because of deficiency of pyridoxine formed by dephosphorylation of pyridoxal 5'-phosphate; pyridoxine is a cofactor in the synthesis of the neurotransmitter γ -aminobutyric acid.

The diagnosis of hypophosphatasia is confirmed by the clinical and radiographic findings of rickets in additions to low bone alkaline phosphatase activity and elevated serum levels of pyrophosphate and pyridoxal-5'-phosphate, increased urine excretion of pyrophosphate and phosphoethanolamine, and identification of the mutation in ALPL.

Treatment of patients with the perinatal, infantile and juvenile-onset forms of hypophosphatasia had proven extraordinarily effective with a biosynthetic human recombinant ectodomain of tissue nonspecific alkaline phosphatase named as Strensiq (asfotasealfa) which is approved by both the U.S. Food and Drug Administration and European Medicines Agency [30].

Rickets in prematurity/low birth weight

Since approximately 80% of total bone calcium is accrued in the last trimester of pregnancy and because low birth weight (LBW) (<1500g) and very LBW (<1000g) infants are unable to maintain the in utero rate of synthesis of bone matrix and mineralization from the nutrients absorbed from gastrointestinal tract or administered by parenteral nutrition, they are at great risk for development of low bone mass (osteopenia of prematurity) and/or rickets [31-33]. An immobilized premature or LBW offspring of a multiparous mother, who develop bronchopulmonary dysplasia and who receiving glucocorticoid, theophylline, or furosemide is at particular risk for development of low bone mass [34,35]. The LBW neonate is best managed preventively by the daily feeding of as much of required amounts of calcium (140-160mg/100kcal of formula/day), phosphate (95-110mg/100 kcal), vitamin D (400 U/day), protein, carbohydrates, and lipid as possible. Either breast milk fortified with calcium and phosphate or prepared formulas designed for feeding of LBW neonate may be used. If parenteral administration of nutrients is necessary, the maximum safe amounts of calcium and phosphate should be infused. Frequent determinations of serum level of calcium, phosphate, and creatinine are necessary to prevent hypocalcemia,

hypercalcemia, hypercalciuria, and nephrocalcinosis. Although bone mass may remain low in prematurity born infant through infancy and childhood, it eventually normalizes [36].

CONCLUSION

Rickets is a preventable disorder that results from decreased mineralization of the growth plate in the growing infant, child and adolescent. There are different ways of classifying types of rickets, the most commonly used is to be classified as calciopenic and phosphopenic rickets. Treatment of each types of rickets depend on the underlying etiologies, these include improve sunlight exposure, diet, vitamin D and mineral supplements.

REFERENCES

1. Sperling M. Pediatric endocrinology. 4th edn. Philadelphia: Saunders/Elsevier. 2014.
2. Colin D. Rudolph, Abraham M. Rudolph, George E. Lister, Lewis R. First, Anne A. Gershon. Rudolph's Pediatrics. 22nd edn. New York: McGraw-Hill. 2011.
3. Al-Atawi MS, Al-Alwan IA, Al-Mutair AN, Tamim HM, Al-Jurayyan NA. Epidemiology of nutritional rickets in children. Saudi J Kidney Dis Transpl. 2009; 20: 260-265.
4. Misra M. Vitamin D insufficiency and deficiency in children and adolescents. UpToDate. 2012.
5. Misra M, Pacaud D, Petryk A, Collett-Solberg PF, Kappy M, Drug and Therapeutics Committee of the Lawson Wilkins Pediatric Endocrine Society. Vitamin D deficiency in children and its management: review of current knowledge and recommendations. Pediatrics. 2008; 122: 398-417.
6. Munns CF, Shaw N, Kiely M, Specker BL, Thacher TD, Ozono K, et al. Global Consensus Recommendations on Prevention and Management of Nutritional Rickets. J Clin Endocrinol Metab. 2016; 101: 394-415.
7. Cheng JB, Levine MA, Bell NH, Mangelsdorf DJ, Russell DW. Genetic evidence that human CYP1B1 enzyme is a key vitamin D 25-hydroxylase. Proc Natl Acad Sci U S A. 2004; 101: 7711-7715.
8. Casella SJ, Reiner BJ, Chen TC, Holick MF, Harrison HE. A possible genetic defect in 25-hydroxylation as a cause of rickets. J Pediatr. 1994; 124: 929-932.
9. Thacher TD, Fischer PR, Singh RJ, Roizen J, Levine MA. CYP2R1 Mutations Impair Generation of 25-hydroxyvitamin D and Cause an Atypical Form of Vitamin D Deficiency. J Clin Endocrinol Metab. 2015; 100: 1005-1013.
10. Al Mutair AN, Nasrat GH, Russell DW. Mutation of the CYP2R1 Vitamin D 25-Hydroxylase in a Saudi Arabian Family with Severe Vitamin D Deficiency. J Clin Endocrinol Metab. 2012; 97: 2022-2025.
11. Molin A, Wiedemann A, Demers N, Kaufmann M, Do Cao J, Mainard L, et al. Vitamin D-Dependent Rickets Type 1B (25-Hydroxylase Deficiency): A Rare Condition or a Misdiagnosed Condition? J Bone Miner Res. 2017; 32: 1893-1899.
12. Demay MB. Rickets caused by impaired vitamin D activation and hormone resistance: pseudovitamin D deficiency rickets and hereditary vitamin D-resistant rickets. In: Favus MJ, editors. Primer on the Metabolic Bone Diseases and Disorders of Mineral Metabolism, 6th ed. Washington: American Society for Bone and Mineral Research, 2006: 338-341.
13. Nicolaidou P, Tsitsika A, Papadimitriou A, Karantana A, Papadopoulou A, Psychou F, et al. Hereditary vitamin D-resistant rickets in Greek children: Genotype, phenotype, and long-term response to treatment. J Pediatr Endocrinol Metab. 2007; 20: 425-430.

14. DeLucia MC, Mitnick ME, Carpenter TO. Nutritional rickets with normal circulating 25-hydroxyvitamin D: a call for reexamining the role of dietary calcium intake in North American infants. *J Clin Endocrinol Metab.* 2003; 88: 3539-3545.
15. Thacher TD, Fischer PR, Pettifor JM, Lawson JO, Isichei CO, Reading JC, et al. A comparison of calcium, vitamin D, or both for nutritional rickets in Nigerian children. *N Engl J Med.* 1999; 341: 563-568.
16. Agus ZS. Causes of hypophosphatemia. UpToDate. 2012.
17. Alon US. Hypophosphatemic vitamin D-resistant rickets. In: M. J. Favus (Ed.), *Primer on the metabolic bone diseases and disorders of mineral metabolism*, (6th edn) (pp. 342-345). Washington, DC: American Society for Bone and Mineral Research. 2006.
18. Novais E, Stevens PM. Hypophosphatemic rickets: the role of hemiepiphyseal diaphyseal. *J Pediatr Orthop.* 2006; 26: 238-244.
19. Mäkitie O, Doria A, Kooh SW, Cole WG, Daneman A, Sochett E. Early treatment improves growth and biochemical and radiographic outcome in X-linked hypophosphatemic rickets. *J Clin Endocrinol Metab.* 2003; 88: 3591-3597.
20. Takeda E, Yamamoto H, Nashiki K, Sato T, Arai H, Taketani Y. Inorganic phosphate homeostasis and the role of dietary phosphorus. *J Cell Mol Med.* 2004; 8: 191-200.
21. Shulman DI, Hahn G, Benator R, Washington K, Kenneth E. White, Joshua Farber, et al. Tumor-induced rickets: Usefulness of MR gradient echo recall imaging for tumor localization. *J Pediatr.* 2004; 144: 381-385.
22. Feng JQ, Ward LM, Liu S, Lu Y, Xie Y, Yuan B, et al. Loss of DMP1 causes rickets and osteomalacia and identifies a role for osteocytes in mineral metabolism. *Nat Genet.* 2006; 38: 1310-1315.
23. Lorenz-Depiereux B, Bastepe M, Benet-Pagès A, Amyere M, Wagenstaller J, Müller-Barth U, et al. DMP1 mutations in autosomal recessive hypophosphatemia implicate a bone matrix protein in the regulation of phosphate homeostasis. *Nat Genet.* 2006; 38: 1248-1250.
24. Ward LM. Renal phosphate-wasting disorders in childhood. *Pediatr Endocrinol Rev.* 2005; 2: 342-350.
25. Tebben PJ, Thomas LF, Kumar R. Fanconi syndrome and renal tubular acidosis. In: Favus MJ, editor. *Primer on the Metabolic Bone Diseases and Disorders of Mineral Metabolism*, 6th edn. Washington, DC: American Society for Bone and Mineral Research. 2006; 354-358.
26. Carpenter TO, Imel EA, Ruppe MD, Weber TJ, Klausner MA, Wooddell MM, et al. Randomized trial of the anti-FGF23 antibody KRN23 in X-linked hypophosphatemia. *J Clin Invest.* 2014; 124: 1587-1597.
27. Zhang X, Carpenter T, Imel E, Ruppe M, Weber T, Klausner M, et al. Pharmacokinetics and pharmacodynamics of a human monoclonal anti-FGF23 antibody (KRN23) after single-dose administration to patients with X-linked hypophosphatemia. *J Bone Miner Res.* 2013; 28: SU0169.
28. <http://www.bone-abstracts.org/ba/0003/ba0003pp91.htm>
29. Wolfgang Högler, Anthony Portale, Erik Imel, Annemieke Boot, Agnès Linglart, Raja Padidela, et al. A randomized, open-label Phase 2 study of KRN23, an investigational fully human Anti-FGF23 monoclonal antibody, in children with X-linked Hypophosphatemia (XLH). *Bone Abstracts.* 2017; 6.
30. Whyte MP. Hypophosphatasia. In: Favus MJ, editor. *Primer on the Metabolic Bone Diseases and Disorders of Mineral Metabolism*, 6th ed. Washington, DC: American Society for Bone and Mineral Research; 2006: 351-353.
31. Whyte MP, Greenberg CR, Salman NJ, et al. Enzyme-replacement therapy in life-threatening hypophosphatasia. *N Engl J Med.* 2012; 366: 904-913.
32. Rauch F, Schoenau E. Skeletal development in premature infants: a review of bone physiology beyond nutritional aspects. *Arch Dis Child Fetal Neonatal Ed.* 2002; 86: 82-85.
33. Miller ME. The bone disease of preterm birth: a biomechanical perspective. *Pediatr Res.* 2003; 53: 10-15.
34. Cakir M, Mungan I, Karahan C, Can G, Okten A. Necrotizing enterocolitis increases the bone resorption in premature infants. *Early Hum Dev.* 2006; 82: 405-409.
35. Aladangady N, Coen PG, White MP, Rae MD, Beattie TJ. Urinary excretion of calcium and phosphate in preterm infants. *Pediatr Nephrol.* 2004; 19: 1225-1231.
36. Aly H, Moustafa MF, Amer HA, Hassanein S, Keeves C, Patel K. Gestational age, sex, and maternal parity correlate with bone turnover in premature infants. *Pediatr Res.* 2005; 57: 708-711.
37. Weiler HA, Yuen CK, Seshia MM. Growth and bone mineralization of young adults weighing less than 1500 grams at birth. *Early Hum Dev.* 2002; 67: 101-1012.

Cite this article

Angham AM, Rajaa A (2017) Types of Rickets. *Ann Orthop Rheumatol* 5(2): 1085.