

Case Report

Late-Onset Cystic Hygromas Presenting in an Adult: A Case Report

Ho Hon Lian¹ and Primuharsa Putra SHA^{2*}

¹Department of Otorhinolaryngology- Head & Neck Surgery, KPJ Healthcare University College, Malaysia

²Ear, Nose and Throat-Head & Neck Consultant Clinic, KPJ Healthcare University College, Malaysia

*Corresponding author

Primuharsa Putra Sabir Husin Athar, Ear, Nose and Throat-Head & Neck Consultant Clinic, KPJ Seremban Specialist Hospital/ KPJ Healthcare University College, Jalan Toman 1, Kemayan Square, 70200 Seremban, Negeri Sembilan, Malaysia, Tel: 00-606-767-7800; Ext 138; Fax: 00-606-767-5900; Email: putrani@yahoo.co.uk

Submitted: 01 January 2016

Accepted: 05 February 2016

Published: 08 February 2016

ISSN: 2379-948X

Copyright

© 2016 SHA et al.

OPEN ACCESS

Abstract

Cystic hygroma (lymphangioma) is a benign congenital malformation of the lymphatic system that occurs in infant or children younger than two years of age. It is a rare presentation in adults. A 30-year-old man was referred for a painless left supraclavicular swelling. Conclusion: Cystic hygromas are a rare differential diagnosis in adult neck masses and should be considered for the adult patients who have neck masses. Surgical excision is the treatment of choice.

Keywords

- Cystic hygroma
- Lymphangioma
- Lymphatic malformation
- Neck
- Adult

INTRODUCTION

Cystic hygroma is an uncommon benign cyst caused by a congenital malformation of the lymphatic vessels. It is most likely related to failure of blind clusters of lymph sacs to join the lymphatic system during development [1]. Within the literature the term cystic hygroma is used interchangeably with lymphangioma and lymphatic malformation [2]. They account for 6% of all paediatric soft tissue tumours, 90% of cases are diagnosed by the age of 2 years and they predominantly develop in the cervicofacial region (75%) and axilla (20%) [1,2]. Presentation in adulthood is rare and the cause is uncertain, however, has been proposed to be related to several predisposing factors such as trauma, infection, tumor growth or iatrogenic stimuli [2].

CASE PRESENTATION

Clinical Presentation

A 30-year-old man presented with painless left supraclavicular swelling for 2 weeks. Head and neck examination revealed non tender, cystic swelling at the left supraclavicular region (Figure 1). There were no other swellings noted. Other ear, nose and throat examinations were unremarkable.

Investigation

Ultrasound of the neck showed a cystic lesion seen in the left supraclavicular/ lower neck region. It was well defined and appeared to lie superficial to the neck muscles. There was movement of fluid on compression. It measured at least 13.6 x 53.2 mm in diameters. It was lied close to but separated from the vessels. Computed tomography (CT) of the neck showed a

well-defined hypo dense lesion seen in the left supraclavicular region (Figure 2). It measured 4.3 x 2 cm in diameter, was of fluid density and superficial to the left sternocleidomastoid muscle. The thyroid gland was normal. Blood investigations: hemoglobin 15.2 g/dL, white blood cell count $7.0 \times 10^3/\mu\text{L}$, erythrocyte sedimentation rate (ESR) 22mm/hr.

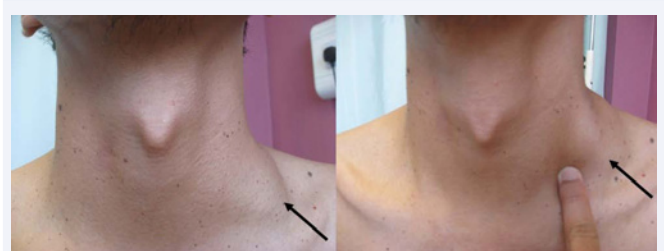

Figure 1 The above photo showed prominent left supraclavicular swelling.

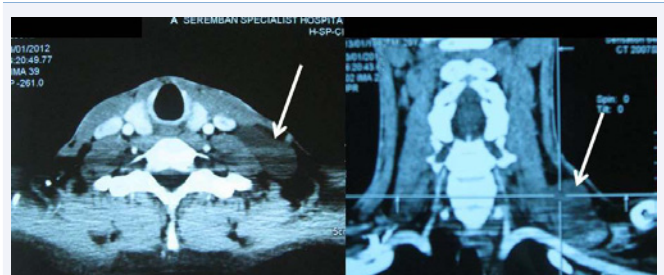

Figure 2 (A) Axial and (B) Coronal computed tomography scan of the neck showed a 6.0 cm x 5.0 cm x 3.0 cm well-defined hypo dense lesion in the left supraclavicular region.

Surgical Management

He underwent an excision under general anesthesia. Intraoperatively, the cystic swelling appeared bluish and separated from the vessels. Post-operative recovery was uneventful. Histopathological examination reported as inflamed cystic hygroma (Figure 3). Specimen of cystic mass measured about 6.0 x 5.0 x 3.0 cm. Histological, sections of the fibrocollagenous cyst wall had diffuse lymphocytic infiltration. The lining was formed by flattened endothelial cells.

DISCUSSION

Typically, a cystic hygroma in an adult grows slowly and in contrast to pediatric hygromas, rarely regresses spontaneously [1]. Although rapid development secondary to trauma, infection, tumor growth or iatrogenic stimuli has been reported, it usually develops in the absence of any precipitating event as shown in this case [2]. The differential diagnosis of the lesion should include hematoma, abscess or lymphocele formation, as well as several types of soft tissue sarcomas [3].

The effect of these lesions depends on their position and relationship to surrounding structures, although the most common adult presentation is of a painless lump in an otherwise asymptomatic patient. However, rapid enlargement over a short period of time has frequently been reported and major structures such as the larynx, trachea, oesophagus, brachial plexus and great vessels have known to be compressed or incorporated within the lesion [4].

Investigation

Ultrasound is particularly helpful in differentiating the cystic or solid nature of the mass [2]. On ultrasound, the lesion appears as multilocular cystic mass, containing septa of variable thickness, while the fluid inside the cyst can appear as completely anechoic, hypo echoic or hyper echoic, depending on the presence of infection, hemorrhage, or high lipid [3].

Other modalities like computed tomography (CT) scan and magnetic resonance imaging (MRI) can be employed to delineate the lesion, in a better way. A CT scan demonstrates multicystic, homogeneous, non-invasive density with low attenuation and enhances uniformly following bolus injection of contrast media. This CT pattern can often be used to differentiate cystic hygroma

from other masses such as soft tissue sarcomas. CT is also helpful in determining the extent of the lesion before surgery [4]. MRI provides accurate preoperative staging, which is essential for defining the individual cystic loci. T1-weighted images determine the extent of the mass and the involvement of contiguous structures provides appropriate information for the surgical procedure, while T2-weighted images may disclose a hyper intense mass corresponding to the dilated lymphatic spaces. These modalities are usually helpful in ascertaining the extent of the lesion and their association with nerves and vessels and are particularly useful, when surgical management of the lesion is contemplated [5].

MANAGEMENT

Complete surgical excision has traditionally been considered the treatment of choice for cystic hygroma [6, 8]. However, several authors have suggested that sclerotherapy may be a more appropriate first-line therapy especially for pediatric patients. Although sclerotherapy is now well established in the treatment of neonatal and pediatric cystic hygromas, there have been relatively few cases reported of its use in adult patients. Some success has been reported in small numbers of adults with sclerotherapy agents such as OK-432 (Picipamil). Caution has been urged with the use of sclerotherapy agents which induce a local immune response that often results in a rapid temporary increase in the size of the cystic hygroma. Depending on the anatomical relations of the tumor, such increases in size may be intolerable and it has been suggested that such therapy should only be administered in specialized facilities due to the risk of airway obstruction [6].

Several authors have expressed the opinion that surgical excision of cystic hygroma is an easier procedure in adult patients, because these lesions are better circumscribed, and as such the success rate is greater [7]. In this case, it was thought that the ideal treatment would be complete surgical excision. There is 81% cure rate if the cystic hygroma has been completely excised and 88% recurrence rate when only part of the cystic hygroma is excised [8]. The procedures that can increase risk of recurrence include unroofing, partial cystectomy and drainage of the contents. In certain cases, complete excision might not be possible if hygroma infiltrates adjacent muscles and neurovascular structures. Some studies suggested that sclerosing agents and radiation therapy may reduce recurrence especially for the cystic hygroma that are not amenable to surgical resection [6,8].

CONCLUSION

Cystic hygromas are a rare differential diagnosis in adult cystic neck masses and should be considered for the adult patients who have neck masses. Surgical excision is the treatment of choice for cystic hygroma in adults.

REFERENCES

1. Cheng LH, Wells FC. A multidisciplinary approach to recurrent cervicothoracic cystic hygroma in an adult. *Br J Oral Maxillofac Surg.* 2004; 42: 66-68.
2. Michail O, Michail P, Kyriaki D, Kolindou A, Klonaris C, Griniatsos J. Rapid development of an axillary mass in an adult: a case of cystic hygroma. *South Med J.* 2007; 100: 845-849.

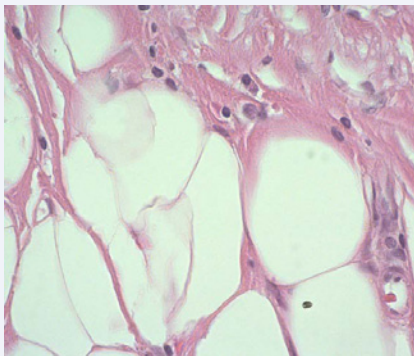


Figure 3 Histopathological examination revealed aggregates of lymphoid cells adjacent to closely packed lymphatic channels.

3. Mirza B, Ijaz L, Saleem M, Sharif M, Sheikh A. Cystic hygroma: an overview. *J Cutan Aesthet Surg.* 2010; 3: 139-144.
4. Sarin YK. Cystic hygroma. *Indian Pediatr.* 2000; 37: 1139-1140.
5. Ito K, Murata T, Nakanishi T. Cystic lymphangioma of the spleen: MR findings with pathologic correlation. *Abdom Imaging.* 1995; 20: 82-84.
6. Mikhail M, Kennedy R, Cramer B, Smith T. Sclerosing of recurrent lymphangioma using OK-432. *J Pediatr Surg.* 1995; 30: 1159-1160.
7. Naidu SI, Mc Calla MR. Lymphatic malformations of the head and neck in adults: a case report and review of the literature. *Ann Otol Rhinol Laryngol.* 2004; 113: 218-222.
8. Stromberg BV, Weeks PM, Wray RC Jr. Treatment of cystic hygroma. *South Med J.* 1976; 69: 1333-1335.

Cite this article

Lian HH, SHA PP (2016) Late- Onset Cystic Hygromas Presenting in an Adult: A Case Report. *Ann Otolaryngol Rhinol* 3(3): 1092.