

## Short Communication

# HIV Infection Associate with Prophylactic Highly Active Antiretroviral Therapy does not Affect Placental Invasion and Endothelial Function in the First Half of Pregnancy

Evilane do Carmo Patrício<sup>1</sup>, Regina Amélia Lopes Pessoa de Aguiar<sup>2</sup>, Henrique Vitor Leite<sup>2</sup>, Victor Hugo de Melo<sup>2</sup>, Antônio Carlos Vieira Cabral<sup>2</sup> and Augusto Henriques Fulgêncio Brandão<sup>3\*</sup>

<sup>1</sup>Physician at the Maternity of Hospital das Clínicas - Universidade Federal de Minas Gerais (UFMG), Brazil

<sup>2</sup>School of Medicine - Universidade Federal de Minas Gerais (UFMG), Brazil

<sup>3</sup>Center of Fetal Medicine, Hospital das Clínicas - Universidade Federal de Minas Gerais (UFMG), Brazil

**\*Corresponding author**

Augusto Henriques Fulgêncio Brandão, Av. Professor Alfredo Balena, 110 – 4º andar – Belo Horizonte – MG – Brazil, Tel: 55-31-3409-9422; Fax: 55-31-8409-4978; Email: augustohfbrandao@hotmail.com

Submitted: 25 February 2015

Accepted: 01 June 2015

Published: 02 June 2015

**Copyright**

© 2015 Fulgêncio Brandão et al.

**OPEN ACCESS****Keywords**

- HIV infection
- Endothelial function
- Placental invasion
- Highly active antiretroviral therapy
- Pregnancy

**Abstract**

**Background:** Highly Active Antiretroviral Therapy (HAART) represented a breakthrough towards vertical transmission of HIV. Despite several reports of important collateral effects, the use of HAART quickly widespread due to its incontestable benefit in decreasing the risk of fetal infection. Endothelial dysfunction and abnormal placentation have been pointed out as one of the consequences of HAART and also as pathophysiological events of many disorders in pregnancy, such as Preeclampsia (PE). The association between PE, HIV and HAART presented conflicted data in literature.

**Objectives:** To evaluate possible differences in endothelial function and placental invasion between HIV-positive pregnant women receiving prophylactic HAART and HIV-negative healthy pregnant women from 16<sup>+0</sup> to 19<sup>+6</sup> weeks of pregnancy.

**Patients and Methods:** In this cross-sectional study, a total of 20 HIV-positive pregnant women and 40 HIV-negative pregnant women were submitted to Flow-mediated dilation (FMD) of brachial artery and doppler fluxometry of uterine arteries, in order to obtain its pulsatility index (UtA-PI).

**Results:** There were no statistical differences between the results of FMD (6,53 ± 3,61 X 4,98 ± 3,17, p=0,13) and UtA-PI (1,08 ± 0,29 X 1,06 ± 0,23, p=0,91) between HIV-positive group and HIV-negative group.

**Conclusions:** our findings suggest adequate placentation and absence of endothelial dysfunction in the first half of pregnancy in HIV positive women using prophylactic HAART.

**ABBREVIATIONS**

HAART: Highly Active Antiretroviral Therapy; PE: Preeclampsia; FMD: Flow-Mediated Dilation, Uta-PI: Uterine Arteries Pulsatility Index; 3TC: Lamivudine; AZT: Zidovudine; LPV/R: Lopinavir/Ritonavir; TDF: Tenofovir

**INTRODUCTION**

Highly active antiretroviral therapy (HAART) represents a breakthrough in vertical transmission of HIV, once it reduced its levels from 25% to less than 1% [1,2]. Prophylactic HAART is defined by the use of 3 antiretroviral drugs in a HIV patient with

no previous indication of these drugs, except pregnancy itself and the intention to reduce vertical transmission of the virus.

Due to its incontestable benefit to the fetus, lowering by near zero, the chance of HIV infection by the mother, not much consideration towards the risks and collateral effects of HAART is done. It is, for instance, well known that antiretroviral drugs, particularly protease inhibitors (IP), can promote dyslipidemia and endothelial dysfunction [3], including damage in the blood-brain barrier [4]. HIV infection, by itself, can also cause endothelial dysfunction [5].

In pregnancy, any loss in the capability of the vascular endothelium to promote vasodilatation may cause a hemodynamic state which leads to acute organ failure, such as in Preeclampsia (PE) [6-8]. Therefore, it is possible to hypothesize that HAART or HIV infection might increase the risk of PE, which is not confirmed in most studies.

Savidou et al. 2011 demonstrated that HIV infection and HAART therapy did not affect placental invasion in the first trimester of pregnancy in women who start taking antiretroviral drugs before pregnancy [9]. The short-term effects towards placental invasion and endothelial function in HIV pregnant women using prophylactic HAART had not been yet reported.

Therefore, our objective is to compare placental invasion, evaluated by Doppler fluxometry of uterine arteries and endothelial function, evaluated by Flow-mediated dilation (FMD), between HIV patients using prophylactic HAART and non-infected pregnant women from 16 to 20 weeks of pregnancy.

## MATERIALS AND METHODS

### Patients

In this cross-sectional study, 20 HIV positive pregnant women using prophylactic HAART, with no other comorbidity, and 40 healthy women, were submitted to Doppler fluxometry of uterine arteries and Flow-mediated dilation (FMD) of brachial artery between 16<sup>th</sup> and 19<sup>th</sup> weeks of pregnancy. HAART was always composed by at least 3 drugs: Lamivudine (3TC) was given to all the 20 HIV positive patients, Zidovudine (AZT) to 11 patients (55%), Lopinavir/Ritonavir (LPV/r) to 13 patients (65%) and Tenofovir (TDF) to 3 patients (15%). The most common association was composed by 3TC+AZT+LPV/r, given to 10 patients (50%).

### Doppler fluxometry of uterine arteries

A transabdominal transducer was placed on the lower quadrant of the abdomen, angled medially, and color Doppler was used to identify the uterine artery, at the apparent crossover with the external iliac artery. Measurements were taken approximately 1 cm distal to the crossover point. Care was taken to ensure that insonation angle was less than 60°.

### Flow-mediated dilation of brachial artery

The assessing of flow-mediated dilatation of the brachial artery was made by using a high-resolution ultrasound with a 5 - 7 MHz linear transducer. The patients rested for 15 minutes before the ultrasound examination in dorsal decubitus. The brachial artery of dominant arm was identified medially in

antecubital fossa. A clearest image of the artery was scanned over a longitudinal section, approximately, 5 cm above the elbow, at the end of the diastole. This moment was monitored using the B-mode of the echocardiographic equipment as the moment presenting the lowest distension of the vessel walls (to prevent larger vascular calibers originated from the vascular distension caused by the systole), which can be correctly captured by receding the image using the equipment cine loop of the equipment. Arterial diameter was obtained from frozen screen images, by calculating the mean of three measurements of the caliber of the vessel (D1). After this first procedure, a pneumatic cuff was inflated, placed on the forearm, distal to the ultrasound imaging site, to suprasystolic pressure (250mmHg) for 5 minutes, and after, the cuff was slowly deflated. One minute after the deflation, the mean of three new measurements of the caliber of the vessel was obtained by the same technique previously described (D2) (Figure 1).

Based on the previously described standards, a new measurement of the brachial artery caliber was carried out. The FMD value was obtained from the following calculation:  $FMD (\%) = [(D2 - D1)/D1] \times 100$ , where D1 = basal diameter and D2 = post-occlusion diameter.

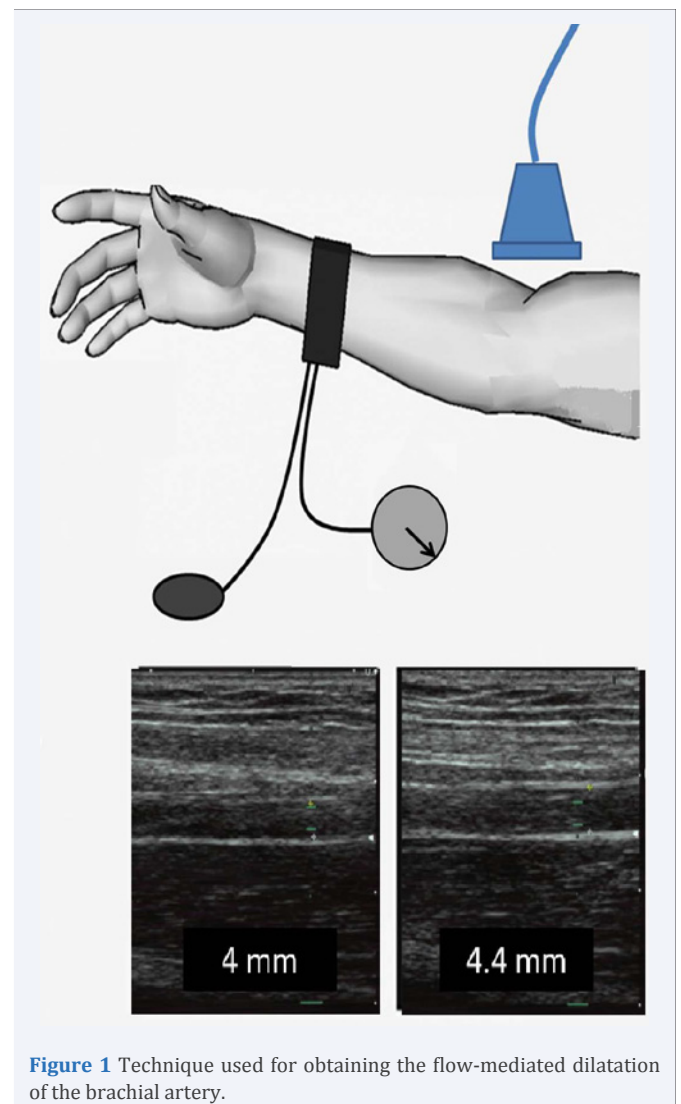


Figure 1 Technique used for obtaining the flow-mediated dilatation of the brachial artery.

## Statistical Analyses

Normality of continuous data was assessed with Shapiro-Wilk test. Student's *t* test was used to compare variables between the two groups. Data was expressed as mean  $\pm$  SD (limits). The statistical analyses were performed using the Statistical Package for Social Sciences (Version 18) (SPSS, Chicago, IL, USA).

## RESULTS AND DISCUSSION

### Results

The descriptive characteristics of the patients are shown in Table 1, as well as viral load and CD4 count in HIV-positive group. There were no significant differences between demographic and pregnancy characteristics.

Flow-mediated dilation of brachial results were no significantly different between HIV-positive and HIV-negative patients. Mean UtA-PI and lower UtA-PI were also no different between the two groups. These results are expressed in Table 2.

## Discussion

Pregnancy is a physiological condition with important endothelial adaptations. Many clinical complications are associated with endothelial dysfunction in pregnancies, as preeclampsia, gestational diabetes and intra-uterine growth restriction (IUGR) [6-8,10,11].

The mechanism involved in endothelial lesion in HIV infection is probably due to an inflammatory response to viral action [12]. The antiretroviral drugs can affect the endothelium by promoting oxidative stress leading to endothelial cell damage [13-15].

The association between HAART and HIV infection could increase the degree of endothelial dysfunction [16,17], but this is a statement not always confirmed by studies [18].

Our results showed absence of endothelial dysfunction in HIV group, once FMD results were similar to control group. Possible explanations for this fact are the low viral count with high levels of CD4 in HIV patients in this particular group. Only 8 patients (40%) have viral load higher than 1000 copies/mL and only

**Table 1:** Descriptive characteristics of the 60 patients divided into the 2 groups in the study.

	HIV-positive patients (n=20)	HIV-negative patients (n=40)	p value
<b>Maternal Age (years)</b>	30,71 $\pm$ 5,71 (18 - 30)	28,21 $\pm$ 5,80 (18 - 28)	0,14
<b>Number of Gestations</b>	2,71 $\pm$ 2,28 (1 - 7)	2,16 $\pm$ 1,45 (1 - 10)	0,37
<b>Gestational Age (weeks)</b>	17,65 $\pm$ 1,32 (16 - 19)	17,37 $\pm$ 1,29 (16 - 20)	0,47
<b>Racial Group</b>			
White	9 (45%)	17 (42,5%)	0,97
Black	6 (30%)	13 (32,5%)	
Other	5 (25%)	10 (25%)	
<b>Body Mass Index (Kg/m<sup>2</sup>)</b>	21,95 $\pm$ 3,36 (18,56 - 29,41)	22,67 $\pm$ 5,87 (15,17 - 37,34)	0,88
<b>Systolic Blood Pressure (mmHg)</b>	114,1 $\pm$ 10,6 (90,00 - 130,00)	114,5 $\pm$ 11,3 (90,00 - 130,00)	0,89
<b>Diastolic Blood Pressure (mmHg)</b>	73,53 $\pm$ 8,52 (60,00 - 90,00)	75,58 $\pm$ 8,25 (60,00 - 90,00)	0,84
<b>Mean Arterial Blood Pressure (mmHg)</b>	87,06 $\pm$ 8,65 (70 - 100)	88,56 $\pm$ 8,82 (70 - 103,33)	0,55
<b>CD4 count (cells/mL)</b>	599,5 $\pm$ 203,9 (144 - 907)		
<200 cells/mL	1 (5%)	*	*
>200 cells/mL	19 (95%)		
<b>Viral load (copies/mL)</b>	3955 $\pm$ 8043 (20 -29684)		
>1000 copies	8 (40%)	*	*
<1000 copies	8 (40%)		
undetectable	4 (20%)		

**Table 2:** Results of Flow-mediated dilation of brachial artery and Pulsatility Index of Uterine arteries of the 2 groups.

	HIV-positive patients (n=20)	HIV-negative patients (n=40)	p value
<b>Brachial artery basal diameter (mm)</b>	3,32 $\pm$ 0,38 (2,56 - 4,08)	3,33 $\pm$ 0,49 (2,65 - 4,57)	0,97
<b>Flow-mediated dilation (%)</b>	6,53 $\pm$ 3,61 (1,00 - 16,00)	4,98 $\pm$ 3,17 (0,00 - 12,00)	0,13
<b>Mean UtA-PI</b>	1,08 $\pm$ 0,29 (0,73 - 1,91)	1,06 $\pm$ 0,23 (0,69 - 1,55)	0,91
<b>Lower UtA-PI</b>	1,00 $\pm$ 0,29 (0,65 - 1,83)	0,93 $\pm$ 0,23 (0,56 - 1,52)	0,57

**Note:** UtA-PI - Uterine arteries - Pulsatility Index

one patient (5%) had a CD4 count lower than 200 cells/mL. The short period that HIV group was taking HAART could also be insufficient to promote any kind of endothelial dysfunction.

Another complication associated with endothelium lesion in pregnancy is placental dysfunction [19,20]. Our results also showed absence of abnormal placental invasion, once UtA-PI had no significant differences between the two groups. Our results are similar to another study developed in United Kingdom with 76 HIV-positive pregnant women taking prophylactic or therapeutic HAART [9].

## CONCLUSION

Our findings suggest adequate placentation and absence of endothelial dysfunction in the first half of pregnancy in HIV positive women using prophylactic HAART. These results corroborate studies that show no increase of pregnancy complications related to these pathophysiological events, such as PE and IUGR [21,22].

## ACKNOWLEDGEMENTS

We would like to thank Jorge Andrade Pinto for all his contribution to this study.

## REFERENCES

1. Kourtis AP, Bansil P, McPheeters M, Meikle SF, Posner SF, Jamieson DJ. Hospitalizations of pregnant HIV-infected women in the USA prior to and during the era of HAART, 1994-2003. *AIDS*. 2006; 20: 1823-1831.
2. UNAIDS. 2008 Report on the global AIDS epidemic. Status of the global HIV epidemic. 2011.
3. Troll JG. Approach to dyslipidemia, lipodystrophy, and cardiovascular risk in patients with HIV infection. *Curr Atheroscler Rep*. 2011; 13: 51-56.
4. Manda, KR, Banerjee A, Banks WA, Ercal N. Highly active antiretroviral therapy drug combination induces oxidative stress and mitochondrial dysfunction in immortalized human blood-brain barrier endothelial cells. *Free Radic Biol Med*. 2011; 50: 801-810.
5. Solages A, Vita JA, Thornton DJ, Murray J, Heeren T, Craven DE. Endothelial function in HIV-infected persons. *Clin Infect Dis*. 2006; 42: 1325-1332.
6. Gant NF, Whalley PJ, Everett RB, Worley RJ, MacDonald PC. Control of vascular reactivity in pregnancy. *Am J Kidney Dis*. 1987; 9: 303-307.
7. Jim B, Sharma S, Kebede T, Acharya A. Hypertension in pregnancy: a comprehensive update. *Cardiol Rev*. 2010; 18: 178-189.
8. Young BC, Levine RJ, Karumanchi SA. Pathogenesis of preeclampsia. *Annu Rev Pathol*. 2010; 5: 173-192.
9. Savvidou MD, Samuel MI, Akolekar R, Poulton M, Nicolaides KH. First trimester maternal uterine artery Doppler examination in HIV-positive women. *HIV Med*. 2011; 12: 632-636.
10. Anastasiou E, Lekakis JP, Alevizaki M, Papamichael CM, Megas J, Souvatzoglou A, et al. Impaired endothelium-dependent vasodilatation in women with previous gestational diabetes. *Wien Klin Wochenschr*. 2007; 119: 483-489.
11. Steinberg HO, Chaker H, Leaming R, Johnson A, Brechtel G, Baron AD. Obesity/insulin resistance is associated with endothelial dysfunction. Implications for the syndrome of insulin resistance. *J Clin Invest*. 1996; 97: 2601-2610.
12. Ross AC, Armentrout R, O'Riordan MA, Storer N, Rizk N, Harrill D. Endothelial activation markers are linked to HIV status and are independent of antiretroviral therapy and lipodystrophy. *J Acquir Immune Defic Syndr*. 2008; 49: 499-506.
13. Behrens G, Schmidt H, Meyer D, Stoll M, Schmidt RE. Vascular complications associated with use of HIV protease inhibitors. *Lancet*. 1998; 351: 1958.
14. De Gaetano Donati K, Rabagliati R, Tumbarello M, Tacconelli E, Amore C, Cauda R, et al. Increased soluble markers of endothelial dysfunction in HIV-positive patients under highly active antiretroviral therapy. *AIDS*. 2003; 17: 765-768.
15. Baliga RS, Liu C, Hoyt DG, Chaves AA, Bauer JA. Vascular endothelial toxicity induced by HIV protease inhibitor: evidence of oxidant-related dysfunction and apoptosis. *Cardiovasc Toxicol*. 2004; 4: 199-206.
16. Wimalasundera RC, Larbalestier N, Smith JH, De Ruiter A, McG Thom SA, Hughes AD. Pre-eclampsia, antiretroviral therapy, and immune reconstitution. *Lancet*. 2002; 360: 1152-1154.
17. Suy, Martínez E, Coll O, Lonca M, Palacio M, De Lazzari E. Increased risk of pre-eclampsia and fetal death in HIV-infected pregnant women receiving highly active antiretroviral therapy. *AIDS*. 2006; 20: 59-66.
18. Mattar R, Amed AM, Lindsey PC, Sass N, Daher S. Preeclampsia and HIV infection. *Eur J Obstet Gynecol Reprod Biol*. 2004; 117: 240-241.
19. Plasencia W, Maiz N, Poon L, Yu C, Nicolaides KH. Uterine artery Doppler at 11 + 0 to 13 + 6 weeks and 21 + 0 to 24 + 6 weeks in the prediction of pre-eclampsia. *Ultrasound Obstet Gynecol*. 2008; 32: 138-146.
20. Huppertz B. Placental origins of preeclampsia: challenging the current hypothesis. *Hypertension*. 2008; 51: 970-975.
21. Bodkin C, Klopper H, Langley G. A comparison of HIV positive and negative pregnant women at a public sector hospital in South Africa. *J Clin Nurs*. 2006; 15: 735-741.
22. Frank KA, Buchmann EJ, Schackis RC. Does human immunodeficiency virus infection protect against preeclampsia-eclampsia? *Obstet Gynecol* 2004; 104: 238-242.

### Cite this article

do Carmo Patrício E, Lopes Pessoa de Aguiar RA, Leite HV, de Melo VH, Vieira Cabral AC, et al. (2015) HIV Infection Associate with Prophylactic Highly Active Antiretroviral Therapy does not Affect Placental Invasion and Endothelial Function in the First Half of Pregnancy. *Clin Res HIV/AIDS* 2(3): 1024.