

Case Report

Combined Heart-Liver Transplant in a Child Following Failed Single Ventricle Palliation

John P Scott*, George M Hoffman, James S Tweddell, David C Cronin II, L. Eliot May and Harvey J Woehlk

Department of Anesthesiology and Pediatrics, Sections of Pediatric Anesthesia and Pediatric Critical Care, Medical College of Wisconsin, USA

INTRODUCTION

Palliated single ventricle anatomy imposes unique physiologic limitations that increase the risk for cardiac and end organ failure. Patients with failing univentricular circulation often have very high systemic venous pressures as a result of the superimposition of the trans-pulmonary pressure gradient on elevated ventricular end-diastolic pressure, with increased risk of cardiac cirrhosis and end stage liver disease. Here we present the case of a 14-year-old male, with failed bidirectional Glenn circulation and cardiac cirrhosis, who required a combined heart-liver transplant (CHLT). Informed consent from the patient's legal guardian was obtained for this case report.

CASE REPORT

The patient had double inlet single left ventricle with L-transposition of the great arteries (Figure 1), palliated with pulmonary artery banding at 3 months of age, and subsequent bidirectional Glenn at 10 months of age. At age 22 months, he underwent septation of his double inlet single left ventricle and pulmonary arterioplasty rather than complete Fontan cavopulmonary reconstruction (Figure 2). He required pacemaker placement for sick sinus syndrome, but remained at NYHA class 3 functional status. At age 11, was listed for heart transplantation secondary to congestive heart failure with disseminated systemic venous hypertension. His longstanding Glenn physiology and venous hypertension was associated with extensive systemic to pulmonary collateral formation and worsening hypoxemia secondary to veno-arterial admixture, requiring multiple catheter based interventions for collateral occlusion. These veno-arterial shunts contributed to increased cyanosis and reduced myocardial performance. Pretransplant cardiac catheterization revealed elevated Glenn pressures within the superior vena cava (17 mmHg), main pulmonary artery (22/18, mean 20 mmHg), left pulmonary artery (20/16, mean 19 mmHg), and right pulmonary artery (20/18, mean 19 mmHg). The right atrial pressure was significantly elevated (19 mmHg), consistent with pressure elevations in the hypoplastic right ventricle (24/0, mean 14 mmHg). Left ventricular end diastolic pressure was also elevated (17 mmHg). He was found to have portal hypertension

*Corresponding author

John P Scott, MD, Departments of Anesthesiology and Pediatrics, Sections of Pediatric Anesthesia and Pediatric Critical Care, Medical College of Wisconsin, 9000 W Wisconsin Ave. PO Box 1997, Milwaukee WI, 53201-3022, Tel: 4142663560; Fax: 4142666092; Email: scottjake@mcw.edu

Submitted: 24 October 2013

Accepted: 15 January 2014

Published: 21 January 2014

Copyright

© 2014 Scott et al.

OPEN ACCESS

with elevated hepatic venous wedge pressures (20 mmHg within the right hepatic lobe and 21 mmHg within the left hepatic lobe) which were similar to measured right atrial pressures. While awaiting heart transplantation, he developed cirrhosis confirmed via liver biopsy. Due to the end stage nature of his heart and liver disease he was listed for combined organ transplantation. His pretransplant course was further complicated by pulmonary hemorrhage from ruptured paratracheal varices. These varices extended from the proximal trachea to the mainstem bronchi, and were treated with trans-catheter coiling. He also experienced gastrointestinal bleeding secondary to large (grade III) esophageal varices that required banding. He spent a protracted period of time on the transplant list awaiting a suitable donor.

On the day of transplant, intraoperative monitoring included

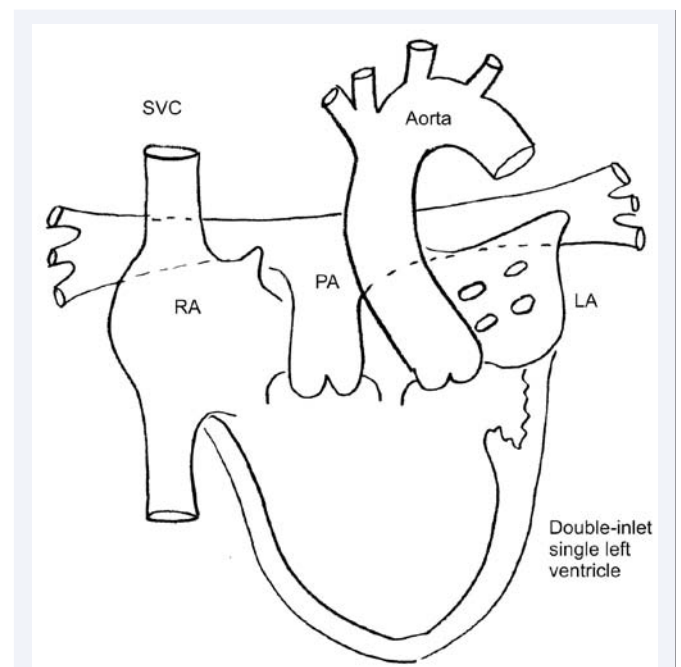


Figure 1

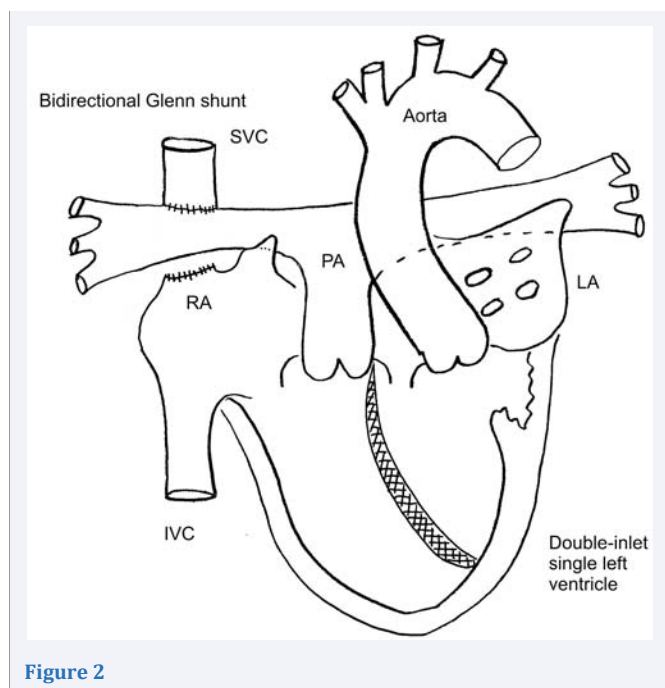


Figure 2

electrocardiogram, pulse oximetry, non-invasive and invasive arterial blood pressure, central venous pressure (CVP), and two-site (cerebral and somatic) near-infrared spectroscopy (NIRS) (Somanetics INVOS, Troy, MI). Anesthesia was induced with intravenous midazolam, fentanyl, and sevoflurane and maintained with fentanyl and isoflurane. Cisatracurium was administered for neuromuscular blockade. Oral endotracheal intubation was performed without fiberoptic guidance as pretransplant flexible bronchoscopy revealed complete decompression of his tracheal varices. Intravenous access included a right internal jugular vein introducer (8.5 Fr), a triple lumen left subclavian central venous line (7.5 Fr), and bilateral antecubital fossa rapid infusion catheters (7.5 Fr and 4.5 Fr). Pressure in the superior vena cava (SVC) varied from 18-25 mmHg throughout the pre-bypass period. Transesophageal echocardiography (TEE) was also utilized.

Orthotopic heart transplantation with cardiopulmonary pulmonary bypass (CPB) was performed first in order to minimize donor myocardial ischemic time. Tranexamic acid was administered as antifibrinolytic therapy per protocol: 50 mg/kg IV loading dose, 50 mg/kg in the CPB pump prime, and 15 mg/kg continuous IV infusion. The patient's bidirectional Glenn anastomosis was taken down prior to donor heart implantation.

Donor heart ischemic time was 217 minutes. Following successful reanimation of the donor heart the patient separated from CPB on epinephrine (0.1 mcg/kg/min) and milrinone (0.75 mcg/kg/min) infusions, a vasoactive strategy targeting low pulmonary and systemic vascular resistance and high contractility. The CVP ranged from 6 to 8 mmHg, and left atrial pressure (LAP) from 4 to 6 mmHg. The patient's systemic venous hypertension was markedly improved following cardiac transplantation. Ventilatory management after liberation from CPB included inhaled nitric oxide (iNO) to reduce right ventricular afterload, optimize right ventricular function and minimize

central venous pressure prior to liver transplantation. Post-CPB TEE demonstrated good left ventricular systolic function, mildly reduced right ventricular systolic function, trivial mitral regurgitation, and no tricuspid regurgitation. Heparin effect was fully reversed with protamine and hemostasis achieved.

With the patient's sternum left open, and after hemodynamic and hemostatic stabilization, transplantation of the liver began. Venovenous bypass (VVB) was used during the anhepatic phase. Venous inflow was provided by cannulation of the left superficial saphenous vein, and return provided through the indwelling right atrial venous cannula used during the cardiac transplant. Flow on systemic VVB was approximately 1.3 L/min and was further augmented to over 2 L/min with addition of portal venous blood to the VVB circuit. Complete caval replacement technique utilizing the donor IVC graft followed by portal venous reperfusion was performed for liver allograft implantation. Cold ischemic time for the donor liver was approximately 480 minutes. Reperfusion was tolerated well without hemodynamic instability, arrhythmia or reperfusion syndrome and the patient was removed from VVB on continued inotropic support with epinephrine (0.08 mcg/kg/min) and milrinone (1 mcg/kg/min). CVP ranged from 5 to 7 mmHg, and LAP from 2 to 4 mmHg during reconstruction of the hepatic artery and bile duct. Intraoperative coagulation was assessed with thromboelastography (TEG[®], Haemoscope Corp. IL, USA), activated clotting times, and heparin concentrations (Hepcon[®] HMS, Medtronic Inc. MN, USA). A total of 11 units of packed red blood cells, 24 units of fresh frozen plasma, 18 units of cryoprecipitate, 3 single donor pheresed units of platelets, and 2 liters of cell saver blood were administered throughout the combined procedure. After ensuring satisfactory hemostasis and hemodynamics, the sternum and abdomen were closed sequentially. The patient tolerated the procedure well, and was transferred to the intensive care unit with mechanical ventilation and inotropic support. The intraoperative monitoring strategy and hemodynamic management were continued in the postoperative period.

DISCUSSION

Although uncommon in the pediatrics, CHLT has classically been performed for inherited metabolic diseases. One such example is familial hypercholesterolemia in which a defect in hepatic cholesterol metabolism results in early advanced atherosclerosis [1,2]. Another is familial amyloidosis in which heart failure results from defective protein folding within the myocytes [3,4]. In these diseases, CHLT is required to replace the damaged heart and reverse the metabolic defect with a normal liver. Cardiac failure from complex congenital heart disease with secondary liver failure has represented a rare indication for pediatric CHLT [5].

Single ventricle anatomy as occurs in the patients with hypoplastic left heart syndrome requires sequential palliative procedures to create functional series circulation. Palliation is necessary for survival beyond infancy, but long-term morbidity and early mortality remain. Complications of failed single ventricle physiology include congestive heart failure, arrhythmias, venous hypertension, plastic bronchitis, protein losing enteropathy, and liver dysfunction [6]. Heart transplantation may be curative in such cases. Single ventricle palliation is associated with an

increased risk of nonalcoholic cirrhosis [7]. Most commonly this occurs in patients with Fontan physiology, however extensive liver fibrosis has also been shown prior to Fontan completion [8].

The incidence of cirrhosis in single ventricle patients appears to be increasing. Krieger et al noted a 173% increase in the incidence of admissions for cirrhosis in single ventricle patients from 1998 to 2009. When compared to single ventricle patients without cirrhosis, those with cirrhosis were more likely to have concurrent congestive heart failure⁷. This evidence suggests that failed single ventricle physiology with concurrent cardiac and hepatic failure is likely to be an emerging indication for pediatric CHLT.

Anesthetic considerations are complex for CHLT in patients with palliated single ventricle heart disease. A comprehensive preoperative evaluation is critical to assess for associated comorbidities (arrhythmias, pulmonary collaterals, pulmonary hypertension, hepatorenal renal syndrome, hepatopulmonary syndrome, hepatic encephalopathy, etc.), and to optimize preoperative health status. Massive transfusion is to be expected during CHLT and adequate blood product availability must be confirmed preoperatively. Intraoperatively, large bore peripheral intravenous access is required, as are intra-arterial and central venous pressure monitoring. Different anesthetic induction strategies are commonly employed for isolated heart or liver transplantation. End stage cardiac disease is associated with reduced cardiac output and prolonged intravenous induction times. Induction for heart transplantation is usually involves premedication followed by a gradual balanced induction including a combination of intravenous (opiates, benzodiazepines and/or etomidate) and volatile agents. Rapid sequence inductions tend to be avoided due to concerns for profound hemodynamic lability, particularly in patients with palliated univentricular hearts. In contrast, end stage liver disease is associated with increased cardiac output and shortened intravenous induction times. Typically, a rapid sequence intravenous induction without excessive premedication is recommended for liver transplantation to minimize risk of aspiration. These differences must be considered and addressed during CHLT. In this instance, we utilized premedication and a balanced induction technique with cricoid pressure in order to preserve cardiac output and perfusion while attempting to reduce aspiration risk. Additional concerns relate to risks associated with instrumentation of the trachea and esophagus in patients with variceal disease. Proper endotracheal tube placement may require fiberoptic guidance in patients with tracheal varices. Similarly, esophageal varices must be considered prior to TEE and gastric tube placement in patients with esophageal varices.

Surgical techniques employed for CHLT include: 1) implantation of both organs on CPB, with an additional portal venous cannula; 2) heart implantation on CPB, and liver implantation on VVB, with an additional portal venous cannula; 3) heart implantation on CPB and liver implantation without bypass. When choosing a method for implantation of the donor organs, the team must be cognizant of the divergent physiologic needs of each donor organ. Acute right heart failure is common following heart transplantation and may be exacerbated by elevated recipient pulmonary artery pressures, pulmonary vein

pressures, and interstitial lung disease. In recipients with pre-existing pulmonary hypertension, the transplanted right ventricle may exhibit restrictive physiology with preload dependence and require pulmonary vasodilator (inhaled nitric oxide, intravenous milrinone, etc.) therapy to compensate for increased right ventricular afterload. The right ventricle is at risk for coronary ischemia and concurrent systemic vasopressor administration may be needed to maintain adequate right coronary artery perfusion pressure. In patients with pulmonary arteriovenous malformations, arterial hypoxemia occurs at low trans-pulmonary pressure gradients. Both right heart dysfunction and veno-arterial admixture will improve with inhaled nitric oxide. In contrast to the donor heart, the optimal environment following donor liver implantation is one of low systemic venous pressure to limit hepatic venous congestion. These competing goals must be recognized and dynamically prioritized during combined organ transplantation.

In this case we chose heart implantation on CPB and liver implantation on VVB. We were concerned that the unconditioned donor right ventricle would fail without the preload preservation provided via VVB, yet the need for full anticoagulation with CPB during liver transplantation would be undesirable. We were able to reverse heparin fully following CPB, permitting optimal hemostasis prior liver transplantation. A heparin-bonded circuit was used for VVB, negating the need for additional anticoagulation. VVB support allowed for preload preservation and reduced vasoactive medication requirements during liver implantation. This also provided vital time for donor right heart recovery following ischemia such that the systemic venous pressures following liver reperfusion were acceptable with central venous pressures generally less 10 mmHg. This strategy ultimately proved successful as the both grafts functioned well following implantation.

In this example, failed univentricular physiology with end stage heart and liver disease was treated with combined heart-liver transplantation. As growing numbers of single ventricle patients survive staged palliation pathways with ongoing physiologic limitation, it is likely that many will require combined organ transplantation and management expertise in the perioperative care of congenital heart disease, cardiac transplantation, and hepatic transplantation.

REFERENCES

1. Starzl TE, Bilheimer DW, Bahnson HT, Shaw BW Jr, Hardesty RL, Griffith BP, et al. Heart-liver transplantation in a patient with familial hypercholesterolaemia. *Lancet*. 1984; 1: 1382-1383.
2. Figuera D, Ardaiz J, Martín-Júdez V, Pulpón LA, Pradas G, Cuervas-Mons V, et al. Combined transplantation of heart and liver from two different donors in a patient with familial type IIa hypercholesterolemia. *J Heart Transplant*. 1986; 5: 327-329.
3. Schwartz BG, Kuiper JJ, Klintmalm GB, Stone MJ, Schussler JM. Combined cardiac and liver transplantation for the treatment of familial amyloidosis. *Proc (Bayl Univ Med Cent)*. 2007; 20: 146-148.
4. Barreiros AP, Post F, Hoppe-Lotichius M, Linke RP, Vahl CF, Schäfers HJ, et al. Liver transplantation and combined liver-heart transplantation in patients with familial amyloid polyneuropathy: a single-center experience. *Liver Transpl*. 2010; 16: 314-323.
5. Hollander SA, Reinhartz O, Maeda K, Hurwitz M, N Rosenthal D,

- Bernstein D. Intermediate-term outcomes after combined heart-liver transplantation in children with a univentricular heart. *J Heart Lung Transplant.* 2013; 32: 368-370.
6. de Leval MR, Deanfield JE. Four decades of Fontan palliation. *Nat Rev Cardiol.* 2010; 7: 520-527.
 7. Krieger EV, Moko LE, Wu F, Landzberg MJ, Valente AM, Assenza GE, et al. Single ventricle anatomy is associated with increased frequency of nonalcoholic cirrhosis. *Int J Cardiol.* 2013; 167: 1918-1923.
 8. Schwartz MC, Sullivan L, Cohen MS, Russo P, John AS, Guo R, et al. Hepatic pathology may develop before the Fontan operation in children with functional single ventricle: an autopsy study. *J Thorac Cardiovasc Surg.* 2012; 143: 904-909.

Cite this article

Scott JP, Hoffman GM, Tweddell JS, Cronin DC II, May LE, et al. (2014) Combined Heart-Liver Transplant in a Child Following Failed Single Ventricle Palliation. *Int J Clin Anesthesiol* 2(1): 1023.