

Research Article

Observational Study of Intra-Articular Lidocaine for Management of Shoulder-Dislocation at Sylvanus Olympio University Teaching Hospital, Togo

Hamza Doles Sama^{1*}, Aboudoul Fataou Ouro Bang'na Maman¹,
Raweuginbasba Armel Flavien Kabore² and Mofou Belo³

¹Department of Anesthesiology and Intensive Care, Sylvanus Olympio University Teaching Hospital, Togo

²Department of Anesthesiology, Charles de Gaulle Pediatric Hospital, Burkina Faso

³Department of Neurology, Sylvanus Olympio University Teaching Hospital, Togo

***Corresponding author**

Sama Hamza Dolès, Department of Anesthesiology and Intensive Care, Sylvanus Olympio University Teaching Hospital, Lomé, TOGO, Email: hamzasama@hotmail.com

Submitted: 24 January 2014

Accepted: 05 February 2014

Published: 06 June 2014

ISSN: 2333-6641

Copyright

© 2014 Sama et al.

OPEN ACCESS**Keywords**

- Shoulder dislocation
- Intra-articular lidocaine
- Developing countries

Abstract

Background: Intra-articular injection of lidocaine is a recognized anesthetic technique for closed reduction of Anterior Internal Shoulder Dislocation (AISD), which may be of particular benefit to patients in developing countries.

Methods: A prospective observational study was conducted of patients admitted to the Sylvanus Olympio University Teaching Hospital, Togo with a diagnosis of AISD between August 1 2010 and March 31 2011. Demographic and relevant clinical data, including patient satisfaction were collected.

Results: 60 patients with AISD were admitted during this period. There was a male predominance (75%), with median age of 33 years. The injury had occurred in the street in 35 cases. Sub-coracoid dislocation was demonstrated on X-ray in 42 cases. Intra-articular lidocaine 2% was administered and was effective 3 minutes after injection in most cases, with a success rate of 95%. 54 patients required less than 5ml lidocaine 2% in total. No immediate complications were reported, and patient satisfaction was high.

Conclusion: The use of intra-articular lidocaine is a useful technique for reduction of AISD, which should be considered in developing countries.

INTRODUCTION

Closed reduction of Anterior Internal Shoulder Dislocation (AISD) using Intra Articular infiltration of Lidocaine (IAL) has been shown to provide equivalent quality of outcome compared to neuroleptanalgesia [1-3]. IAL has been described as a first line therapy for AISD in the Emergency Department (ED) in high-income countries as it is safe, effective, reduces time in the ED, and rate of adverse events is low compared to intravenous procedural sedation with narcotic [4,5]. In sub-Saharan Africa, the risks of anesthesia are increased due to a combination of poor socioeconomic conditions, lack of physician anesthetists

and lack of equipment [6,7]. The main objective of this study was to evaluate the practice of IAL for reducing AISD in a developing country where provision of safe anaesthesia is challenging. The specific objectives were to describe the epidemiology of patients with AISD, the quantity of lidocaine 2% injected, the patient satisfaction, the surgical complications, the success rate, and the predictive factors of failure of IAL.

PATIENTS AND METHODS

Ethics approval was gained from the hospital ethics committee, and all patients taking part in the study gave informed consent. All patients admitted for radiologically confirmed AISD

(see Figure 1) at Sylvanus Olympio Teaching Hospital, Lomé, were eligible for inclusion in the study. Data was collected prospectively from August 1, 2010 to March 31, 2011. Exclusions included patients with suspected complications of AISD (vascular or nerve injuries), unconscious patients, or those in which AISD reduced spontaneously. All data were entered into a standard survey form, and included patient demographics, circumstances and mechanism of shoulder injury, time to admission, clinical and initial post-reduction radiological assessments, type of reduction technique, and time between dislocation and admission and to shoulder reduction. Patient satisfaction was evaluated by assessment of visual analogue pain score for the procedure and satisfaction rating scale (very satisfied, satisfied, or disappointed). All ratings of pain and satisfaction were submitted anonymously. Success or failure of the reduction, complications, and postoperative analgesia requirements were identified.

Technique for IAL

All reductions were performed by a trained operator. After surgical scrub, including the use of sterile gloves, the operator stood facing the patient on the side of the dislocated shoulder, with the patient sitting on the examination table (see Figure 2). The operator located the glenoid cavity by palpating the acromion and the humeral head. The skin next to the empty glenoid was cleaned using 10% povidone iodine. The operator inserted a 3.5 cm, 23-gauge needle attached to a 10 mL syringe containing 2% lidocaine, into the glenoid cavity, perpendicular

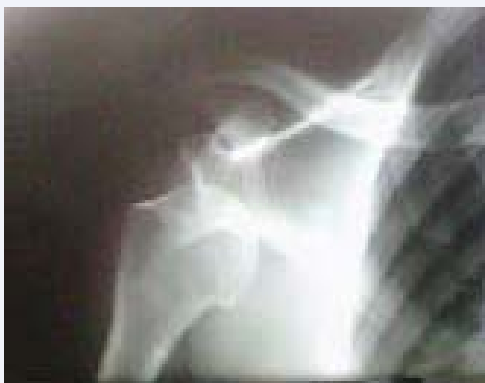

Figure 1 X-ray demonstrating subcoracoid glenohumeral dislocation.

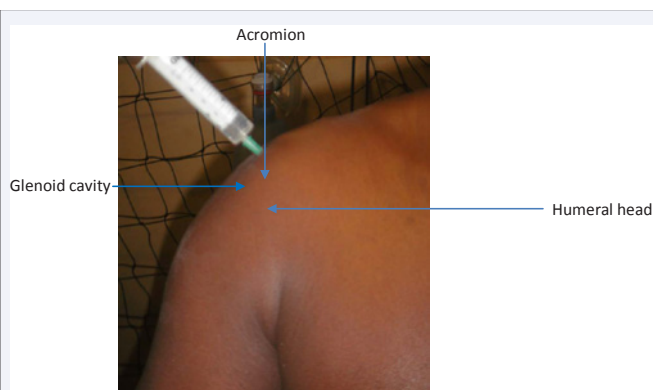


Figure 2 Technique of injection of intra articular lidocaine.

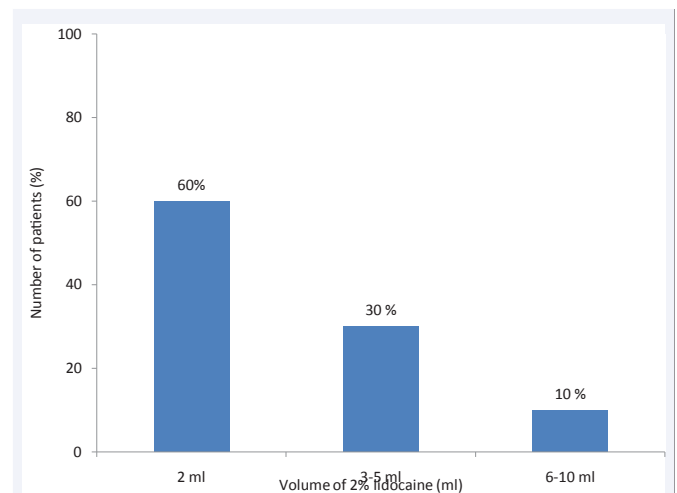


Figure 3 Volume of 2% lidocaine required (ml) for shoulder reduction.

to the skin. Blood or fluid from the post traumatic haematoma was aspirated indicating that the tip of the needle was in the glenoid cavity, or if the joint was dry, the needle was inserted until a “pop” was felt, indicating that the needle was placed inside the glenoid fossa. Lidocaine was injected slowly until pain was relieved, and the reduction could be performed. The dose of 2% lidocaine was analyzed according to the age of the patient, weight, time from injury to presentation and reduction of the dislocation. For statistical analysis, we used Epi Info™ 7 (Centers for Disease Control and Prevention, Atlanta, GA, USA).

RESULTS

Sixty patients who met our inclusion criteria were selected out of the 89 patients admitted for AISD during the study period. The incidence of AISD at Sylvanus Olympio Teaching Hospital in 8 months was 4.7% of all shoulder traumas. There was a male predominance (75% of cases). The median age was 33 years, ranging from 18-70 years old. Ten (17%) patients had a history of shoulder trauma. Fifty-nine percent of cases were traffic-related injuries. The mechanism was direct trauma in 40 (67%) cases. A single case of AISD occurred spontaneously. Pain and functional disability were found in all patients. Only four (7%) patients did not present the classic attitude of upper-limb trauma. There were 42 (70%) cases of sub coracoid dislocation. Patients were classified according to the American Society of Anesthesiology into ASA I (57 patients, 95%), ASA II (2 patients, 3%), and ASA III (1 patient, 2%). Five patients received premedication with 0.1 mg/kg midazolam IV. The operator was a trainee surgeon in all cases, and all general anesthetics were administered by nurse anesthetists. IAL was performed as described in the methods and illustrated in figure 2. The volume of 2% lidocaine required for shoulder reduction is shown in Figure 3. The maximum dose of lidocaine 2% used was 10 ml (200mg), the minimum dose, 2 ml (40 mg) and the median dose, 5 ml (100 mg). The onset of action was less than 3 minutes in 35 (58%) cases (Table 1). The duration of 2% lidocaine analgesia and the volume administered is shown in Table 2. The median time before patient admission was 4 hours (range 1–18 hours); 54 (90%) patients were seen in the first 6 hours. Mean time from dislocation until reduction was 8 ± 7 hours. Median delay between time of admission

and reduction was 4 hours (range 1-19 hours). We treated 58 patients in the first 8 hours after admission. All patients underwent closed reduction of shoulder dislocation. The Milch method was performed in 46 (77%) patients, and the Kocher method in 14 (23%) patients. There was a 95% success rate (57 patients), and the three cases of failure were successfully reduced under General Anesthesia (GA). A total of 57 (95%) patients were satisfied after reduction and received analgesics orally. The three patients who failed reduction after IAL were not satisfied; the patients presented with residual pain, with visual analog pain score scale ≥ 4 . They required reduction of dislocation under GA, multimodal analgesia with intravenous paracetamol and nefopam and nonsteroidal anti inflammatory drugs for 48 – 72 hours orally. AISD reduction was easy for the operator in 46 (77%) cases, but difficult in 14 (23%) cases. The risk of failure was correlated with the radiological type of AISD; the intra coracoid form of dislocation had a high risk of failure ($P = 0.0021$). We did not find any significant difference between the technique used and the reduction result. Difficulty encountered during the reduction contributed to a failure rate of 14%. After reduction, all patients underwent upper-limb immobilization for 21 days, followed by six sessions of physiotherapy for 3 weeks. The cost of treatment was US\$ 40 under IAL and US\$ 100 after failure and conversion to GA.

DISCUSSION

Anterior Internal Shoulder Dislocation (AISD) is one of the most common osteoarticular injuries, occurring most commonly as the result of a road traffic accident in our setting. We have demonstrated that reduction of AISD using intra-articular lidocaine is cost-effective and associated with high patient satisfaction, and can be performed by non-specialist staff in a developing country, despite relatively delayed presentations after injury. No complications were seen due to IAL administered using a landmark technique.

Uncomplicated AISD was noted in 4.7% of patients presenting to our institution with shoulder trauma, higher than Owens et al (0.17% of shoulder injuries) [8]. The cause of dislocation was most often related to road traffic accidents (58%), in contrast to other authors who have noted 48% of injuries to be sport-related [9].

The efficacy of IAL in shoulder-dislocation management is well documented [10]. High quality analgesia can be achieved using IAL compared to standard intravenous agents, with

Table 1: Delay of action of 2% lidocaine (patient reported).

Lidocaine (delay of action)	<3 minutes	3-5 minutes	6-10 minutes
Patient (n/%)	35 (58%)	19 (32%)	6 (10%)

Table 2: Volume of 2% lidocaine administered and duration of analgesia.

Lidocaine (ml)	<15 minutes (n)	15-30 minutes (n)	31-60 minutes (n)	>60 minutes (n)
2 mL	2	9	3	22
3-5 mL	1	1	4	12
6-10 mL	1	1	0	4

markedly reduced time in the emergency department [1,3]. In our study, a median dose of 5 mL lidocaine 2% (20 mg/mL) or 100 mg produced sufficient analgesia for reduction of AISD, and was half that used by Ng et al [1]. Reducing the dose of local anesthetic minimizes the risk of toxicity and prevents possible complications; 90% of patients felt no pain 5 minutes after IAL, despite the small doses of lidocaine used. The duration of lidocaine after intra-articular injection was ≥ 15 minutes, which is sufficient to reduce AISD and provide a temporary sensation of well-being and comfort to patients. Risk of local anesthetic complication could be further reduced by ultrasound-controlled injection, but this is not available in our institution [11].

All patients underwent a reduction maneuver of involving positioning the shoulder such that spontaneous reduction was achieved. Recent studies have shown that newer techniques such as Stimson and Milch's are easy, safe and effective, and associated with fewer complications than Kocher's and Hippocratic techniques [12]. After reduction, all patients underwent upper-limb immobilization in internal rotation, in accordance with the literature [13]. No complications were found at two-month follow-up after the reduction, for instance, injury to the circumflex nerve or axillary artery, fracture of the glenoid, or infection in the region.

We were prepared in each instance for GA conversion in case of failure. The three cases of failed reduction were probably due to lack of relaxation of the shoulder muscles; of note these cases were all successfully reduced under GA by the same operator. Interscalene block may have improved outcomes further, and reduced local anesthetic requirements, but is not currently possible in our context [6,14]. Our results of IAL showed a success rate of 95%. The dissatisfaction of three patients because of pain during the reduction could be explained by lack of analgesia due to probable injection of lidocaine outside the glenoid cavity, and also due to different pain thresholds between patients. The success of IAL depends on the injection being made into the glenoid cavity and aspiration of hematoma is not a 100% reliable method to ensure that the needle is in the joint. The needle could be in one of the blood vessels around the shoulder joint. The lack of shoulder-muscle relaxation explains the cases that were difficult to reduce, but could also be due to inexperience of the surgeon.

Patients presented to hospital on average 4 hours after the onset of their dislocation; 54 (90%) patients attended hospital in the first 6 hours. The mean delay before reduction of AISD was 8 hours, higher than Fares et al of 2.4 hours [15]. Fares et al indicated that if the patient presented more than 5 hours after dislocation, reduction was only attempted under GA because of high risk of failure under IAL. There was no correlation between IAL failure and start time of treatment relative to the dislocation, although management delay did dictate the choice of reduction technique [10]. Our time to reduction was long (8 hours) due to the poverty of our patients, leading to a tendency to self-medicate and/or use of traditional medicine as a first line. Also, a lack of medical emergency transport and insufficient nursing staff available for emergency care for patients in our hospital explains this delay of care.

The cost of anesthesia care for AISD by IAL was US\$ 40

versus US\$ 100 after failure and conversion to GA. Miller et al in a prospective randomized study in 2002 reported costs of US\$ 1 and US\$ 98, respectively, under local and GA [16]. Our patients do not have health insurance care and the social security system in developing countries is poor, which explains the high cost of health care in our center. IAL is safe effective technique, has few side effects and provides the opportunity to drain a haemarthrosis.

The operator was a general surgeon in training, due to the limited number of orthopedic trauma surgeons, and anesthetic management was carried out by nurse anesthetists as there are few physician anesthesiologists. Regional analgesia and anesthesia techniques are growing in popularity; they are indicated for many trauma situations including reduction of shoulder dislocation [17,18]. Many hospitals in developing countries do not have access to equipment for safe general anesthesia, and recent evidence shows that up to 70% of the operating rooms operating in developing world do not have a pulse oximeter [19]. It is clear for patients undergoing shoulder dislocation reduction in well-equipped emergency department; regional anesthesia and IAL are better compared to general anesthesia [14,20]. We did not monitor our patients for long-term complications such as immediate and delayed chondrotoxicity or infection [21-23]. However, there remains a potential risk of infection, even if no cases have been reported yet [1,3].

CONCLUSION

AISD remains one of the most common osteoarticular injuries, in our study, most commonly as the result of a road traffic accident. The success rate of our reduction under IAL was 95%. Regional anesthesia techniques for treatment of painful musculoskeletal conditions are important and must be outlined in the medical literature. Our study shows that use of IAL for AISD is cost effective, well-tolerated and has a low complication rate, and may be particularly suitable for developing countries. Further trials comparing IAL to other analgesic methods should be undertaken to describe which protocol is better for reduction of shoulder dislocation in medical systems with scarce resources.

ACKNOWLEDGMENT

We would like to express our gratitude to Doctor Isabeau A Walker, Consultant Anaesthetist, Great Ormond Street Hospital for Children NHS Foundation Trust, London UK for English medical editing of this paper.

REFERENCES

- Ng VK, Hames H, Millard WM. Use of intra-articular lidocaine as analgesia in anterior shoulder dislocation: a review and meta-analysis of the literature. *Can J Rural Med.* 2009; 14: 145-149.
- Ballieul RJ, Jacobs TF, Herregods S, Van Sint Jan P, Wyler B, Vereecke H, et al. The peri-operative use of intra-articular local anesthetics: a review. *Acta Anaesthesiol Belg.* 2009; 60: 101-108.
- Wakai A, O'Sullivan R, McCabe A. Intra-articular lidocaine versus intravenous analgesia with or without sedation for manual reduction of acute anterior shoulder dislocation in adults. *Cochrane Database Syst Rev.* 2011; 4: CD004919.
- Fitch RW, Kuhn JE. Intra articular Lidocaine versus Intravenous Procedural Sedation with Narcotics and Benzodiazepines for Reduction of the Dislocated Shoulder: A Systematic Review. *Academic Emergency Medicine.* 2008; 15: 703-708.
- Hunter B, Wilbur L. Can intra-articular lidocaine supplant the need for procedural sedation for reduction of acute anterior shoulder dislocation? *Ann Emerg Med.* 2012; 59: 513-514.
- Lokossou T, Zoumenou E, Secka G, Bang'na FO, Le Polain de Waroux B, Veyckemans F, et al. Anesthesia in French-speaking Sub-Saharan Africa: an overview. *Acta Anaesthesiol Belg.* 2007; 58: 197-209.
- Walker IA, Wilson IH. Anaesthesia in developing countries--a risk for patients. *Lancet.* 2008; 371: 968-969.
- Owens BD, Dawson L, Burks R, Cameron KL. Incidence of shoulder dislocation in the United States military: demographic considerations from a high-risk population. *J Bone Joint Surg Am.* 2009; 91: 791-796.
- Zacchilli MA, Owens BD. Epidemiology of shoulder dislocations presenting to emergency departments in the United States. *J Bone Joint Surg Am.* 2010; 92: 542-549.
- Tamaoki MJ, Faloppa F, Wajnsztein A, Archetti Netto N, Matsumoto MH, Belloti JC. Effectiveness of intra-articular lidocaine injection for reduction of anterior shoulder dislocation: randomized clinical trial. *Sao Paulo Med J.* 2012; 130: 367-372.
- Beck S, Chilstrom M. Point-of-care ultrasound diagnosis and treatment of posterior shoulder dislocation. *Am J Emerg Med.* 2013; 31: 449.
- Dala-Ali B, Penna M, McConnell J, Vanhegan I, Cobiella C. Management of acute anterior shoulder dislocation. *Br J Sports Med.* 2012;.
- Liavaag S, Brox JI, Pripp AH, Enger M, Soldal LA, Svenningsen S. Immobilization in external rotation after primary shoulder dislocation did not reduce the risk of recurrence: a randomized controlled trial. *J Bone Joint Surg Am.* 2011; 93: 897-904.
- Blaivas M, Adhikari S, Lander L. A prospective comparison of procedural sedation and ultrasound-guided interscalene nerve block for shoulder reduction in the emergency department. *Acad Emerg Med.* 2011; 18: 922-927.
- Sayegh FE, Kenanidis EI, Papavasiliou KA, Potoupnis ME, Kirkos JM, Kapetanos GA. Reduction of acute anterior dislocations: a prospective randomized study comparing a new technique with the Hippocratic and Kocher methods. *J Bone Joint Surg Am.* 2009; 91: 2775-2782.
- Miller SL, Cleeman E, Auerbach J, Flatow EL. Comparison of intra-articular lidocaine and intravenous sedation for reduction of shoulder dislocations: a randomized, prospective study. *J Bone Joint Surg Am.* 2002; 84-84A: 2135-9.
- De Buck F, Devroe S, Missant C, Van de Velde M. Regional anesthesia outside the operating room: indications and techniques. *Curr Opin Anaesthesiol.* 2012; 25: 501-507.
- Beaudet V, Williams SR, Tétreault P, Perrault MA. Perioperative interscalene block versus intra-articular injection of local anesthetics for postoperative analgesia in shoulder surgery. *Reg Anesth Pain Med.* 2008; 33: 134-138.
- Kirby T. Pulse oximeters breathe life into surgery in poorer nations. *Lancet.* 2011; 377: 17-18.
- Cheok CY, Mohamad JA, Ahmad TS. Pain relief for reduction of acute anterior shoulder dislocations: a prospective randomized study comparing intravenous sedation with intra-articular lidocaine. *J Orthop Trauma.* 2011; 25: 5-10.

21. Piper SL, Kramer JD, Kim HT, Feeley BT. Effects of local anesthetics on articular cartilage. *Am J Sports Med.* 2011; 39: 2245-2253.
22. Dragoo JL, Braun HJ, Kim HJ, Phan HD, Golish SR. The in vitro chondrotoxicity of single-dose local anesthetics. *Am J Sports Med.* 2012; 40: 794-799.
23. Rahnama R, Wang M, Dang AC, Kim HT, Kuo AC. Cytotoxicity of local anesthetics on human mesenchymal stem cells. *J Bone Joint Surg Am.* 2013; 95: 132-137.

Cite this article

Sama HD, Ouro Bang'na Maman AF, Flavien Kabore RA, Belo M (2014) Observational Study of Intra-Articular Lidocaine for Management of Shoulder-Dislocation at Sylvanus Olympio University Teaching Hospital, Togo. *Int J Clin Anesthesiol* 2(2): 1028.