

## Case Report

# Severe Hypotension Associated with Insertion of an Alexis® Wound Protector/Retractor during Lower Abdominal Surgery in a Child: A Case Report

Rika Nakayama, Takahiro Mihara\*, Yoshiko Mizuno, Yoshihisa Miyamoto, Kouji Ka

Department of Anesthesiology, Kanagawa Children's Medical Center, Japan

## \*Corresponding author

Takahiro Mihara, Department of Anesthesiology, Kanagawa Children's Medical Center, Mutsukawa 2-138-4, Minami-ku, Yokohama, Japan, Tel: +81-45-711-2351; Fax: +81-45-721-3324; Email: miharaxxtotoro@yahoo.co.jp

Submitted: 31 January 2014

Accepted: 11 February 2014

Published: 06 June 2014

ISSN: 2333-6641

Copyright

© 2014 Mihara et al.

OPEN ACCESS

## Keywords

- Intraoperative hypotension
- Wound retractor
- Children
- Pediatric anesthesia

## Abstract

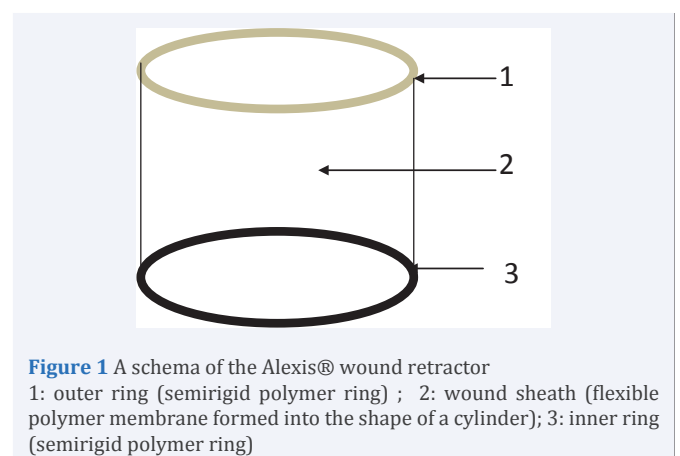
We present a case of severe hypotension associated with insertion of an Alexis® wound protector/retractor during lower abdominal surgery in a child. A 3-year old female patient underwent ureteroneocystostomy for vesicoureteral reflux under general anesthesia. After skin incision in the lower abdomen, the retractor was placed in position through the incision in the lower abdominal wall, with the inner ring inside the abdomen. Following insertion of the retractor, the patient's blood pressure dropped from 95/40 mmHg to 45/20 mmHg. Physical examination and transthoracic echocardiography did not indicate any signs of anaphylactic reaction, cardiac dysfunction, or pulmonary embolism, and after removal of the wound retractor, the patient's blood pressure quickly recovered to the baseline level. Because these wound retractors may cause severe hypotension, it is important to pay particular attention to blood pressure when they are used in small children undergoing abdominal surgery.

## INTRODUCTION

In recent years, several modifications for less invasive and more cosmetic surgical procedures have been advocated. The Alexis® wound protector/retractor (Applied Medical, Rancho, Santa Margarita, CA) (Figure 1) is one of the tools made for minimally invasive surgery. This type of wound retractor allows for maximum exposure of the surgical field with a minimum incision size, and is increasingly being used in children. Although few complications related to these wound retractors have been reported, we experienced severe hypotension after insertion of one during lower abdominal surgery in a pediatric patient. We report the case and discuss possible mechanisms.

## CASE PRESENTATION

An otherwise healthy 3-year old, 15.7kg female patient underwent ureteroneocystostomy for vesicoureteral reflux under general anesthesia with standard non-invasive monitoring (electrocardiogram, blood pressure, precordial stethoscope, and pulse oximetry). Anesthesia was induced with sevoflurane and nitrous oxide in oxygen, and maintained with age-adjusted 1-2



**Figure 1** A schema of the Alexis® wound retractor  
1: outer ring (semirigid polymer ring) ; 2: wound sheath (flexible polymer membrane formed into the shape of a cylinder); 3: inner ring (semirigid polymer ring)

MAC of sevoflurane in air and oxygen. The airway was secured with a 5.5 mm cuffless endotracheal tube. Caudal epidural analgesia was administered as 15 mL of a 1:2 mixture of 0.75% ropivacaine and 1% lidocaine.

For the operation, a 3 cm linear incision was made in the lower abdomen and a size S wound retractor, suitable for 2.5–6 cm incision, was inserted through the incision. Immediately after insertion of the wound retractor, the patient's blood pressure dropped from 95/40 mmHg to 45/20 mmHg. Despite rapid infusion of crystalloid (10 mL/kg) and administration of an inotropic drug (0.1 mg/kg of ephedrine), the severe hypotension persisted. There were no signs of anaphylactic reaction, such as wheezing, flushing, or generalized hives. Transthoracic echocardiography did not show any sign of pulmonary embolism or cardiac dysfunction.

We suspected the wound retractor as a cause of hypotension. As soon as the wound retractor was removed, the patient's blood pressure recovered to baseline (85/40 mmHg). A smaller size wound retractor (size XS; suitable for 2–4 cm incision) was inserted, but hypotension recurred (60/25 mmHg). We removed the second retractor and chose another type of abdominal retractor without an inner ring. Thereafter, no significant hypotension occurred, and the surgery was completed uneventfully.

## DISCUSSION

The clinical course of this patient highlighted two important clinical issues. First, severe hypotension may occur due to insertion of a wound retractor. Second, severe hypotension caused by insertion of a wound retractor can be treated by removing the retractor. Complications associated with wound retractors are relatively rare. Those that have been reported include bleeding [1,2], wound site infection [2-4], or allergy to polyurethane [5]. However, to our knowledge, there are no other case reports about hypotension. In this case, the patient developed severe hypotension immediately after insertion of the wound retractor. Pulmonary embolus and anaphylaxis are possible causes of such a situation, but in this case, physical examination and transthoracic echocardiography indicated no signs of these complications. Finally, we removed the wound retractor and the patient's blood pressure immediately recovered to the baseline, which suggested that insertion of the wound retractor had caused the severe hypotension.

In general, intraoperative hypotension is attributed to four factors: 1) decreased preload, 2) decreased systemic vascular resistance, 3) decreased cardiac contraction, and 4) obstructive shock [6,7]. Because we did not use invasive hemodynamic monitoring, the precise mechanism of the hypotension in this case remains unclear. As no signs of bleeding, anaphylaxis, cardiac failure, or pulmonary embolism were observed, we speculate that the inner ring and sheath of the wound retractor compressed neighboring veins including the common iliac, renal, and inferior mesenteric veins [8], and thus cardiac preload was reduced. However, obstruction of local venous return alone does not seem enough to cause severe intractable hypotension, because the lower limbs and lower abdominal organs account for only about 20% of total cardiac output [8]. The small sized wound retractor

used in the present case has a diameter of 9.3 cm and width of 1.2 cm, and this is relatively large for the small abdominal cavity of a child. Therefore, the wound retractor might also have indirectly compressed the greater veins, i.e., the inferior vena cava, portal vein, or hepatic vein, causing severe hypotension.

The Alexis® wound protector/retractor is widely used for minimally invasive surgery and its safety has been established in adults. However, we cannot verify its safety for children because of the current lack of clinical experiences. Thus, when this type of wound retractor is used for small children, careful attention should be paid to the occurrence of hypotension, and removal of the wound retractor should be considered when hypotension occurs.

## CONCLUSION

We presented a case of severe hypotension associated with insertion of a wound retractor during lower abdominal surgery in a child. Our experience indicated that insertion of a wound retractor can cause hypotension in children undergoing abdominal surgery, and that hypotension caused by insertion of a wound retractor can be rapidly restored to baseline by removing the retractor.

## REFERENCES

1. Chung SD, Huang CY, Wang SM, Hung SF, Tsai YC, Chueh SC, et al. Laparoendoscopic single-site totally extraperitoneal adult inguinal hernia repair: initial 100 patients. *Surg Endosc*. 2011; 25: 3579-3583.
2. Seo IY, Lee JW, Rim JS. Laparoendoscopic single-site radical nephrectomy: a comparison with conventional laparoscopy. *J Endourol*. 2011; 25: 465-469.
3. Pendlimari R, Holubar SD, Pattan-Arun J, Larson DW, Dozois EJ, Pemberton JH, et al. Hand-assisted laparoscopic colon and rectal cancer surgery: feasibility, short-term, and oncological outcomes. *Surgery*. 2010; 148: 378-385.
4. Cheng KP, Roslani AC, Sehha N, Kueh JH, Law CW, Chong HY, et al. ALEXIS O-Ring wound retractor vs conventional wound protection for the prevention of surgical site infections in colorectal resections(1). *Colorectal Dis*. 2012; 14: e346-351.
5. Horiuchi T, Tanishima H, Tamagawa K, Sakaguchi S, Shono Y, Tsubakihara H, et al. A wound retractor/protector can prevent infection by keeping tissue moist and preventing tissue damage at incision sites. *Helix Review Series: Infectious Diseases*. 2007; 3: 17-23.
6. Tintinalli J, Stapczynski J, Ma OJ, Cline D, Cydulka R, Meckler G. *Tintinalli's Emergency Medicine: A Comprehensive Study Guide*. 7<sup>th</sup> edn. New York: McGraw-Hill Professional. 2010.
7. Bijker JB, van Klei WA, Kappen TH, van Wolfswinkel L, Moons KG, Kalkman CJ. Incidence of intraoperative hypotension as a function of the chosen definition: literature definitions applied to a retrospective cohort using automated data collection. *Anesthesiology*. 2007; 107: 213-220.
8. John T Hansen, Bruce M Koeppen. *Netter's Atlas of human physiology*, Teterboro. NJ: Saunders. 2002.

### Cite this article

Nakayama R, Mihara T, Mizuno Y, Miyamoto Y, Ka K (2014) Severe Hypotension Associated with Insertion of an Alexis® Wound Protector/Retractor during Lower Abdominal Surgery in a Child: A Case Report. *Int J Clin Anesthesiol* 2(2): 1031.

