

## Case Report

# Clinical Management of Massive Hemolysis in a Neonate during Cardiopulmonary Bypass

Craig McRobb<sup>1</sup>, Glenn R Merritt<sup>2</sup>, Mike Krieves<sup>2</sup>, Sandeep Jhaji<sup>3</sup>, Cindy Barrett<sup>4</sup>, Kelley E. Capocelli<sup>5</sup>, James Jagers<sup>6</sup> and Richard J Ing<sup>2\*</sup>

<sup>1</sup>Perfusion Services, Children's Hospital Colorado, Denver Colorado

<sup>2</sup>Department of Anesthesiology, Children's Hospital Colorado, Denver Colorado

<sup>3</sup>Department of Surgery, Children's Hospital Colorado, Denver Colorado

<sup>4</sup>Department of Cardiology and Critical Care, Children's Hospital Colorado, Denver Colorado

<sup>5</sup>Department of Pathology, Children's Hospital Colorado, Denver Colorado

<sup>6</sup>Department of Cardiothoracic Surgery, Children's Hospital Colorado, Denver Colorado

## INTRODUCTION

Massive hemolysis during cardiopulmonary bypass (CPB) for repair of congenital cardiac defects is rare and life threatening. Potential etiologies of intra operative hemolysis during cardiac surgery include hemolytic transfusion reactions, CPB circuit and suction-related mechanical red blood cell (RBC) trauma, the generation of oxygen (O<sub>2</sub>) free radicals, activation of complement, inherited hemoglobinopathies, and complications involving the infusion of preparatory fluids and medications during CPB [1].

A hemolytic transfusion reaction may be considered when urine shows a red discoloration; however, it is often dismissed as mild hemolysis from mechanical trauma on CPB that seldom leads to significant morbidity or mortality. Massive hemolysis during CPB requires the participation of the entire cardiac perioperative team to ensure excellent clinical outcomes.

We report on massive hemolysis in a neonate during CPB while undergoing repair of complex congenital heart disease.

## CASE REPORT

A one month old, corrected gestational age of 39 weeks, 2.8 kg male with Tetralogy of Fallot was scheduled for complete surgical repair on CPB. His past medical history included intrauterine growth retardation associated with maternal eclampsia and hemolysis, elevated liver enzymes and low platelets (HELLP) syndrome. His blood was type A positive. At the time of surgery his mother's blood type was not recorded in the charts this child had been delivered at an outside institution.

Upon arrival to the operating room, standard monitors were placed including cerebral near infrared spectroscopy (NIRS), pulse oximetry, and non-invasive blood pressure. Initial blood

### \*Corresponding author

Richard J Ing, Department of Anesthesiology, Children's Hospital Colorado, 13123 East 16th Avenue, Box B090, Aurora, CO 80045, Denver Colorado, Tel: 720-777-4589; Fax: 720-777-7266; Email: richard.ing@childrenscolorado.org

Submitted: 11 December 2015

Accepted: 19 January 2016

Published: 21 January 2016

ISSN: 2333-6641

Copyright

© 2016 Ing et al.

OPEN ACCESS

### Keywords

- Cardiopulmonary bypass
- Hemolysis
- Cardiac surgery

pressure was 70/40 mmHg, heart rate of 125, and a peripheral O<sub>2</sub> saturation of 82%. An inhalational sevoflurane anesthetic induction, in 70 % air:oxygen was initiated. Following loss of consciousness, the patient's O<sub>2</sub> saturation dropped to 30% despite adequate ventilation and normal hemodynamic parameters. The low O<sub>2</sub> saturation returned to 60-70% with 3 doses of 1 mcg/kg of phenylephrine, 20 mL/kg of I.V. plasmalyte-A and 10 mL of 5% albumin. The blood pressure remained stable at 75/40 mm Hg with a heart rate of 120. Subsequently, nasal intubation was successful with a 3 mm I.D. uncuffed endotracheal tube placed to 10 cm at the right nare. Despite pharmacological therapy, oxygen saturations remained in the high 60%-70% range and following administration of 450 IU/kg of bovine heparin the patient was placed on CPB.

The CPB circuit consisted of a neonatal hollow fiber oxygenator (Maquet Cardiovascular, Wayne, N.J.), a 3/16" arterial line and 1/4" venous line with SMART<sub>x</sub> (Sorin Group USA, Arvada, CO) coated tubing, an arterial roller pump, and a pediatric ultrafiltration device (Medivators Inc., Minneapolis, MN). Vacuum-assisted venous drainage (VAVD) was used for venous return. CPB monitoring consisted of continuous inline mixed venous saturation (SVO<sub>2</sub>) and arterial blood gas (ABG) monitoring (CDI 500, Terumo Cardiovascular) along with arterial, cardioplegia and VAVD pressures. Temperature monitoring included arterial and venous blood, cardioplegia, and patient rectal and nasopharyngeal. ABG testing was accomplished on CPB using the i-STAT® point-of-care system (Abbott Point of Care Inc., Princeton, NJ). The CPB circuit was primed with 221 mLs of A<sup>+</sup> fresh frozen plasma (FFP) and 256 mLs of A<sup>+</sup> packed red blood cells (pRBC) which were less than 3 days old. Appropriate doses of mannitol, sodium bicarbonate, heparin, and calcium

chloride were added to the circuit prime. The occlusion of the arterial roller pump and the roller pumps used for cardioplegia, venting, and suction were all checked prior to the initiation of CPB and found to be within normal limits. Standard protocol is to “wash” the blood prime by removing 1000mLs of ultra filtrate and replacing it with a balanced electrolyte solution. This is done to remove excessive amounts of glucose, citrate, potassium, and lactic acid from the prime that may be present in banked blood. Prior to the emergent institution of CPB, only approximately 100 mLs of ultra filtrate had been removed from the CPB prime. The ultra filtrate, which is normally clear, had a reddish color. This observation was not totally out of the ordinary at the onset of ultra filtration and further ultra filtration on CPB was planned.

On CPB the patient was cooled to 34 degrees Celsius. The first i-STAT ABG on CPB revealed that the baseline hemoglobin (Hb) and hematocrit (Hct) values had dropped from the initial intraoperative values of 11.6 g/dL and 34% to values of 6.1g/dL and 18%, respectively. The serum potassium (K<sup>+</sup>) value was 8.6mmol/L. In the presence of an otherwise normal clinical presentation (blood pressure, SVO<sub>2</sub>, NIRS), a point of care lab value or sampling error was suspected. Repeat testing revealed an Hb of 4.1g/dL and Hct of 12%. The K<sup>+</sup> was 9.0 mmol/L. Oxygenator water to blood leak was immediately considered, however, felt to be extremely unlikely as the initial CPB pH was 7.4 and no increase in venous reservoir volume was observed.

Suspecting a hemolytic transfusion reaction or hyperkalemia from the donated pRBC unit, the Blood Bank was notified and an immune hemolytic transfusion work-up was initiated. Blood samples from the patient were compared with pre-transfusion patient samples. During the time between the low Hb reading and the second set of tests, a second unit of O<sup>+</sup>pRBCs was transfused on CPB. Both blood bags were returned to the Blood Bank for immediate analysis, which included K<sup>+</sup> measurements and analysis for evidence of hemolysis.

The initial urine sample from the urinary catheter was clear, and no new urine had been produced at this time to evaluate for hematuria. Dilutional ultra filtration on CPB with saline was performed to decrease the K<sup>+</sup>. Ten mg/kg of hydrocortisone was administered for treatment of a possible immune transfusion reaction. The anesthesia team instituted a treatment regimen for hyperkalemia with sodium bicarbonate, insulin and glucose. Additionally, inhaled and intravenous beta agonist therapy was initiated after surgical repair during rewarming. Mechanical CPB-related causes for hemolysis were evaluated and no evidence of a CPB pump or oxygenator malfunction was identified.

During weaning from CPB, decreased myocardial contractility was identified. A loading dose of milrinone 50 mcg/ kg and an infusion of 0.5 mcg/kg/min, epinephrine 0.05 mcg/kg/ min, dopamine 5 mcg/kg/ min, and vasopressin 0.0003 (units) were initiated and the patient was successfully weaned from CPB.

In the interim, the patient received 1 unit of platelets, and 2 units of cryoprecipitate. The sternum was closed, the patient remained intubated and sedated and was transferred to the cardiac intensive care unit (CICU) with the last measured intra operative K<sup>+</sup> of 6.9mmol/L. The EKG showed evidence of a bundle branch block and peaked T waves. The laboratory hemolytic

transfusion workup obtained on CPB and after being in the CICU for 24hrs is shown in (Table 1). A pre-transfusion sample of the patient’s blood was re-examined and had a plasma free Hb (PfHb) value of 16 mg/dL.

The patient arrived in the CICU with a blood pressure of 112/58 mmHg on vasoactive drips of dopamine, epinephrine, vasopressin and milrinone. Vasopressin was quickly weaned off due to hypertension. The central venous pressure ranged from 10 to 15 mmHg. Initially there was difficulty with ventilation and over the next hour, several large bloody clots were suctioned from his endotracheal tube with subsequent improvement in his ventilatory parameters.

Notably, the patient’s urine was dark red and scant in volume. His immediate postoperative labs revealed serum K<sup>+</sup> of 4.4 mmol/L, PfHb of 2900 mg/dL, and a total bilirubin of 14.2 mg/dL. The K<sup>+</sup> and Hct were monitored every 30 minutes for the first 2 hours after arrival and remained in the 4.5- 5 mmol/L range and 35 % respectively.

The initial goal was to maintain renal perfusion and stable hemodynamics. Full maintenance fluids (100 mL/kg/day) and a dose of furosemide were administered 6 hours after the initial dose in the operating room. The urine was alkalinized by administering trimethamine (THAM) (due to elevated sodium). Due to the concern for an intrinsic hemolytic reaction given his pre-transfusion elevated PfHb, serum cortisol was measured and found to be low at 0.8 mcg/dL. The patient therefore received hydrocortisone replacement at 1 microgram/kg every six hours.

The patient was evaluated for plasmapheresis. Although the necessary equipment and personnel were available, the patient was only 2.8 kg, and too small for placement of a plasmapheresis catheter. Therefore a double manual exchange blood transfusion was initiated. The patient received 15mL aliquots of blood exchange over 2.5 hours with little change in his hemodynamics. His post-exchange PfHb was 900 mg/dL, down from 6600 mg/dL.

As no absolute cause of this massive hemolysis was identified despite extensive testing, patient records were obtained from the hospital where the child had been born. These revealed a peak total bilirubin level of 10 mg/dL shortly after birth - a value considered physiologically normal for a newborn. A blood sample from the mother was obtained to test for ABO and Rh antigen incompatibility. Both the patient and mother were A<sup>+</sup> which ruled out a question of persistent hemolytic disease of the newborn. The mother was tested for antibodies five weeks post-partum and found to be negative.

**Table 1:** Laboratory hemolytic transfusion workup.

	Normal values	Patient on CPB	Patient in CICU first 24 hrs
Plasma free Hb (mg/dL)	≤3	6600	2200
Urine myoglobin (mcg/mL)	≤0.025	3.01	3.01
Plasma total bilirubin (mg/dL)	0.2-1.2	22.6	6.3
Plasma LDH (U/L)	480-1120	14314	5480

The investigation then turned to the donor of the A<sup>+</sup> pRBC unit used to prime the CPB circuit. A peripheral smear showed the presence of spherocytes; all other red cell indices were within normal limits. A bilirubin profile, LDH, reticulocyte count, and Pfhb were all unremarkable. Given the presence of spherocytes on the peripheral smear, an RBC osmotic fragility test was performed which was unremarkable. In addition, questioning of the donor revealed that she occasionally noticed dark urine with her first void, so a sample was also obtained and ruled out paroxysmal nocturnal hemoglobinuria as a possible cause of hemolysis.

## DISCUSSION

Hemolysis occurs when the RBC membrane undergoes premature breakdown and Hb is released into the plasma, becoming Pfhb. Subsequent organ injury is directly proportional to the amount of Pfhb. Pfhb leads to decreased nitric oxide synthesis, which subsequently leads to increased intravascular thrombosis and vasoconstriction [1]. This process is capable to causing multiple organ injury, including heart, gastrointestinal, pulmonary and urogenital [1]. Unfortunately no practical clinical algorithms could be found for the management of extreme hemolysis during CPB.

Vercaemst reports that higher degrees of hemolysis on CPB should be expected in young children, but massive hemolysis is rarely observed even in the most premature infant undergoing cardiac repair [2]. When hemolysis occurs in a newborn associated with CPB, a wide differential diagnosis should be considered. Possible causes include RBC membrane abnormalities, hemoglobinopathies, iso-immunization, undiagnosed RBC enzyme abnormalities as well as acquired conditions such as sepsis or drug interaction with the RBC's [2].

Acute hemolytic transfusion reactions (HTRs) are defined by destruction of either transfused RBCs or the recipient's RBCs. In an anesthetized patient, the only signs of a hemolytic transfusion reaction may be hypotension, hemoglobinuria, and a systemic hemorrhagic state [1]. One type of HTR are immune mediated, which include the interaction of antibodies in the recipient's plasma with antigens on the donor's RBCs (major incompatibility) or antibodies in the donor plasma with antigens on the recipients RBCs (minor incompatibility). It is also possible to have a rare reaction of one donor's plasma antibodies interacting with a second donor's RBC antigens [2]. Most severe acute HTRs are due to ABO incompatibility; however, HTRs can also occur from irregular alloantibodies induced by former blood transfusion or pregnancy directed towards non-ABO antigens on RBCs [2].

Although Immune mediated HTRs are the most common type of HTR there are many non-immune mediated causes of pseudo-hemolytic transfusion reactions, as noted in the Table 2. These should be investigated when an immune etiology cannot be elucidated. Pseudo-hemolytic transfusion reactions can have many of the same consequences as immune mediated HTRs, and should be considered in the differential diagnosis of a suspected transfusion reaction.

The possibility that the patient had a congenital hemolytic anemia was considered; however, a peripheral smear was unremarkable, thus ruling out the possibility of sickle cell anemia

or hereditary spherocytosis. A test for glucose six phosphate dehydrogenase (G6PD) deficiency and paroxysmal nocturnal hemoglobinuria was also negative. The Blood Bank work-up included consideration of a hemolytic process in the donor of the RBCs that hemolyzed in the CPB circuit. Hemolytic laboratory tests were unremarkable.

In addition, thermal, osmotic, or mechanical mechanisms of cell injury should also be investigated [1]. Extremes of temperature can be associated with a pseudo-hemolytic transfusion reaction. In this case neither the blood prime nor the patient blood during CPB was exposed to temperature extremes. Hemolysis due to a water-to-blood leak in the oxygenator during CPB can occur, but is extremely rare [3]. Heat exchangers are pre-tested for leaks by the manufacturers based on FDA recommendations and product failures only occur on <0.001 to 0.1% of devices and defective devices are removed from the manufacturing process [3].

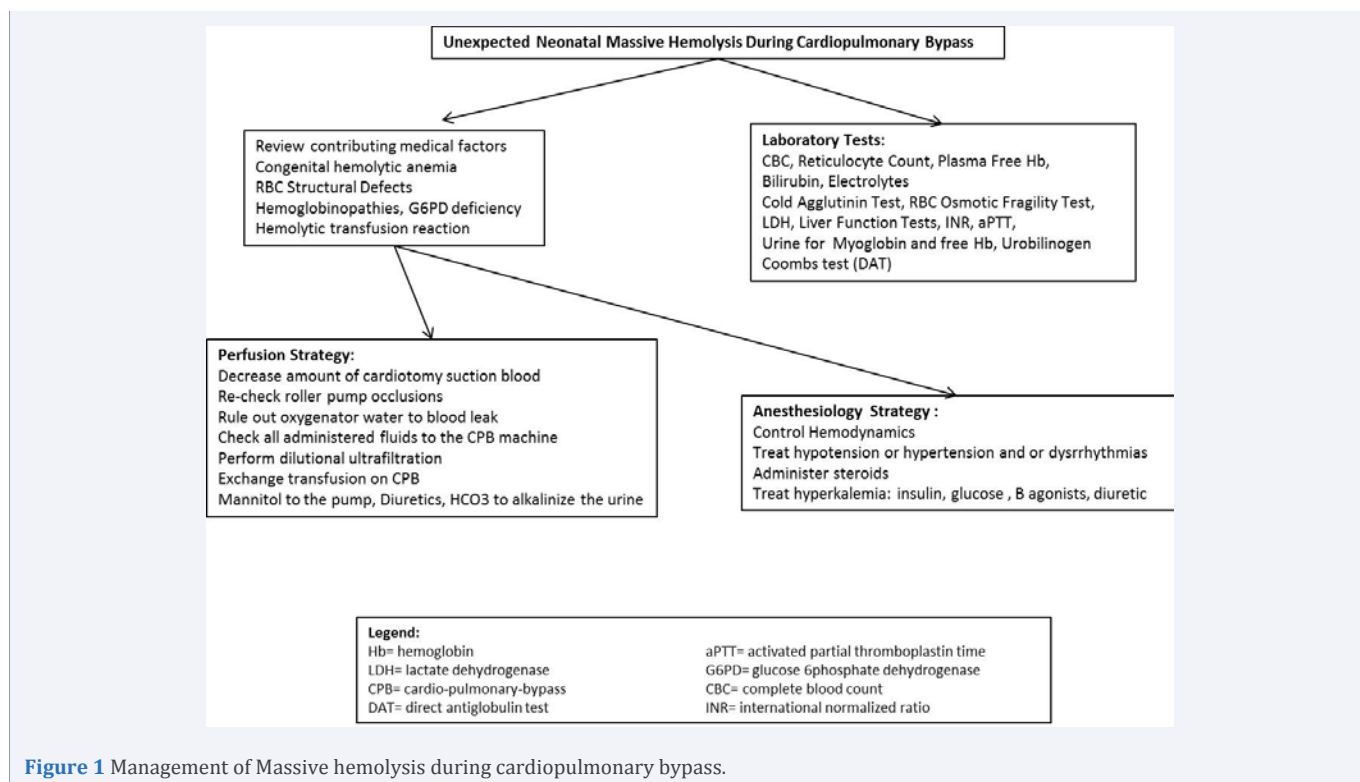
Concern about the possibility of osmotic injury having resulted in red cell destruction led to testing of all of the fluids added to the CPB prime. These fluids were found to have normal osmolality. Entrainment of the cardioplegic solution into the CPB prime was considered; however, this would only explain the high potassium levels and not the hemolysis.

Several mechanisms of mechanical trauma were investigated. The bypass circuit itself can be a cause of mechanical trauma to RBCs, resulting in hemolysis. This has been minimized over the years with the use of different tubing materials, optimizing of tubing size and length, and the use of centrifugal over roller pumps. Special care must be paid throughout the utilization of CPB for any pump occlusion issues or excessive pump sucker return, which could in turn cause significant hemolysis<sup>2</sup>. Minor mechanical trauma may also occur commonly during CPB but the Pfhb in this setting is usually rapidly cleared by the kidneys and seen as red discolored urine. Ricci et al retrospectively reviewed 22 neonates and infants patients with CPB. This showed hemolysis occurred with average fHb ranging 76 (65-109) at CPB weaning and returning to 35 on POD 2 (P<0.0001) [4]. As noted previously, neither of these conditions were present in this case. As comparison, our patient maxed at 6600 fHb during CPB, extremely high compared to report in review.

Since efforts during CPB to decrease the patient's K<sup>+</sup> and increase his Hct were successful, there is no evidence that the hemolysis was associated with an ongoing hemolytic event (such as one that would be caused by an over occluded roller pump).

Since there was some visual evidence of hemolysis in the blood prime (reddish ultrafiltrate) prior to initiation of CPB, transfusion of hemolyzed RBCs from the CPB prime to the patient was considered a possibility. The roller pump occlusion was rechecked post-CPB (including by the heart lung machine manufacturer), and found to be within normal limits. Roller pumps used on modern heart-lung machine consoles are very sensitive to over-occlusion and had this been the etiology, the CPB machine would likely have alarmed, alerting the operator to the problem. The oxygenator was also tested by the manufacturer and no defects were reported.

It is possible to speculate, and perhaps advise, that visual evidence of hemolysis in the CPB prime should result in further



**Figure 1** Management of Massive hemolysis during cardiopulmonary bypass.

work-up prior to initiation of CPB. In this case, however, rapid initiation of CPB was felt to be necessary. Unless addressed promptly, serious consequences of massive hemolysis can occur, such as multiple organ failure by microvascular vasoconstriction and platelet thrombi formation [5]. Appropriate therapy aimed at removing hemolyzed blood and protecting organ function from cytotoxic effects of heme is of utmost importance [6,7]. This case highlights the successful clinical management of an extreme form of neonatal, CPB associated massive hemolysis. The slow insidious nature of this hemolysis progression resulted in post operative exchange transfusion. Due to the rarity of this clinical problem, it is important to remember that exchange transfusion on CPB should be considered early in management of massive hemolysis. Despite an extensive work up and differential diagnosis review no cause for hemolysis could be found. However we believe the experience and literature review in this clinical report may be helpful to other medical teams caring for children with this similar medical emergency.

## CONCLUSION

Currently no algorithm exists in the literature for evaluation of massive hemolysis associated with CPB [7]. We have proposed an algorithm that utilizes investigation of CPB hemolysis. Laboratory work-up should be sent looking for findings of hemolysis (including not limited to plasma free Hb, bilirubin, urine for myoglobin, free Hb and urobilinogen). Review of medical factors should be performed for any pertinent medical history, such as hemoglobinopathies. Cardiac perioperative strategy includes

co-management by perfusion and anesthesiology (Figure 1). Perfusion strategy includes ensuring hemolysis isn't due to the CPB circuit and that it is functioning properly, as anesthesiology manage patient hemodynamics and electrolyte abnormalities.

## REFERENCES

1. Beaugard P, Blajchman MA. Hemolytic and pseudo-hemolytic transfusion reactions: an overview of the hemolytic transfusion reactions and the clinical conditions that mimic them. *Transfus Med Rev.* 1994; 8: 184-199.
2. Strobel E. Hemolytic Transfusion Reactions. *Transfus Med Hemother.* 2008; 35: 346-353.
3. Hamilton C, Stein J, Seidler R, Kind R, Beck K, Tosok J, et al. Testing of heat exchangers in membrane oxygenators using air pressure. *Perfusion.* 2006; 21: 105-107.
4. Ricci Z, Pezzella C, Romagnoli S, Iodice F, Haiberger R, Carotti A, et al. High levels of free haemoglobin in neonates and infants undergoing surgery on cardiopulmonary bypass. *Interact Cardiovasc Thorac Surg.* 2014; 19: 183-187.
5. Carcillo JA. Multiple organ system extracorporeal support in critically ill children. *Pediatr Clin North Am.* 2008; 55: 617-646.
6. Qian Q, Nath KA, Wu Y, Daoud TM, Sethi S. Hemolysis and acute kidney failure. *Am J Kidney Dis.* 2010; 56: 780-784.
7. Vercaemst L. Hemolysis in cardiac surgery patients undergoing cardiopulmonary bypass: a review in search of a treatment algorithm. *J Extra Corpor Technol.* 2008; 40: 257-67.

### Cite this article

McRobb C, Merritt GR, Krieves M, Jhajj S, Barrett C, et al. (2016) Clinical Management of Massive Hemolysis in a Neonate during Cardiopulmonary Bypass. *Int J Clin Anesthesiol* 4(1): 1049.