

Case Report

Anesthetic Management for Stereotactic Neurosurgical Treatment of Patients with Pantothenate Kinase – Associated Neurodegeneration (PKAN) – An Experience of Two Cases with Dexmedetomidine

Rohini M. Surve*, Dwarakanath Srinivas, Ganne S. Umamaheswara Rao, Sonia Bansal, Kadarapura N. Gopalkrishna, and Venkataramaiah Sudhir

Department of Neuroanesthesiology and Neuro Critical Care, National Institute of Mental Health and Neurosciences, India

***Corresponding author**

Sudhir Venkataramaiah, Department of Neuroanesthesiology, National Institute of Mental Health and Neurosciences, 3rd Floor, Faculty block, National Institute of Mental Health and Neurosciences, Bangalore, Karnataka, 560029, India, Tel: 919900793108; Fax: 910826564830; Email: vsudhir77@gmail.com

Submitted: 07 October 2017

Accepted: 13 November 2017

Published: 16 November 2017

ISSN: 2333-6641

Copyright

© 2017 Surve et al.

OPEN ACCESS**Keywords**

- Pantothenate kinase - associated neurodegeneration (PKAN)
- Dexmedetomidine
- Deep brain stimulation
- Anesthesia

Abstract

Pantothenate Kinase – associated neurodegeneration (PKAN) is a rare autosomal recessive disorder. PKAN presents with severe incapacitating dystonias, rigidity and cognitive impairment usually in early childhood. The initial treatment of patients suffering from PKAN constitutes medical line of management, but for those patients who are refractory to medical management surgical treatment is an option. Perioperative anaesthetic management is a challenge in view of generalized dystonias, restricted airway access due to head frame, need for an awake and co-operative patient, and to provide ideal conditions for intraoperative microelectrode recordings (MERs) under anesthesia. All these factors demand an appropriate anesthetic technique. It further becomes challenging if the surgical procedure is performed on children, since they require general anaesthesia which in turn can interfere with the interpretation of MERs and clinical assessment. We report two cases of PKAN who underwent surgical treatment using dexmedetomidine (alpha agonist) as the principal anesthetic agent.

INTRODUCTION

Pantothenate Kinase - associated neurodegeneration is a rare autosomal recessive disorder presenting with severe incapacitating dystonias, rigidity and cognitive impairment, which by and large manifest in the early childhood. The diagnosis is usually based on the clinical presentation, magnetic resonance imaging (MRI) and genotyping [1,2]. Medically refractive dystonias can be surgically treated by performing bilateral stereotactic thalamotomy, pallidotomy or deep brain stimulation (DBS) [3-9]. Anaesthetic management necessitates rendering the patient in a balanced state of sedation wherein the patient needs to remain immobile during the critical steps of the surgery and at the same time should be able to quickly return to an awake state when functional assessment needs to be carried out. We report two cases in which the alpha agonist Dexmedetomidine was used to produce rapidly reversible sedated state with immobility while allowing functional analysis during stereotactic surgical procedure for DBS.

CASE REPORTS**Case 1**

A 17-yr-old boy weighing 25 kg presented with a history of blepharospasm for 2 years, left-sided torticollis and opisthotonus for 6 months and was bed-bound in the past 3 months. MRI of the brain showed bilateral symmetrical, hyper intense signals with surrounding hypo intensities in the region of globus pallidus on T2 weighted images, consistent with the “eye of the tiger” sign. His dystonia remained refractory to medical management with trihexyphenidyl, tetrabenazine, carbamazepine, nitrazepam, clonazepam, syndopa (a combination of levodopa and carbidopa) and baclofen. Therefore, a pallidotomy was planned.

Surgical procedure: Stereotactic Lekshell head frame was applied under local anaesthetic in filtration at the pin site and MRI was completed under dexmedetomidine sedation with intravenous (IV) bolus of 1µg/kg over 15 min followed by 0.5µg/

kg/h achieving Ramsay sedation score (RSS) of 5. Pallidotomy was performed under conscious sedation with the administration of a 25-µg bolus of IV fentanyl followed by dexmedetomidine infusion at 0.7µg/kg/h until the burr holes were placed, and 0.3-0.5µg/kg/h thereafter for maintenance of the sedated state. Dexmedetomidine infusion was stopped five minutes before the microelectrode recordings (MERS) and subsequent functional assessment. The patient was conscious, obeying verbal commands and cooperative with an RSS of 2 during MERS and subsequent assessment. The entire procedure lasted for 45 minutes. The patient's dystonia decreased significantly after the procedure. His vital parameters remained stable throughout the procedure (Figure 1). The patient's clinical condition improved following the procedure for a brief period. However, at 6 months follow up after surgery most of his symptoms had recurred and he was being considered for redo stereotactic surgery.

The anesthetic management of this patient for preoperative MRI has been previously reported by other authors [10].

Case 2

A 5½-yr-old female child weighing 15 kilograms presented in acute dystonic crisis. She had abnormal movements initially in both the upper limbs, which progressed to involve lower limbs, trunk, head and neck over a period of 15 days. She also had difficulty in talking and breathing. On examination, the patient had generalized dystonia's with intermittent opisthotonus and retrocollis. Her muscle tone was tough to evaluate because of pronounced rigidity. Predominant mouth breathing was present. The diagnosis was confirmed by an MRI of the brain that showed the "eye of the tiger" sign (Figure 2a). Medical therapy with central anticholinergics, anticonvulsants and benzodiazepines failed therefore DBS was planned.

Anesthetic management in the MRI suite was similar to that in case 1. Considering her age and the presence of severe dystonias, general anesthesia (GA) was planned for the surgery. Anesthesia was induced with IV fentanyl 2µg/kg and propofol 2 mg/kg. After confirming mask ventilation, intravenous Succinylcholine 20mg was administered and trachea was intubated with a 5-mm uncuffed endotracheal tube (ETT) and mechanical ventilation was initiated. Non-invasive blood pressure (NIBP), pulse oximetry (SPO2), electrocardiography (ECG), urine output, skin temperature and spectral entropy for depth of anaesthesia were monitored. Anesthetic state was maintained using sevoflurane 1% in O₂ and Air (FiO₂ 0.5), and dexmedetomidine and fentanyl infusion at 0.5µg/kg/h. The patients' respiration was supported with pressure support mode of ventilation and muscle relaxants were avoided throughout the procedure. At the time of electrophysiological monitoring sevoflurane was stopped and dexmedetomidine infusion was titrated to 0.1-0.2µg/kg/h. The spectral entropy values were maintained at 20-30 which increased to 90-100 at the time of electrophysiological recordings following decrease in the dexmedetomidine infusion rate and cessation of sevoflurane. The variations in the spectral entropy during deep sedation and during electro physiological recordings when the patient was under a lighter plane of anesthesia have been graphically represented in Figure 2b. MERS, macro stimulation and motor testing could be completed successfully with low dose dexmedetomidine infusion. At the end of surgery,

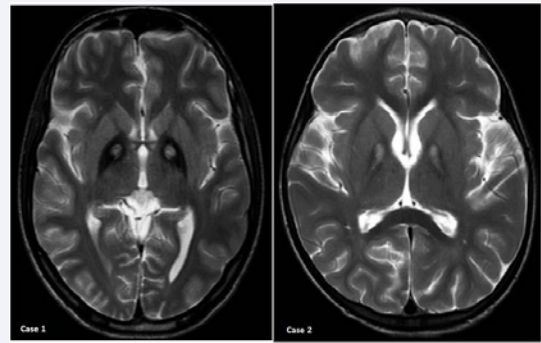


Figure 1 T2-weighted axial brain magnetic resonance images (MRIs) of both the cases shows the classical "eye of the tiger" sign in the globus pallidus.

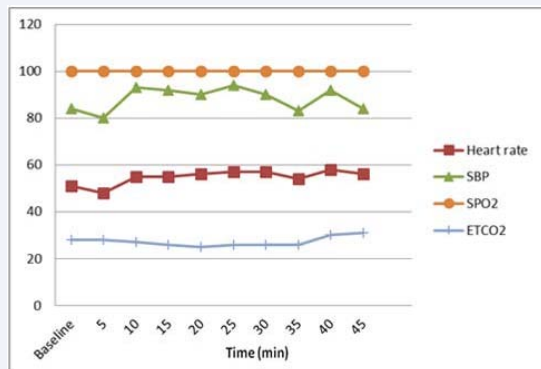


Figure 2a The graphical representation of the monitored vital parameters in Case 1 where the procedure was conducted under sedation with dexmedetomidine without tracheal intubation and general anesthesia.

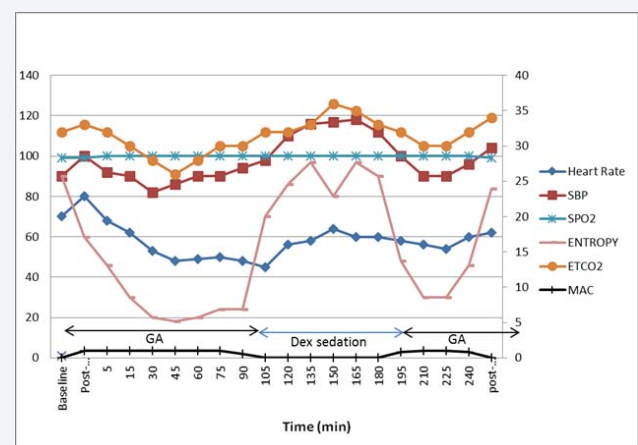


Figure 2b The trend of vital parameters in Case 2 where the procedure was conducted under general anesthesia with tracheal intubation. Spectral entropy was monitored in this case which was maintained below 40 during general anesthesia with 1.0 MAC concentration of sevoflurane and was maintained above 90 during MERS under dexmedetomidine sedation without inhalational agent (SBP-systolic blood pressure, DBP-diastolic blood pressure, MAP-mean arterial pressure, MAC-minimum alveolar concentration, SpO2-oxygen saturation, EtCO2-end tidal carbon dioxide).

dexmedetomidine and fentanyl infusions were stopped and the patient was breathing comfortably. Postoperative computed tomography scan (CT) of the brain confirmed the accurate positioning of the electrodes. The scan also revealed a small volume pneumocephalus. Following the CT scan, the child was awake, obeying verbal commands, was moving all limbs, and her trachea was extubated.

The rest of the post-operative stay in the hospital was uneventful. Her clinical dystonic condition improved following DBS. At 3 months follow up Fahn-Marsden scoring for dystonia had improved to 38 from a score of 57 before the surgery (Figure 3).

DISCUSSION

PKAN is a rare disease with reported frequency of one in one million [1]. Irreversible ablative stereotactic procedures have been performed surgically to treat medically refractive conditions [3,7]. In a retrospective study conducted by Timmermann et al., data of 23 patients with neurodegeneration with brain iron accumulation (NBIA) who underwent stereotactic neurosurgical procedure across many centres worldwide were collected and analysed. They concluded that secondary dystonia in NBIA improved following GPi-DBS and patients with severe dystonia fared better following stereotactic surgery. The authors also advocate surgery as soon as the dystonia became disabling and before any skeletal deformity manifested [11]. In recent times, DBS is increasingly being performed, even in paediatric patients as it is reversible, safe and titration of stimulation is possible [5,6,9].

Generalized dystonias, restricted airway access caused by the head frame, need for an awake and co-operative patient and ideal conditions for intraoperative MERs, all demand an appropriate anesthetic technique.

Literature on anesthetic management for DBS in PKAN is limited to a few case reports [3-9]; GA was employed in majority of these cases. A few reports have mentioned the use of propofol [3,6,8]. Keegan et al. [7], used sevoflurane (5%) induction for intubation and maintained anesthesia with fentanyl 100 µg,

pancuronium, and isoflurane in N₂O and O₂. Isoflurane was titrated to a MAC of 0.4-0.7% at the time of electrical mapping. Propofol infusion was used for transport to and from the MRI room. Postoperatively, the patient had airway obstruction which was attributed to anxiety but other possibilities like the effects of residual anaesthetic, surgical manipulations, or inadequate thalamic ablation, could not be ruled out. Koc et al. [9], used propofol (2mg/kg), remifentanyl (0.3ug/kg) and vecuronium (0.1mg/kg) for intubation; similar to our technique. For maintenance of anesthesia, sevoflurane 1-2% in O₂ and air, and remifentanyl infusion at 0.1ug/kg/min was used, which was titrated to 1% and 0.05-0.1ug/kg/min respectively while monitoring the motor responses to electrode stimulation. However, this technique did not permit the observation of immediate desired effects and possible complications of lesioning. Post operatively they used remifentanyl and midazolam for overnight elective ventilation and extubated the patient next day. Dystonia has reappeared after 3 hours of extubation which were controlled with dexmedetomidine infusion at 0.3ug/kg/hr. Unlike Koc et al., we used a low dose of dexmedetomidine infusion during electrophysiological monitoring which facilitated the motor examination and also helped us to note the onset of any adverse effects.

Anesthetic agents such as propofol and benzodiazepines can lead to respiratory depression and can potentially affect the MERs during DBS, as they are GABA-mimetic. Hutchison et al. [12], observed that the firing rates in the GPi nucleus were substantially reduced and were associated with long pauses under GA with propofol as compared with local anesthesia. Further, GA limits the benefit of clinical testing. Therefore, a sedative technique which does not interfere with the MERs could be a good alternative to GA.

Because of its unique properties and mechanism of action, dexmedetomidine may prove to be a good choice for sedation in patients with dystonias. Dexmedetomidine acts at sub cortical level, thus preserves cognitive functions and provides conscious sedation that mimics natural sleep. It induces prolonged non-REM sleep through alpha-2 adrenergic modulation. As suggested by Rao et al., probable mechanism for reduction of dystonias could be due to reduced muscle tone during non-REM sleep [10]. Further, it has non-GABA mimetic action with minimal effects on MERs [13,14]. In low dose, it does not alter the hemodynamic, or does it suppresses the respiration and is easily titrable. As an adjuvant to GA, it reduces the requirement of the opioids and inhalational anesthetics. However, its use during PKAN has not been explored much.

MER's were recorded in the second case when a low dose of dexmedetomidine was still on flow, and was stopped 5minutes prior to the recordings in the first. First patient was conscious and co-operative and the second was drowsy but easily arousable. The quality of MERs was good in both the patients. In Case2, we used entropy to titrate the sedation as the patient received GA with tracheal intubation. Entropy value was more than 90 during stimulation and MER. Elias et al. [15], used BIS monitoring to titrate dexmedetomidine sedation in patients with Parkinson's disease. They found that on titration of sedation to an easily arousal state (BIS value > 80) with dexmedetomidine infusion at

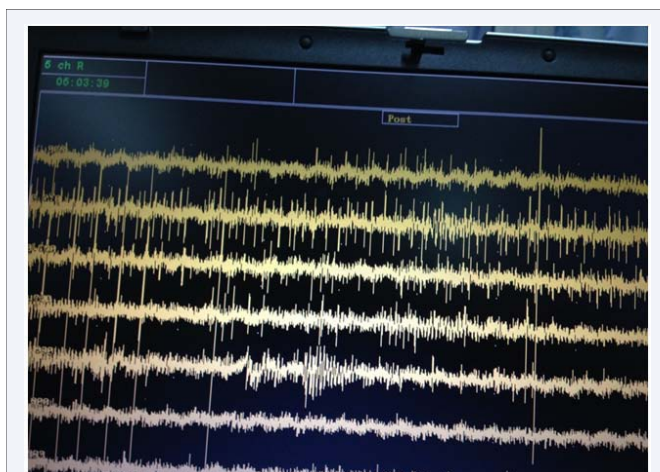


Figure 3 Microelectrode recordings (MERs) at 7 different depths on one side in Case2 during stimulation of globus pallidus internus.

0.1-0.4 µg/kg/h, the quality of sub thalamic MERs was equivalent to that in the awake state while they were suppressed with deep sedation (BIS <80).

In conclusion, dexmedetomidine either independently for conscious sedation or as an adjunct to GA is an effective and safe option in the anesthetic management of PKAN patients undergoing DBS surgery to control dystonias and facilitate intraoperative MERs and functional assessment. Dexmedetomidine can be initiated preoperatively for MRI imaging and can be continued in the postoperative course if required, thus avoiding the need of multiple anesthetic agents. Low dose fentanyl infusion can be used during surgery to supplement analgesia as dexmedetomidine alone has a weak analgesic property. Spectral entropy monitoring is a good option to assess sedation during dexmedetomidine infusion under GA.

REFERENCES

- Swaiman KF. Disorders of the basal ganglia. In: Swaiman KF, editors. Pediatric neurology: principles and practice. St Louis: Mosby. 1994: 1071-1098.
- Hayflick SJ, Westaway SK, Levinson B, Zhou B, Johnson MA, Ching KH, et al. Genetic, clinical, and radiographic delineation of Hallervorden-Spatz syndrome. *N Engl J Med.* 2003; 348: 33-40.
- Balas I, Kovacs N, Hollody K. Staged Bilateral Stereotactic Pallidotomy for Life-Threatening Dystonia in a Child with Hallervorden-Spatz Disease. *Movement Disorder.* 2006; 21: 82-85
- Umamura A, Jaggi JL, Dolinskas CA, Stern MB, Baltuch GH. Pallidal deep brain stimulation for long standing severe generalized dystonia in Hallervorden-Spatz syndrome. Case report. *J Neurosurg.* 2004; 100: 706-709.
- Castelnau P, Cif L, Valente EM, Vayssiere N, Hemm S, Gannau A, et al. Pallidal Stimulation Improves Pantothenate Kinase-Associated Neurodegeneration. *Ann Neurol.* 2005; 57: 738-741.
- Pinsker MO, Volkmann J, Falk D, Herzog J, Steigerwald F, Deuschl G, et al. Deep brain stimulation of the internal globus pallidus in dystonia: target localisation under general anaesthesia. *Acta Neurochir.* 2009; 151: 751-758.
- Keegan MT, Flick RP, Matsumoto JY, Davis DH, Lanier WL. Anesthetic Management for Two-Stage Computer-Assisted, Stereotactic Thalamotomy in a Child with Hallervorden-Spatz Disease. *J Neurosurg Anesthesiol.* 2000; 12: 107-111.
- Hurtado P, Salvador L, Carrero E, Rumia J, Fàbregas N. Anesthesia considerations for deep-brain stimulation in a patient with type-2 pantothenate kinase deficiency (Hallervorden-Spatz disease). *Rev Esp Anestesiol Reanim.* 2009; 56: 180-184.
- Koc D, Imer P, Bayri Y, Seker A. Anesthetic management for deep brain stimulation in a patient with pantothenate kinase-associated neurodegeneration. *J Anaesth Crit Care Pain Med.* 2014; 2: 122-125.
- Madhusudan Rao B, Radhakrishnan M. Dexmedetomidine for a patient with Hallervorden-Spatz syndrome during magnetic resonance imaging: a case report. *J Anesth.* 2013; 27: 963-964.
- Timmermann L, Pauls KA, Wieland K, Jech R, Kurlmann G, Sharma N, et al. Dystonia in neurodegeneration with brain iron accumulation: outcome of bilateral pallidal stimulation. *Brain.* 2010; 133: 701-712.
- Hutchinson WD, Lang AE, Dostrovsky JO, Lozano AM. Pallidal neuronal activity: implications for models of dystonia. *Ann Neurol.* 2003; 53: 480-488.
- Rozet I. Anesthesia for functional neurosurgery: the role of dexmedetomidine. *Curr Opin Anaesthesiol.* 2008; 21: 537-543.
- Rozet I, Muangman S, Vavilala MS, Lee LA, Souter MJ, Domino KJ, et al. Clinical experience with dexmedetomidine for implantation of deep brain stimulators in Parkinson's disease. *Anesth Analg.* 2006; 103: 1224-1228.
- Elias WJ, Durieux ME, Huss D, Frysinger RC. Dexmedetomidine and arousal effect of subthalamic neurons. *MovDisord.* 2008; 23: 1317-1320.

Cite this article

Surve RM, Srinivas D, Umamaheswara Rao GS, Bansal S, Gopalkrishna KN, (2017) Anesthetic Management for Stereotactic Neurosurgical Treatment of Patients with Pantothenate Kinase – Associated Neurodegeneration (PKAN) – An Experience of Two Cases with Dexmedetomidine. *Int J Clin Anesthesiol* 5(6): 1087.