

## Case Report

# Bone Formation in Subcutaneous Pocket after Bone Flap Preservation

Wen-xue Wang\*, Jian-wei Wang, Xin Kang, Guang-hui Fu and Yu-liang Liu

Department of Neurosurgery, Lianyungang Oriental Hospital, China

**\*Corresponding author**

Wen-xue Wang, No. 57 West Road ZHONGHUA, Lianyung District Lianyungang City 222042, Jiangsu Province, China, Tel: +86-1515268106; Fax: +86-58-80683069; Email: wangwenxue131@sina.com

Submitted: 16 November 2015

Accepted: 18 January 2016

Published: 20 January 2016

Copyright © 2016 Wang et al.

ISSN: 2373-9819

OPEN ACCESS

**Keywords**

- Autologous cranioplasty
- Subcutaneous pocket
- Complication
- Bone formation

**Abstract**

**Introduction:** Cranioplasty with autologous skull flaps has obvious advantages, but also induces various complications. We present a case of a rare complication after cranioplasty: bone formation on the residual periosteum in the subcutaneous abdominal pocket.

**Materials and methods:** In the present case, partial residual periosteum developed periosteal bone formation in the pocket 10 years after cranioplasty. Thus, lumpectomy was conducted on the left lower abdomen under local anesthesia.

**Results:** Pathological sections revealed abundant osteocytes and mature bone matrix, and confirmed the bone formation on the residual periosteum.

**Conclusion:** The bone formation on the periosteum has a huge potential, and can provide a new idea for cranioplasty.

## INTRODUCTION

Cranioplasty not only protects the brain and restores head appearance, but also improves cerebral blood flow, cerebrospinal fluid circulation, and brain metabolism; repairs neurological function; eases trephine syndrome; and improves mental disorders [1]. Materials commonly used for cranioplasty include autologous skull flaps, plexiglass, methacrylate, and titanium mesh. Every material is associated with corresponding complications, and has specific advantages and disadvantages [2]. Since 2003, we have performed cranioplasty using autologous skull flaps preserved in a subcutaneous pocket on the left lower abdomen. In the present case, partial residual periosteum developed periosteal bone formation in the pocket 10 years after cranioplasty.

## CASE PRESENTATION

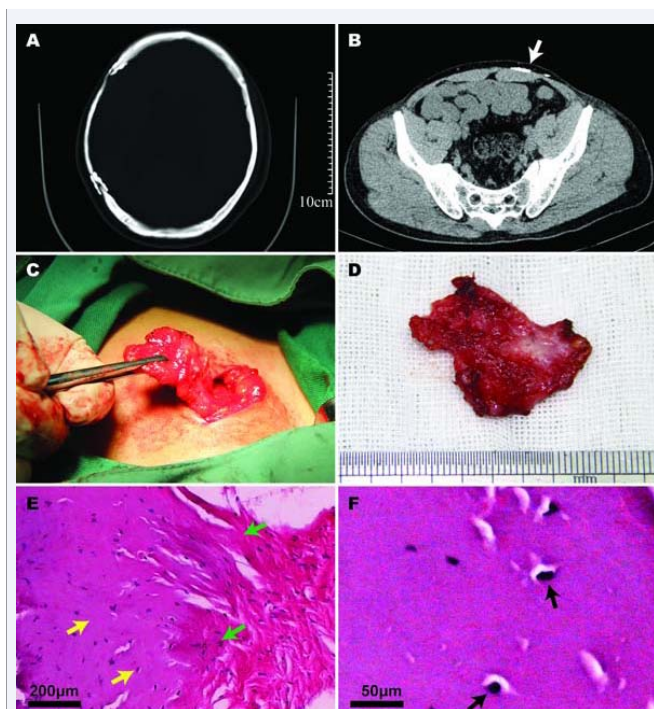
A 35-year-old man suffered brain contusion in the right temple and traumatic subdural hematoma as a result of a motorcycle accident in 2005. Thirty minutes after injury, he underwent tracheotomy and craniotomy with skull flap removal to clear the hematoma. Partial periosteum was preserved on the surface of the free skull flap. A 5-cm transverse incision was made in the skin on the patient's left lower abdomen. A pocket was created anterior to the subcutaneous location to contain the skull flap. The patient regained consciousness by day 5 after injury, was discharged on day 15, and was readmitted on day 68 for cranioplasty. The

preserved bone flap was retrieved and implanted at the site of the patient's skull defect, where it was fixed with three Rapidflaps Spindown Clamp (WalterLorenzSurgical®, Florida USA; Figure 1A). Beginning in the third year after cranioplasty, the patient became aware of a hard lump in the left lower abdominal region where the bone flap had been preserved. The lump did not enlarge remarkably, but became harder over time.

The patient felt a slight tingling sensation when he bent over or performed strenuous activity. Abdominal CT scan revealed a 25 × 15-mm sheet of high-density tissue (Figure 1B). The patient underwent lumpectomy with local anesthesia to remove the abnormal tissue 9 years, 7 months after cranioplasty (Figure 1C). The excised tissue was a hard sheet, 25 × 15 mm in size (Figure 1D). The tissue was fixed in formalin, stained with hematoxylin and eosin, and observed under low power (200×). A large number of osteocytes and mature bone matrix were visible (Figure 1E, yellow arrows). Abundant fibroblasts and collagen fibers were observed in the functional zone (Figure 1E, green arrows). Under high power (800×), mature osteocytes were distinctly visible (Figure 1F).

## DISCUSSION

All cranioplasty methods are associated with complications, including surgical and anesthetic risks, hemorrhage and wound infection, hydrocephalus, fluid under the scalp, and seizures [3]. Repairing the cranium with an autologous skull flap has obvious



**Figure 1** CT scan after cranioplasty (A); Abdominal CT scan revealed a 25 × 15-mm high-density sheet anterior to the left lower subcutaneous location (B); Removal of the 25 × 15-mm sheet of abnormal tissue (C, D); With hematoxylin-eosin staining, abundant osteocytes and mature bone matrix are visible under low power, and many fibroblasts and collagen fibers are observed in the junctional zone (E). Under the high-power lens (800×), mature osteocytes are distinctly visible (F).

advantages [4]: intraoperative shaping is not necessary, bone union is possible, anti-impact strength is near normal after healing, the cost of treatment is low, patients do not have psychological barriers or immune rejection, the graft has good growth potential and high resistance to infection, and the survival rate of bone flaps is high. Cheng et al. reported that cryopreserving autologous skull flaps in an autogenously pocket is safe and effective. The reported incidence of complications for cranioplasty with autologous skull flap is variable, ranging from 0 to 46%. ElGhoul et al. [2] reported a complication rate of 46% for cranioplasty with autologous skull flap, including many mild symptoms such as headache, irregular wounds, mild facial changes, small pulmonary embolism, pneumonia, wound swelling, and a subjective feeling of bone flap instability. Severe complications that required readmission to the hospital or reoperation accounted for 30% of all complications, and included epidural hematoma, drain occlusion, severe contusion, wound infection, hydrocephalus, subcutaneous fluid, subdural effusion, poor appearance, stroke with dysphasia, and temporal depression. The most common complications that are of great concern to neurosurgeons are bone resorption and wound infection. Previous studies indicate that bone flaps are commonly discarded for several reasons [5]. First, traumatic brain injury generally requires emergency surgery, necessitating removal of the lesion in the shortest time possible to relieve high intracranial pressure. Most clinicians have performed surgery by drilling and expanding the bone window. With the use of CT, craniotomy with formed bone flaps has also been performed, but also with extension of the bone window. Thus, autologous bone

flaps were seldom used in craniotomy in the past. In addition, it was thought that craniotomy with a formed bone flap required long surgical time during which decompression is not complete. Even when craniotomy with a bone flap is performed, bone flap preservation is challenging. Embedding the bone flap in the abdominal subcutaneous space has drawbacks: the bone flap can be absorbed and shrink, so that its size does not match the size of the bone window, or it can shrink postoperatively. Preserving the bone flap in vitro requires specific conditions. Considering all potential disadvantages, surgeons often elect to discard the bone flap. We have performed craniotomy with autologous skull flaps at our institution since 2003. Cryopreservation of skull flaps requires special equipment, and is not generally possible at primary hospitals. However, the preservation of bone flaps under the skin of the left lower abdomen is convenient. It is important to keep the following points in mind: (1) Autologous bone flaps are not subject to rejection, and there is no need for bone shaping. Operation time is short and the cost is low. (2) The optimal time for bone flap replantation is between the second and third months after craniotomy. Marked absorption can be avoided as long as the replantation time is less than 6 months. Even if the bone is slightly reduced in size, the titanium Rapid flapSpin down Clamp can achieve firm fixation. (3) The key to a successful outcome is to design a large enough bone flap for decompression according to the size of the hematoma and midline shift. Planning an adequately sized window avoids the use of a rongeur to widen the bone window, which can result in an irregular shape, leading to instable replantation of the bone flap and negative effects on healing. (4) It is necessary to preserve part of the periosteum when the bone flap is obtained during the initial craniotomy to allow an ideal connection between the bone flap and the window during replantation [6]. Therefore, we reserved part of the periosteum, and embedded the bone flap with attached periosteum subcutaneously in the left lower abdomen. However, residual periosteum can remain in the abdomen when the bone flap is retrieved for cranioplasty. The residual periosteum can differentiate from mesenchymal stem cells into osteocytes, which secrete bone matrix to directly generate new bone [7]. Bone marrow mesenchymal stem cells are the most common source of osteogenic cells. Rosales-Rocabado et al. [8] detected STRO-1- and CD105-positive cells in the mesenchymal stem cells of cranial periosteum. Wang et al. [9] reported the case of a 16-year-old patient who had subperiosteal hematoma after trauma; the hematoma was ossified 1 month after injury. Hoover et al. [10] reported the case of a 17-year-old patient with bilateral frontal damage caused by gunshot, whose wound was repaired with periosteum with a vascular pedicle after coronal craniotomy. Five months later, bone formation appeared in the cranial periosteum. Ono et al. [11] used computer-designed hydroxyapatite ceramics and skull periosteum flaps in three patients with skull defects, and demonstrated that incomplete bone formation occurred in the periosteum. These phenomena suggest that the periosteum has a great potential for bone formation, which may provide a new option for cranioplasty.

## REFERENCES

1. Grant FC, Norcross NC. REPAIR OF CRANIAL DEFECTS BY CRANIOPLASTY. *Ann Surg.* 1939; 110: 488-512.

2. El Ghouli W, Harrison S, Belli A. Autologous cranioplasty following decompressive craniectomy in the trauma setting. *Br J Neurosurg.* 2014; 6: 1-6.
3. Stephens FL, Mossop CM, Bell RS, Tigno T Jr, Rosner MK, Kumar A, et al. Cranioplasty complications following wartime decompressive craniectomy. *Neurosurg Focus.* 2010; 28: E3.
4. Cheng CH, Lee HC, Chen CC, Cho DY, Lin HL. Cryopreservation versus subcutaneous preservation of autologous bone flaps for cranioplasty: comparison of the surgical site infection and bone resorption rates. *Clin Neurol Neurosurg.* 2014; 124:85-89.
5. Flannery T, McConnell RS. Cranioplasty: why throw the bone flap out? *Br J Neurosurg.* 2001; 15: 518-520.
6. Gordon CR, Fisher M, Liauw J, Lina I, Puvanesarajah V, Susarla S, et al. Multidisciplinary approach for improved outcomes in secondary cranial reconstruction: introducing the pericranial-onlay cranioplasty technique. *Neurosurgery.* 2014; 10: 179-189.
7. Knight MN, Hankenson KD. Mesenchymal Stem Cells in Bone Regeneration. *Adv Wound Care (New Rochelle).* 2013; 2: 306-316.
8. Rosales-Rocabado JM, Kaku M, Kitami M, Akiba Y, Uoshima K. Osteoblastic differentiation and mineralization ability of periosteum-derived cells compared with bone marrow and calvaria-derived cells. *J Oral Maxillofac Surg.* 2014; 72: 694.
9. Wang Y, Zhang J. Ossification of subperiosteal hematoma: the potential of periosteal osteogenesis in cranioplasty. *J Craniofac Surg.* 2013; 24: 1603-1605.
10. Hoover DA, Mahmood A. Ossification of autologous pericranium used in duraplasty. Case report. *J Neurosurg.* 2001; 95: 350-352.
11. Ono I, Gunji H, Kaneko F, Numazawa S, Kodama N, Yoza S. Treatment of extensive cranial bone defects using computer-designed hydroxyapatite ceramics and periosteal flaps. *Plast Reconstr Surg.* 1993; 92: 819-830.

## Cite this article

Wang WX, Wang JW, Kang X, Fu GH, Liu YL (2016) Bone Formation in Subcutaneous Pocket after Bone Flap Preservation. *JSM Clin Case Rep* 4(1): 1093.