

Case Report

Resection of Superior Sulcus Tumor by a Combined Transmanubrial—Paulson Approach

Yoshitomo Okumura^{1*}, Taichi Koyama², Masaki Hashimoto³ and Seiki Hasegawa³

¹Department of Thoracic Surgery, Itami City Hospital, Japan

²Department of Surgery, Itami City Hospital, Japan

³Department of Thoracic Surgery, Hyogo College of Medicine, Japan

Special Issue on
Lung Cancer

***Corresponding author**

Yoshitomo Okumura, Department of Thoracic Surgery, Itami City Hospital, 1-100, Koyaike, Itami, Hyogo 654-8540, Japan, Tel: +81-72-777-3773; Fax: +81-72-781-9888; Email: yokumura@hosp.itami.hyogo.jp

Submitted: 27 January 2014

Accepted: 03 March 2014

Published: 15 March 2014

Copyright

© 2014 Okumura et al.

OPEN ACCESS**Keywords**

- Superior sulcus tumor
- Transmanubrial osteomuscular-sparing approach
- Paulson approach
- Induction chemoradiotherapy

Abstract

A 75-year-old man complained of pain and swelling of the right shoulder for 2 months. Plain chest radiography revealed a mass in the right upper lung field and dissolution of several ribs. Bronchoscopic brush cytology showed class V squamous cell carcinoma. The patient was diagnosed with clinical stage IIIA (cT4N0M0) lung cancer. After induction chemoradiotherapy, right upper lobectomy was performed and the chest wall was reconstructed. The successful outcomes suggest that the combined transmanubrial—Paulson approach in a half-lateral decubitus position is safe and suitable for resecting superior sulcus tumors.

ABBREVIATIONS

SST: Superior Sulcus Tumor; **FDG-PET:** ¹⁸F-Fluorodeoxyglucose Positron Emission Tomography; **SUV_{max}:** Maximum Standardized Uptake Value; **CT:** Computed Tomography

INTRODUCTION

The unique feature of Superior Sulcus Tumors (SSTs) is not the tumor biology but the almost inaccessible anatomic region in which they occur. One method for their resection is the transmanubrial osteomuscular-sparing approach, which involves sectioning parts of the manubrium and first costal cartilage and retracting them with the clavicle. However, thoracotomy is sometimes necessary. Here, we present a case of SST resection by a combined transmanubrial-Paulson approach.

CASE PRESENTATION

A 75-year-old man complained of pain and swelling of the right shoulder for 2 months. Plain chest radiography revealed a mass in the right upper lung field and dissolution of the first to third ribs (Figure 1-A). Chest Computed Tomography (CT) showed a 10 cm mass over the apex of the right lung. The images indicated that the mass had invaded the subclavian vessels and first to third ribs and involved the transverse process at the Th2 level (Figure 1-B, C). Bronchoscopic brush cytology suggested class V squamous cell carcinoma. ¹⁸F-Fluorodeoxyglucose

Positron Emission Tomography (FDG-PET) indicated that the maximum Standardized Uptake Value (SUV_{max}) of the tumor was 15.09 (Figure 1-D). The patient was diagnosed with clinical stage IIIA (cT4N0M0) lung cancer. He underwent induction chemoradiotherapy as the initial treatment. Radiation of 60 Gy and concurrent chemotherapy consisting of weekly carboplatin (2 mg/area under curve) and paclitaxel (35 mg/m²) were administered. Good partial response was obtained after six courses and the tumoral SUV_{max} decreased to 3.1 (Figure 2). We planned combined surgical removal of the subclavian vessels and transverse processes for complete tumoral resection by the Paulson approach. This method allows excellent exposure of the posterior chest wall including the transverse processes and thoracic nerve roots. The operation was undertaken with the patient in a half-lateral decubitus position with the neck hyperextended. The right arm was placed in an arm bag after sterilization and was not fixed, allowing free movement during the procedure. For the transmanubrial osteomuscular-sparing approach, operability in the thoracic cavity was initially determined by thoracoscopy. Then, the operating table was aligned to a near supine position and an L-shaped skin incision was made. The internal thoracic vessels were divided at this point, and the manubrium was divided with a sternal saw in a reverse L-shape. The first-rib cartilage and costoclavicular ligament were resected, and the flap was progressively retracted. The subclavian vessels were identified and confirmed to be tumor free. The tumor invading the entire first and second ribs was

DISCUSSION

The key point of our case is how the large tumor in a relatively inaccessible site was safely resected by the combined transmanubrial-Paulson approach. A total 60 Gy radiations and concurrent chemotherapy was done followed by surgery [1]. The Paulson approach, popularized for SST resection, involves high posterior thoracotomy with division of the muscles between the scapula and the spinous processes to expose the upper ribs posteriorly [2]. This method can clearly expose the posterior chest wall including the transverse processes and thoracic nerve roots. It also allows standard exposure of the pulmonary hilum. However, resection of the subclavian vessels is difficult. The subclavian vessels are located between the clavicle and the first rib. The subclavian area-opening approach for SST resection was first described by Darteville and colleagues as the anterior transcervical-thoracic approach, which involves an incision along the border of the sternocleidomastoid muscle that continues laterally over the clavicle [3]. This incision allows excellent exposure of the brachial plexus and subclavian vessels, and clear resection of the posterior portion of the two upper ribs. However, conventional lobectomy is difficult without another incision to complete the resection. As another subclavian area-opening approach, Grunenwald and Spaggiari proposed a transmanubrial osteomuscular-sparing approach in which the clavicle is retracted away from the first rib with part of the manubrium and sternoclavicular joint [4]. The method allows better exposure of the subclavian vessels and easier resection of the upper anterior chest wall than the anterior transcervical-thoracic approach. Its main advantage is that it protects the functions of the clavicle and the pectoral and sternocleidomastoid muscles [5,6]. We therefore combined the Paulson and transmanubrial osteomuscular-sparing approaches. This combination can include an anterior approach and posterolateral thoracotomy

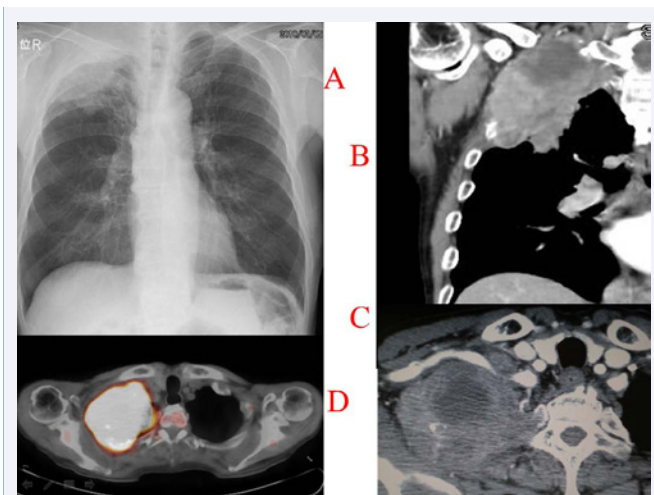


Figure 1 (A) The plain chest radiograph shows a mass in the right upper lung field and dissolution of the first to third ribs. (B, C) The chest CT show a mass 10 cm over the apex of the right lung. They indicate that the mass has invaded the subclavian vessels and three ribs (ribs 1st-3rd) as well as the transverse process at the Th2 level. (D) The FDG-PET image indicates that the tumoral SUV_{max} is 15.09.

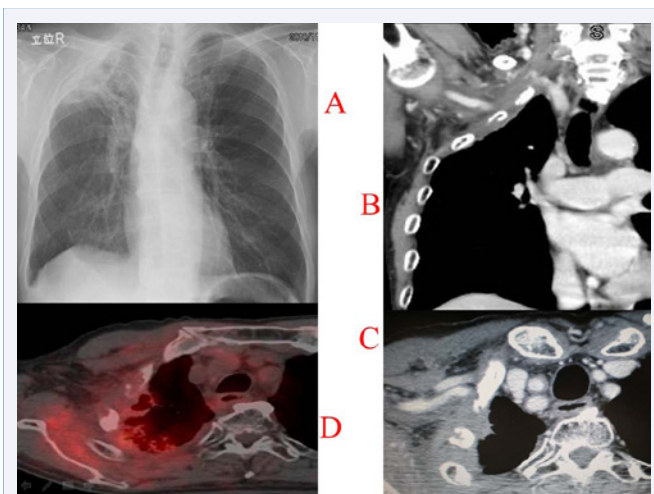


Figure 2 The (A) plain chest radiograph and (B, C) CT images indicate good partial response after the induction chemoradiotherapy. (D) The tumoral SUV_{max} decreased to 3.1.

resected and the wound was closed. Thereafter, the operating table was aligned to a normal lateral decubitus position for the Paulson approach. The skin incision extended around the tip of the scapula, midway between the posterior edge of the scapula and the spinous processes, and up to the C7 level. The high posterior costotransverse joint was exposed. After the tumor invading the entire first and second transverse processes was resected, part of the third and fourth ribs was resected and the Th1 and Th2 nerve roots were cut (Figure 3). No neurological complications, including palsy of the right arm and hand or Horner's syndrome, were observed. The patient is alive and has good shoulder function. The tumor has not recurred at 3 years after the operation.

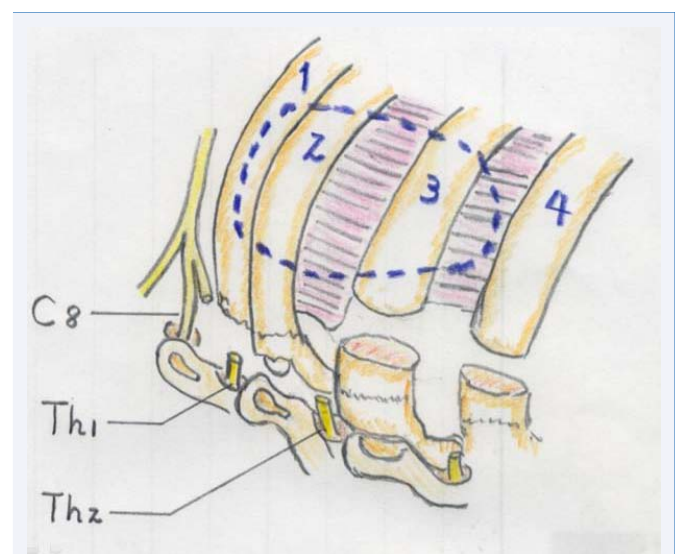


Figure 3 The tumor involving the entire first and second transverse processes and part of the third and fourth ribs were resected; the Th1 and Th2 nerve roots were also cut.

to divide the necessary hilar structures and vertebral elements. We achieved good visualization of the subclavian vessels while leaving the sternoclavicular joint intact.

We also developed a perioperative arm position for this approach. The arm on the operative side is not fixed, but can move freely in an arm bag after sterilization. While adjusting the operating table, it can be positioned anteriorly or laterally to the body. The patient lies in the half-lateral decubitus position on the operating table. The position can be set to either nearly supine for the anterior approach or nearly lateral decubitus for the posterior approach by rotating the operating table.

CONCLUSION

The combined transmanubrial–Paulson approach safely yields excellent results during SST resection.

ACKNOWLEDGEMENT

We thank Mrs. Rieko Okumura for her assistance in preparing the manuscript.

REFERENCES

1. Wright CD, Menard MT, Wain JC, Donahue DM, Grillo HC, Lynch TJ, et al. Induction chemoradiation compared with induction radiation for lung cancer involving the superior sulcus. *Ann Thorac Surg.* 2002; 73: 1541-1544.
2. Shaw RR, Paulson DL, Kee JL. Treatment of Superior Sulcus Tumor by Irradiation Followed by Resection. *Ann Surg.* 1961; 154: 29-40.
3. Dartevelle PG, Chapelier AR, Macchiarini P, Lenot B, Cerrina J, Ladurie FL, et al. Anterior transcervical-thoracic approach for radical resection of lung tumors invading the thoracic inlet. *J Thorac Cardiovasc Surg.* 1993; 105: 1025-1034.
4. Grunenwald D, Spaggiari L. Transmanubrial osteomuscular sparing approach for apical chest tumors. *Ann Thorac Surg.* 1997; 63: 563-566.
5. Dettterbeck FC. Changes in the treatment of Pancoast tumors. *Ann Thorac Surg.* 2003; 75: 1990-1997.
6. Matsuguma H, Nakahara R, Ishikawa Y, Suzuki H, Ui A, Yokoi K. Transmanubrial osteomuscular sparing approach for lung cancer invading the anterior part of the thoracic inlet. *Gen Thorac Cardiovasc Surg.* 2010; 58: 149-154.

Cite this article

Okumura Y, Koyama T, Hashimoto M, Hasegawa S (2014) Resection of Superior Sulcus Tumor by a Combined Transmanubrial—Paulson Approach. *J Cancer Biol Res* 2(1): 1029.