

Research Article

Sequential Crohn's Ileitis, Ileosigmoidal Fistula, Segmental Sigmoid Polyposis, and Sigmoid Stricture: The Natural History

Burton I. Korelitz*, Vivek Kesar, Raja Taunk and Judy Schneider

Division of Gastroenterology, Department of Medicine, Lenox Hill Hospital, USA

***Corresponding author**

Burton I. Korelitz, M.D., Division of Gastroenterology, Department of Medicine, Lenox Hill Hospital, 100 East 77th Street, 6 Black Hall, New York, NY 10075, USA, Tel: 212-434-2063; Fax: 212-434-2446; E-mail: bkorelitz@nshs.edu

Submitted: 31 August 2015

Accepted: 04 November 2015

Published: 06 November 2015

Copyright

© 2015 Korelitz et al.

OPEN ACCESS**Keywords**

• Ileosigmoid fistula; Sigmoid polyposis; Sigmoid stricture; Natural history

Abstract

Background: We have previously recognized segmental sigmoid polyps as an indicator of a fistula from Crohn's ileitis to the sigmoid or proximal rectum. In the course of this study we realized that many patients with this fistula had no sigmoid polyps, but the sigmoid was the site of marked inflammation and early or late stricture formation. Furthermore, in some patients with a stricture, the fistula was not recognized until the Surgeon (or the Pathologist) dissected an inflammatory peri-ileal and/or a peri-sigmoidal mass.

In this study we have sought to clarify the sequence of events by focusing on the segmental inflammation and stricturing of the sigmoid so that its significance be recognized as a local complication of the ileitis and progression of its severity as opposed to arising *sui generis*.

Methods: From our database of more than 3000 patients with inflammatory bowel disease (IBD) at Lenox Hill Hospital we have identified 45 patients with Crohn's ileitis and ileo-sigmoid fistula; 24 had segmental sigmoid polyps and 18 had segmental inflammatory sigmoid strictures. The fistula was first seen by imaging in 36 but not until resection by the Surgeon or dissection by the Pathologist in 7.

Results: The method of diagnosis for the initial recognition of the ileo-sigmoid fistula and the sigmoid stricture are presented in the Table 1. In 36 of the 45 cases the ISF was recognized by radiological imaging. 31 of the 36 required surgical intervention, not because of the fistula but because of small bowel obstruction due to the ileitis. In 7 of the 31 (22%) the fistula was recognized only by dissection of the inflammatory ileo-sigmoid mass by the surgeon or examination of the surgical specimen by the Pathologist. The sequence of events from the originating ileitis to the ileo-sigmoid fistula to the segmental sigmoid polyposis and stricture with resulting sigmoid obstruction is shown in Figure 1A-E.

Conclusion: Emphasis is made on the natural history of the I-S fistula so that its recognition will lead to earlier medical management of the originating ileitis. Furthermore it adds evidence of the recognition that the causative agent of Crohn's disease is carried by the fecal stream.

ABBREVIATIONS

ISF: Ileo-Sigmoid Fistula; CD: Crohn's Disease; CT: Computed Tomography Scan; MRE: Magnetic Resonance Enterography

INTRODUCTION

The internal fistula is a common manifestation of Crohn's disease (CD). A fistula is defined as a pathologic connection between two epithelial surfaces. Fistulas between the terminal ileum and the sigmoid colon have been described in up to 6% of all patients presenting with Crohn's Disease, and in 19% of those patients with CD with internal fistulas [1-3]. The radiological features of ileosigmoid fistulas (ISFs) were shown by Marshak [6-8], and subsequently the current clinical knowledge was reviewed by Korelitz in a Festschrift honoring Marshak in the Mount Sinai Journal of Medicine [9].

Historically, most ISFs were found and described at surgery [2-7]. Subsequently many diagnostic methods including

colonoscopy, small bowel X-ray, barium enema, computed tomographic scan (CT) and magnetic resonance enterography (MRE) have demonstrated the ISF prior to surgery. However, some ISF are unsuspected preoperatively and still found incidentally at surgery. Concerns about ionizing radiation and improvements in magnetic resonance technology have prompted the increased use of the MRE as a radiation-free alternative to the gastrointestinal/small bowel X-ray. Making the diagnosis of the ISF before surgical intervention has a great advantage because it has now been shown that CD fistulas respond to both immunosuppressives [10] and to biological [11].

Recognizing segmental sigmoid polyposis as an indicator of the ISF, we now emphasize the segmental sigmoid stricture as a later progression of the fistula and present our experience with 45 patients and its sequence of events, its methods of detection and outcomes of management. We predict that the natural history of this sequence will lead to earlier medical management of the underlying CD with a more favorable outcome.

Table 1: Mode of diagnosis of ISF with and without Sigmoidal Stricture ± Mass.

I-S Fistula (45)				I-S Fistula + Stricture (18)		
DX BY	DX BY SURGERY ±		DX BY	TOTAL #	DX BY	DX AT
	Imaging*	Pathology	Colonoscopy	Requiring Surgery	Imaging & Colonoscopy	
				SURGERY	NO SURGERY	± PATHOLOGY
36 (71%)	7/31 (22%)		2	31	6 (33%)	12 (66%)

*GI/SI X RAYS 22; BE X RAYS 12; CT/MRE 2
Abbreviations: GI/SI X Rays: Upper GI/Small Bowel X-Rays; BE X Rays: Barium Enema X Rays; CT: CAT Scan of the Abdomen and Pelvis; MRE: Magnetic Resonance Enterography

MATERIALS AND METHODS

Methods - In our database at Lenox Hill Hospital, we have over 3000 patients with Inflammatory Bowel Disease seen between 1975 and 2015. 1615 have Crohn’s disease (CD). In 45 the CD was limited to the terminal ileum from which an ISF was identified. 24 patients had segmental sigmoid polyposis without strictures. We sought to find how many of the remaining patients had inflammatory strictures of the colon limited to the sigmoid and whether this required surgical resection. We also sought to identify the way in which the ISF and the stricture were recognized by imaging and specifically which examinations, by endoscopy, or by the Surgeon and/or by the Pathologist.

RESULTS

Table 1 shows the breakdown by method of diagnosis in the 45 patients with ISF and the 18 with subsequent segmental sigmoid strictures. In 36 of the 45 cases the ISF was recognized by radiological imaging. 31 of the 36 required surgical intervention, not because of the fistula but because of small bowel obstruction due to the ileitis. These results strongly support the sigmoid stricture being a later complication of the ISF after the segmental sigmoid polyposis.

DISCUSSION

Segmental sigmoidal polyposis has been recognized as an indicator of ileo-sigmoid fistula subsequent to Crohn’s ileitis [1]. We have now extended this study to show that progression of the severity of the fistula and the polyposis leads to segmental sigmoid inflammation and with its worsening results in sigmoid stricturing. The stricturing may lead to colonic obstruction in which case surgical intervention might be required. Still more often the fistula leads to a combination of events including peri-ileitis and/or peri-sigmoiditis, intra-abdominal abscess, and intra-abdominal mass which are encountered by the surgeon at exploration. Most commonly, the patient undergoes an ileo-colectomy for obstruction due to the ileitis, with dissection of the mass which approximates the sigmoid; with recognition of the ISF, the surgeon resects a segment of sigmoid with a separate anastomosis or peels the fistula from the wall of the sigmoid and then oversews or closes the wall of that segment. Occasionally the mass is not so obvious, the fistula remains unrecognized and the sigmoid obstruction leads to a segmental resection, either in combination with the ileo-colic resection for the ileitis or without it, leaving the ileitis (which is not causing obstruction) for further medical management. Sometimes the sigmoid colon appears to be uninvolved with granulomatous inflammation; in those cases the simple closure of the wall of the colon is favored. Heimann,

et al [2,12] reported 17 cases of ISF covering most of these possibilities.

The significance of the sequence of ileitis to ISF to segmental sigmoid polyposis and then to sigmoid stricture clarifies the natural history in stages from isolated ileitis to sigmoidal obstruction. Clinically, the disease may be encountered at any stage of the progression without focusing on the events which preceded.

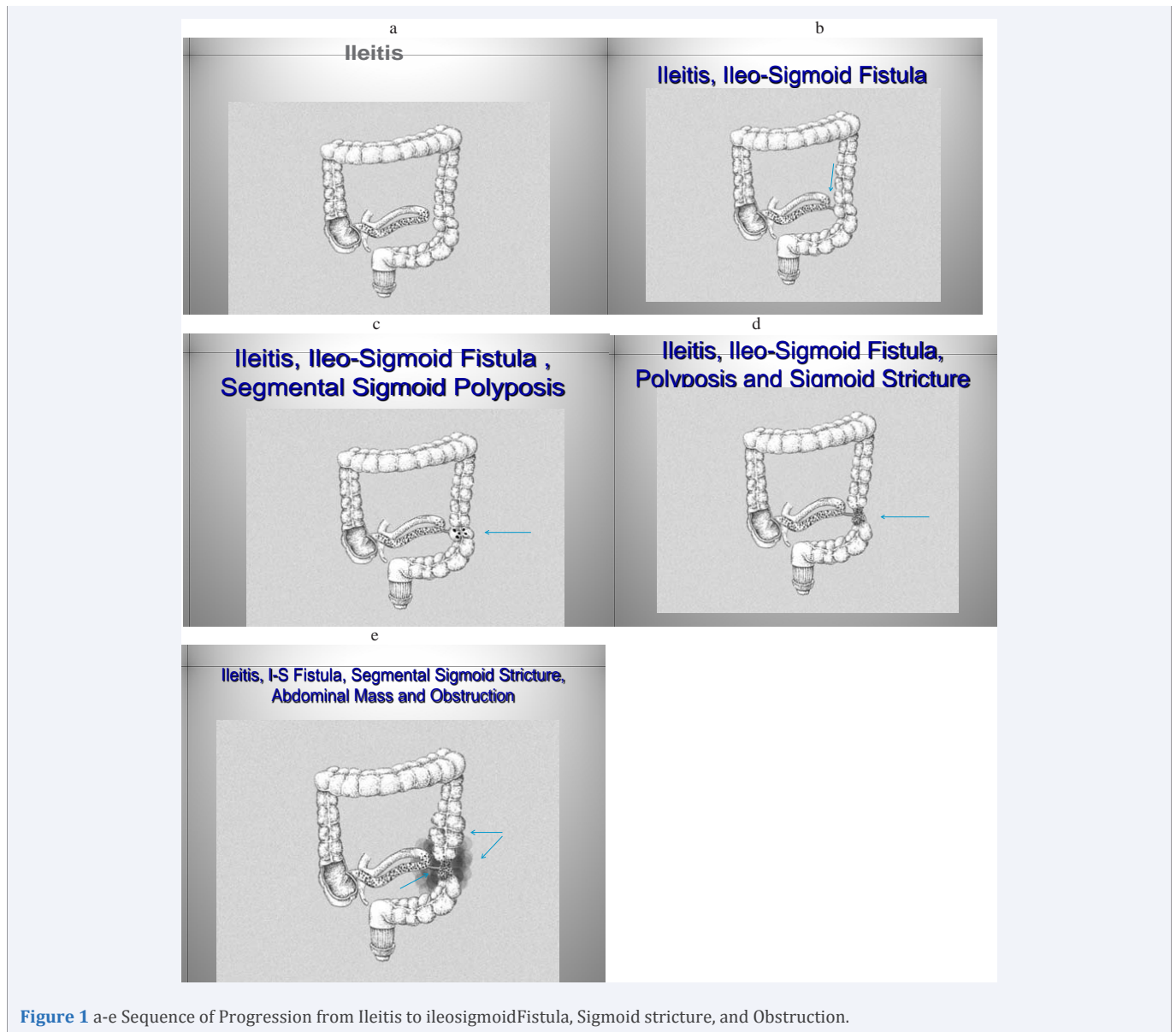
An understanding therefore of the natural history is valuable. Maximal medical therapy for the ileitis is warranted before the I-S fistula has matured and prior to its penetrating the serosa of the sigmoid in order to avoid resection of that segment as well as avoid surgical intervention at all. Furthermore, the ISF offers better understanding of the etiology of Crohn’s disease as it is confronted clinically.

We report the sequence of events in 45 cases of ISF and its progression to segmental sigmoidal stricturing in 18. The fistula was first demonstrated by imaging in 36 and found only at surgical exploration hidden in an abdominal mass of inflammatory tissue in 7. In only 2 was the diagnosis of fistula found at colonoscopy when the tract was gaping and draining into a segment of sigmoid with polyps. We extend our observations to show that 18 of our 45 patients developed progressive inflammation in that polypoid segment. This stricturing was demonstrated by imaging and colonoscopy in 6 but required surgical interventions in 12 because of severe disease with or without obstruction either by the diseased ileum or the sigmoid. Recognizing this chain of events clarifies the natural history of the progression of the ileitis.

This sequence supports the recognition that the causative mechanism of Crohn’s disease is carried by the fecal stream [13-16]. The agent becomes progressively increased in volume at the ileum proximal to the ileo-cecal valve, spreads beyond the walls of the ileum because of the resulting inflammation, obstruction and penetration, fistulizes to a conveniently located loop of bowel which commonly is the sigmoid, and then the causative agent concentrates in this new area and mimics the process in the original ileal location with polyposis, inflammation, stricturing and obstruction.

The evolution in Figure 1 (a-e) shows the sequence of events from ileitis leading to the ISF, progression to penetration of the sigmoid, segmental polyposis, sigmoid stricturing and potential colonic obstruction when untreated.

Progress in diagnosis has been too slow to arrive at correct treatment. The value of recognition of the entity at colonoscopy and imaging with CAT scans and Magnetic Radiographic



Enterography [17] for ileo-sigmoid masses or ISF and secondary damage to the sigmoid or proximal rectum, is one of the goals of this study.

CONCLUSION

We summarize our findings with the conclusion that the ileo-sigmoid fistula of Crohn's ileitis is a natural progression of the causative agent or mechanism leading to granulomatous inflammation and a subsequent insidious detrimental outcome when untreated. Historically this course has led to destruction of adjoining tissue and often to surgical intervention. Surgery will probably not be necessary when current successful therapies are utilized earlier in the chain of events [18]. Perhaps the ileo-sigmoid fistulas, segmental polyposis and sigmoidal stricture might yield a sigmoid reservoir providing a concentration of a causative agent to supply many ongoing studies on the search for the etiology of Crohn's disease.

ACKNOWLEDGEMENTS

We gratefully acknowledge the support of the New York Crohn's Foundation

REFERENCES

1. Korelitz BI, Taunk R, Kesar V. Segmental sigmoid polyposis as a colonoscopic indicator of an ileosigmoid fistula in Crohn's ileitis. *J Crohns Colitis*. 2015; 9: 339-341.
2. Heimann T, Greenstein AJ, Aufses AH Jr. Surgical management of ileosigmoid fistula in Crohn's disease. *Am J Gastroenterol*. 1979; 72: 21-24.
3. Broe PJ, Cameron JL. Surgical management of ileosigmoid fistulas in Crohn's disease. *Am J Surg*. 1982; 143: 611-613.
4. Block GE, Schraut WH. The operative treatment of Crohn's enteritis complicated by ileosigmoid fistula. *Ann Surg*. 1982; 196: 356-360.
5. Michelassi F, Block GE. Surgical management of Crohn's disease. *Adv Surg*. 1993; 26: 307-322.

6. Melton GB, Stocchi L, Wick EC, Appau KA, Fazio VW. Contemporary surgical management for ileosigmoid fistulas in Crohn's disease. *J Gastrointest Surg.* 2009; 13: 839-845.
7. Young-Fadok TM, Wolff BG, Meagher A, Benn PL, Dozois RR. Surgical management of ileosigmoid fistulas in Crohn's disease. *Dis Colon Rectum.* 1997; 40: 558-561.
8. Marshak RH. Granulomatous disease of the intestinal tract (Crohn's disease). *Radiology.* 1975; 114: 3-22.
9. Korelitz BI. The ileorectal and ileosigmoidal fistula in Crohn's disease: a clinical-radiological correlation. *Mt Sinai J Med.* 1984; 51: 341-346.
10. Korelitz BI, Present DH. Favorable effect of 6-mercaptopurine on fistulae of Crohn's disease. *Dig Dis Sci.* 1985; 30: 58-64.
11. Present DH, Rutgeerts P, Targan S, Hanauer SB, Mayer L, van Hogeand RA, et al. Infliximab for the treatment of fistulas in patients with Crohn's disease. *N Engl J Med.* 1999; 340: 1398-1405.
12. Fazio VW, Wilk P, Turnbull RB Jr, Jagelman DG. The dilemma of Crohn's disease: ileosigmoidal fistula complicating Crohn's disease. *Dis Colon Rectum.* 1977; 20: 381-386.
13. Colp R, Garlock JH, Ginzburg L. Ileocolostomy with exclusion for ileitis. *Am J Dig Dis.* 1942; 116: 906-912.
14. Rutgeerts P, Goobes K, Peeters M, Hiele M, Penninckx F, Aerts R, Kerremans R. Effect of faecal stream diversion on recurrence of Crohn's disease in the neoterminal ileum. *Lancet.* 1991; 338: 771-774.
15. D'Haens GR, Geboes K, Peeters M, Baert F, Penninckx F, Rutgeerts P. Early lesions of recurrent Crohn's disease caused by infusion of intestinal contents in excluded ileum. *Gastroenterology.* 1998; 114: 262-267.
16. Janowitz HD, Croen EC, Sachar DB. The role of the fecal stream in Crohn's disease: an historical and analytic review. *Inflamm Bowel Dis.* 1998; 4: 29-39.
17. Fallis SA, Murphy P, Sinha R, Hawker P, Gladman L, Busby K, et al. Magnetic resonance enterography in Crohn's disease: a comparison with the findings at surgery. *Colorectal Dis.* 2013; 15: 1273-1280.
18. Peyrin-Biroulet L, Sandborn W, Sands BE, Reinisch W, Bemelman W, Bryant RV. Selecting Therapeutic Targets in Inflammatory Bowel Disease (STRIDE): Determining Therapeutic Goals for Treat-to-Target. *Am J Gastroenterol.* 2015; 110: 1324-1338.

Cite this article

Korelitz BI, Kesar V, Taunk R, Schneider J (2015) Sequential Crohn's Ileitis, Ileosigmoidal Fistula, Segmental Sigmoid Polyposis, and Sigmoid Stricture: The Natural History. *JSM Gastroenterol Hepatol* 3(3): 1048.