

## Case Report

# Aortic Endograft Infection after Abdominal Aortic Endovascular Repair: Report of a Case Successfully Managed Conservatively

Rodrigo Petersen Saadi<sup>1</sup>, Marina Petersen Saadi<sup>2</sup>, João Augusto Bersch<sup>2</sup>, Ana Paula Tagliari<sup>3</sup>, and Eduardo Keller Saadi<sup>3\*</sup>

<sup>1</sup>Medical School - Pontifícia Universidade Católica do Rio Grande do Sul, Brazil

<sup>2</sup>Medical School - Universidade Luterana do Brasil, Brazil

<sup>3</sup>Hospital de Clínicas de Porto Alegre – Federal University of Rio Grande do Sul, Brazil

**\*Corresponding author**

Eduardo Keller Saadi, Cardiovascular and Endovascular Surgery, Federal University of Rio Grande do Sul, Porto Alegre, RS, Brazil, Tel: 55 51 99825379; Fax: 55 51 32224111; Email: esaadi@terra.com.br

Submitted: 26 June 2016

Accepted: 01 August 2016

Published: 03 August 2016

## Copyright

© 2016 Saadi et al.

## OPEN ACCESS

## Keywords

- Aortic endograft infection
- Endovascular aortic repair

**Abstract**

Even though aggressive surgical management is recommended for most cases of aortic endoprosthesis infection, because of the high surgical risk presented, conservative treatment should also be considered in selected cases. We present here a clinical case of a 84-year-old patient, presenting with low back pain, fever and weight loss for two months. He had undergone an endovascular infra renal aortic aneurysm repair three years ago. A computed tomography scans demonstrated bubbles inside the sac and a perianeurysmatic collection. A puncture of this collection was undertaken and the diagnosis of aortic endograft infection, caused by *Propionibacterium sp.*, was made. The patient was successfully managed conservatively with parenteral followed by long-term oral antibiotic therapy.

**ABBREVIATIONS**

AAA: Abdominal Aortic Aneurysm; EVAR: Endovascular Aortic Repair; CT: Computed Tomography

**INTRODUCTION**

Open surgical repair of abdominal aortic aneurysm (AAA) has slowly been replaced by endovascular aortic repair (EVAR) using aortic endografts. Currently, most of the AAA operations are preceded by endovascular therapy. Lifetime surveillance is important to identify late complications. Endoleaks are the most common complication of EVAR. Infection of the aortic endoprosthesis, although rare, is a feared complication and has been associated with significant morbidity and mortality.

Since the first report by Chalmers in 1993 [1], many advances in terms of treatment has occurred, however, the complete removal of the infected endograft and open aortic reconstruction remains the treatment of choice [2]. Nonetheless, endovascular aortic repair can be used in patients who are not candidates for open procedures and, therefore, the decision to perform an explantation, with thoracic aorta or pararenal aortic cross clamping, is associated with high risk of operative complications

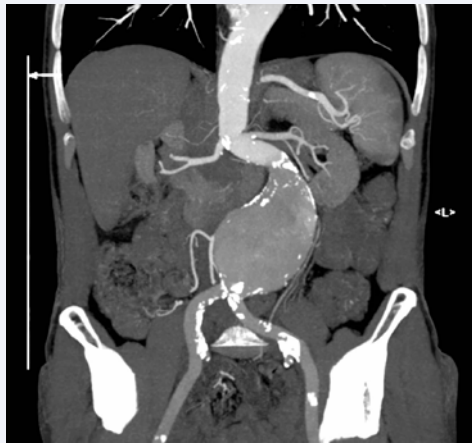or death. [3]. In such cases, conservative treatment has arisen as an alternative.

Regarding the microorganisms involved, the isolation of the microorganism is possible in 67.7% of the cases. *Staphylococcus aureus* is the most commonly isolated germ (54.5%), followed by *Enterococcus*, *Escherichia coli* and *Staphylococcus epidermidis* [4]. Even though infrequent, *Propionibacterium* (an anaerobic gram-positive bacillus that inhabits the skin) isolation has been reported in some papers [5,6].

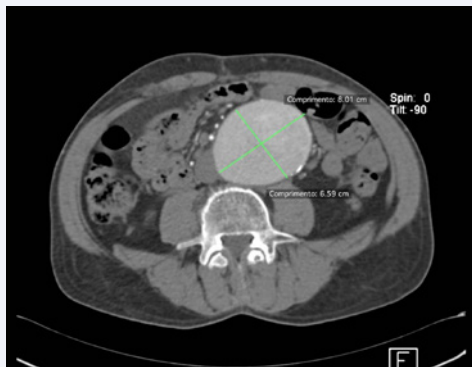
**CASE PRESENTATION**

An 84-year-old Caucasian man was admitted in our hospital three years after an endovascular repair of infrarenal, symptomatic, 8 cm diameter, AAA with a bifurcated stent graft (GoreTex Excluder®) in a hybrid room. He had an uneventful recovery after the EVAR and was discharged 2 days after the procedure. Postoperative computed tomography (CT) showed adequate EVAR correction, with no endoleaks and no signs of infection (Figures 1-3).

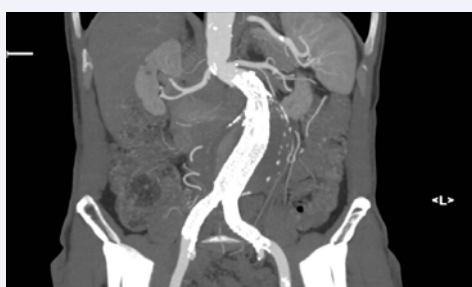The patient was frail and had undergone coronary artery bypass surgery combined with mitral valve replacement 12 years



**Figure 1** Multiplanar reconstruction of a large infra renal AAA with a good length neck anatomy for EVAR, although with an angulated proximal neck.



**Figure 2** Angiotomography with axial measurement of a large (8 cm) diameter AAA with no thrombus.



**Figure 3** Angiotomography 3 months after EVAR with a GORE ExcluderR device showing good repair, with no endoleaks and no signs of infection.

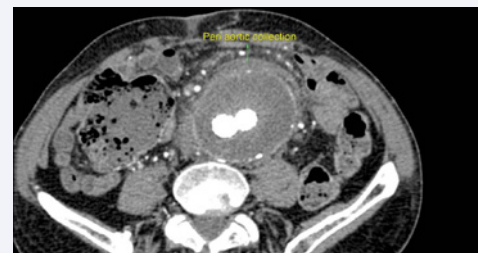
ago and prostatectomy, because of prostate cancer, 17 years ago. He also reported to be a former smoker with chronic obstructive pulmonary disease (COPD).

At his admission he related low back pain, fever and weight loss that started two months ago. His history and physical examination showed severe back pain and sensibility on aneurysm sac palpation. There were no other remarkable

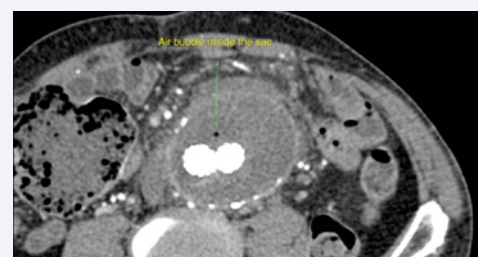
findings.

Considering his comorbidities and previous surgical interventions, the initial diagnostic hypotheses were: endocarditis, osteomyelitis or bone metastasis. Then, blood cultures, echocardiogram and CT scan of abdomen, thorax and lumbosacral spine were requested. Six consecutive blood cultures were negative and the echocardiogram showed norm functioning mitral valve prosthesis, with no evidence of intracardiac vegetations. On the other hand, the inflammatory biomarkers were elevated (erythrocyte sedimentation rate was 90 mm/h and C-reactive protein was 169 mg/L).

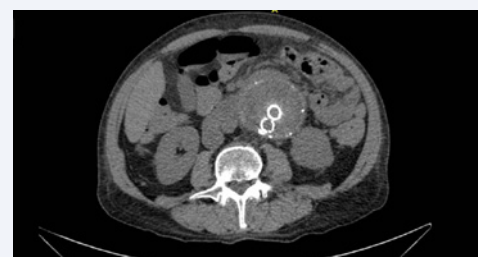The abdominal CT scan revealed infrarenal aortic endoprosthesis adequately sealed with the proximal anchoring below the renal arteries and distal anchoring at the level of the common iliac arteries. There were no endoleaks. The diameter of the aneurysmal sac was 8.1 x 7.0 cm. Periaortic fat infiltration was observed, especially in the anterior portion, where there was a 2cm rupture of the aneurysmal sac wall and



**Figure 4** Angiotomography (axial) showing per aortic collection 3 years after EVAR.



**Figure 5** Angiotomography demonstrating air bubble into the sac late (3 years) after EVAR. This is very suggestive of infection.



**Figure 6** Computed Tomography 6 months after successful conservative treatment of an infected endograft showing slight reduction of per aortic collection and no more air bubbles.

a contained small collection with a diameter of 2.3 x 1.0 cm. Gas bubble was founded inside the aneurysmal sac (Figures 4,5). Besides, small abscesses were located between the inferior right side of the aneurysmal sac and the inferior vena cava.

Based on these findings, we diagnosed aortic endograft infection. In order to guide antimicrobial therapy for a specific germ and because unavailability of pet-scan, we performed a CT-guided needle puncture of the fluid collection. Genetic sequencing of the collected fluid identified *Propionibacterium sp.*

In view of the high surgical risk of this patient, we decided for conservative management first. A 2 week empirical, parenteral, ampicillin/sulbactam plus gentamicin therapy was performed. After the germ identification, the therapy was changed to piperacillin/tazobactam plus rifampicin for another 4 weeks.

The patient presented prompt clinical improvement and inflammatory biomarkers reduction (erythrocyte sedimentation rate was 30 mm/h and C-reactive protein was 60 mg/L). A CT scan without contrast because of borderline renal function was performed after 6 months of antibiotic therapy showed perianeurysmatic collection shrinking and disappearance of the gas bubbles (Figure 6).

The patient was discharged after 43 days of hospitalization, with a plan to keep using amoxicillin 3g/day orally for lifetime.

Currently, the patient has completed two years of follow-up since the above reported event. There was no recurrence of symptoms or changes in follow-up abdominal CT.

## DISCUSSION

With the widespread use of endografts to treat AAA, complications are being increasingly reported. Endoprosthesis infection, after EVAR, is one of the most feared complications and has been associated with a very high morbidity and mortality. Its incidence ranges from 0.5 to 1% [7]. Early infection can occur by direct endograft contamination during the procedure or it can occur later as a result of a secondary infection source [7,8].

It is also worth noting that the infection may not be a complication of the procedure itself. Some of the bacteria may be, indeed, related to the aortic dilation [9].

Endoprosthesis infection diagnosis is not always easy because the clinical findings such as fever, back pain and laboratory alterations (leukocytosis and inflammatory markers), are insidious and advanced imaging methods are needed. Computed tomography angiography may show per aortic inflammatory changes such as fat standing, sac wall thickening, fluid collection and air bubbles inside the sac [10]. Although initial treatment involves the extended use of intravenous antibiotic, complete removal of the infected graft is usually necessary to eliminate the infection.

The R.I.EVAR (Registry of Infection in EVAR) is a relevant registry published this year relating 26 cases of abdominal aortic endograft infection. A 76.9% rate of positive microbiologic cultures was reported. EVAR infection was conservatively treated in 4 cases and a new endovascular treatment was proceeded in two, considered too fragile to be submitted to an open repair. This conservative treatment consisted in wide-spectrum, empirical,

antibiotic administration or percutaneous drainage combined to culture-specific antibiotic therapy. In the other hand, endograft excision was performed in 10 cases by conventional treatment (aortic stump + extra-anatomic bypass) and in other 10 cases by in situ reconstruction. Mortality rates were 50% in all treatment groups [11].

It is important also mention two studies carried out by Moulakakis [12] et al., and Murphy et al., [13]. The first paper, a review of 17 articles gathering 29 patients with aortic endograft infection treated with preservation of the stent-graft, showed that 79% of the endograft infections were diagnosed within 12 months of the initial procedure. In the second study, 18 patients were treated for infected endografts (thoracic= 6, abdominal= 12). The median time to diagnosis of the endograft infection was 90 days. Moulakakis found 21% of in-hospital mortality. In a mean follow-up of 11.4 ± 3.1 months, 7 additional deaths were observed, totalizing 45% of overall mortality. In the Murphy's article, 8 patients were considered too high-risk for explantation or refused open surgery and were, therefore, managed conservatively. In a mean follow-up of 24.7 months, the overall survival of patients with abdominal endografts was similar between the eight patients managed surgically and the four selected for medical management (75% vs 100%, p= 0.39). In both studies, patients with aortoenteric fistula had worse outcomes.

In other study performed by Cernohorsky et al., published in 2011 [14], 1431 endovascular procedures were evaluated. Six endograft infection cases were treated with antimicrobial therapy only, guided by bacterial cultures whenever possible and in other six cases, antimicrobial therapy was followed by surgical intervention. The mortality rate was 25%, with no significant difference between the two groups. Thus, the authors argue that there may be a role for conservative treatment in selected cases of patients with an infected endograft.

In this article we reported a clinical case of a patient diagnosed with a late aortic endograft infection caused by *Propionibacterium*. Due to a high surgical risk, we have chosen a conservative management. This patient presented clinical improvement associated with reduction of inflammatory biomarkers and improvement in CT findings. We conclude that in elderly and high-risk patients, conservative treatment of endograft infection, with long-term antibiotics, may be an alternative to radical surgery.

## REFERENCES

1. Chalmers N, Eadington DW, Gandanhamo D, Gillespie IN, Ruckley CV. Case report: infected false aneurysm at the site of an iliac stent. Br J Radiol. 1993; 66: 946-948.
2. Usatii A, Payne W, Santilli S. Removal of an infected aortic endograft and open aortic reconstruction: technical remarks. Ann Vasc Surg. 2013; 27: 679-683.
3. Smeds MR, Duncan AA, Harlander-Locke MP, Lawrence PF, Lyden S, Fatima J, et al. Treatment and outcomes of aortic endograft infection. J Vasc Surg. 2016; 63: 332-340.
4. Ducasse E, Calisti A, Speziale F, Rizzo L, Misuraca M, Fiorani P. Aortoiliac stent graft infection: current problems and management. Ann Vasc Surg. 2004; 18: 521-526.

5. Harlock JA, Qadura M, Lee G, Szalay DA. Infected aortic stent graft with *Propionibacterium acnes*. *Vasc Endovascular Surg*. 2013; 47: 394-396.
6. Etienne H, Touma J, Becquemin JP. Unusual acute onset of abdominal aortic endograft infection by *Propionibacterium acnes* after coil embolization for type II endoleak. *Ann Vasc Surg*. 2016.
7. Maleux G, Koolen M, Heye S. Complications after endovascular aneurysm repair. *Semin Intervent Radiol*. 2009; 26: 3-9.
8. Parra JR, Lee C, Hodgson KJ, Perler B. Endograft infection leading to rupture of aortic aneurysm. *J Vasc Surg*. 2004; 39: 676-678.
9. Marques da Silva R, Caugant DA, Eribe ER, Aas JA, Lingaas PS, Geiran O, et al. Bacterial diversity in aortic aneurysms determined by 16S ribosomal RNA gene analysis. *J Vasc Surg*. 2006; 44: 1055-1060.
10. Orton DF, LeVeen RF, Saigh JA, Culp WC, Fidler JL, Lynch TJ, et al. Aortic prosthetic graft infections: radiologic manifestations and implications for management. *Radiographics*. 2000; 20: 977-993.
11. Capoccia L, Speziale F, Menna D, Esposito A, Sirignano P, Rizzo AR, et al. Preliminary Results from a National Enquiry of Infection in Abdominal Aortic Endovascular Repair (Registry of Infection in EVAR-R.I.EVAR). *Ann Vasc Surg*. 2016; 30: 198-204.
12. Moulakakis KG, Sfyroeras GS, Mylonas SN, Mantas G, Papapetrou A, Antonopoulos CN, et al. Outcome after preservation of infected abdominal aortic endografts. *J Endovasc Ther*. 2014; 21: 448-455.
13. Murphy EH, Szeto WY, Herdrich BJ, Jackson BM, Wang GJ, Bavaria JE, et al. The management of endograft infections following endovascular thoracic and abdominal aneurysm repair. *J Vasc Surg*. 2013; 58: 1179-1185.
14. Cernohorsky P, Reijnen MM, Tielliu IF, van Sterkenburg SM, van den Dungen JJ, Zeebregts CJ. The relevance of aortic endograft prosthetic infection. *J Vasc Surg*. 2011; 54: 327-333.

#### Cite this article

Saadi RP, Saadi MP, Bersch JA, Tagliari AP, Saadi EK (2016) Aortic Endograft Infection after Abdominal Aortic Endovascular Repair: Report of a Case Successfully Managed Conservatively. *JSM Gastroenterol Hepatol* 4(3): 1064.