

Case Report

Endovascular Treatment of a Late Complication of an Open Repair of Abdominal Aortic Aneurysm

Marina Petersen Saadi¹, Rodrigo Petersen Saadi², Ana Paula Tagliari³, and Eduardo Keller Saadi^{3*}

¹Medical School – Universidade Luterana do Brasil, Porto Alegre, Brazil

²Medical School – Pontifícia Universidade Católica do Rio Grande do Sul, Porto Alegre, Brazil

³Hospital de Clínicas de Porto Alegre – Federal University of Rio Grande do Sul, Porto Alegre, Brazil

***Corresponding author**

Eduardo Keller Saadi, Cardiovascular and Endovascular Surgery, Federal University of Rio Grande do Sul, Porto Alegre, RS, Brazil, Tel: 55 51 99825379; Fax: 55 51 32224111; Email: esaadi@terra.com.br

Submitted: 14 July 2016

Accepted: 01 August 2016

Published: 03 August 2016

Copyright

© 2016 Saadi et al.

OPEN ACCESS**Keywords**

- Abdominal aortic aneurysm
- Endovascular treatment
- Open surgical repair
- Late complication
- Limb occlusion of aortobifemoral bypass

Abstract

Abdominal aortic aneurysms (AAA) are the most common type of aortic aneurysms. Traditionally it has been treated by open surgical repair (OSR), but in the last years endovascular repair (EVAR) became the first choice treatment in patients with suitable anatomy. Although the mortality and morbidity are lower with EVAR, late complications, such as endoleaks, remain a problem. Late complications after OSR are less frequent than after EVAR, but they still occur. We report a case of a patient with an uncommon late complication after OSR: limb occlusion of the Dacron prosthesis of an aortobifemoral bypass 14 years after. The rescue was performed by an unusual, but successful, urgent endovascular approach using intra-arterial thrombolysis with recombinant tissue plasminogen activator (rtPA) followed by covered stents implantation in the Dacron limb prosthesis and balloon angioplasty in the origin of a previous saphenous vein femoropopliteal bypass grafting. Late complications after EVAR and OSR, as well as treatment options, are discussed here.

ABBREVIATIONS

OSR: Open Surgical Repair; AAA: Abdominal Aortic Aneurysm; EVAR: Endovascular Repair; rtPA: Recombinant Tissue Plasminogen Activator

INTRODUCTION

Abdominal Aortic Aneurysm (AAA) is the most common type of aneurysm and it is lethal if untreated [1]. Until 1991, the only treatment option was open surgical repair (OSR). However, in 1991, the management began to change when endovascular aneurysm repair (EVAR) technique emerged as a less invasive alternative [2]. Nowadays, EVAR technique has become the first-line treatment of AAA in many centers around the world [3].

It has been reported that, although the OSR has more early postoperative complications (30 days), the long term complications (beyond 30 days) are rare [1,4,5]. Endoleaks and, as a consequence, further reinterventions, are the Achilles heel of EVAR. Nevertheless, the long-term mortality (6 years) is equal in both groups [4]. Although less frequent than after EVAR, open

repair sometimes needs late interventions, that's why it's advised lifelong surveillance. Here we present an uncommon case: a limb occlusion of an aortobifemoral bypass – a late postoperative complication of an OSR of an AAA, which was corrected by an unusual endovascular approach.

CASE PRESENTATION

A 64 year old male was admitted in our hospital with critical limb ischemia. He had several previous cardiovascular interventions: aortobifemoral bypass 14 years ago for an infra renal abdominal aortic aneurysm associated with iliac occlusive disease; right femoropopliteal bypass (saphenous vein above the knee) 8 years ago; and coronary stents 6 years ago.

The patient was asymptomatic until 3 days before going to emergency room, when he started with sudden rest pain in his right leg. The patient was anxious and restless, his right femoral and distal pulses were absent, and his right leg was pale. Doppler ultrasound demonstrated occlusion of the right limb of the aortobifemoral bypass and low flow (20 m/sec) in the right femoropopliteal bypass.

He was immediately transferred to the hybrid room and underwent an emergency endovascular approach. The occluded right limb was accessed by the left brachial artery and by retrograde approach in the right femoral artery, which was pulseless. An aortography was performed with a pigtail from the arm and confirmed total occlusion of the previous right limb of the aortobifemoral bypass (Figure 1). The recanalization was done from the arm with a 0,035 hydrophilic guide wire Roadrunner-Cook[®]. An intra- arterial trans procedure local thrombolytic therapy with recombinant tissue plasminogen activator (rtPA) through a multiperforated catheter was performed (Figure 2).

Another aortography after thrombolysis demonstrated significant improvement of the right artery flow and a tight stenosis at the origin of the femoropopliteal bypass saphenous vein graft (Figure 3).

The endovascular technique employed was: Shuttle-Cook[®] 8 F through the left arm and 2 Viabahn-Gore[®] 7x15 implanted inside the right limb of the aortobifemoral bypass; balloon accommodation (6x120) of the Viabahn[®] (Figure 4); balloon angioplasty (8x20) of the origin of the right limb; balloon angioplasty (6x20) of the origin of the femoropopliteal bypass (Figure 5).

The patient had immediate pain relief and normal distal pulses after procedure. He was discharged from the hospital next day with clopidogrel and aspirin. An angiotomography was performed 30 days after the procedure, which demonstrated normal flow in the aortofemoral bypass and in the right femoropopliteal bypass grafting as well (Figures 6,7).

DISCUSSION

Open surgical repair of AAA is associated with greater early mortality and morbidity than EVAR. The most common complications of OSR are bleeding (21.7%), incisional hernia (21.7%) and colonic ischemia (30.4%). Mortality associated to those complications is 23% [3]. For this reason, the outcome of the EVAR is better in the immediate post operatory period. On the

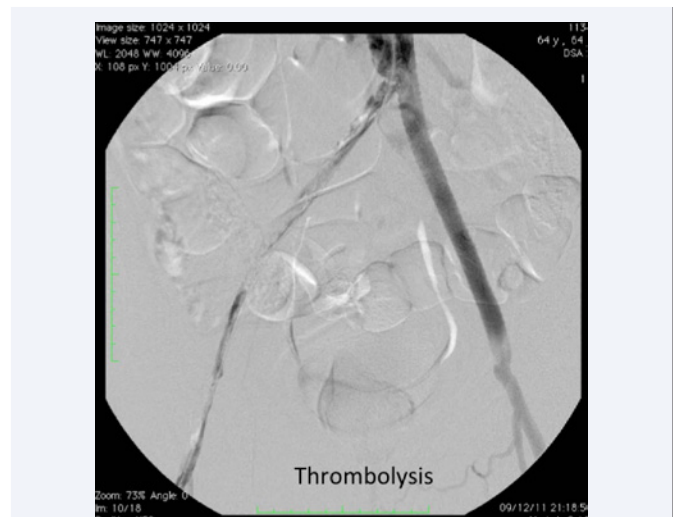

Figure 2 Intra-arterial thrombolysis with rtPA through a multi-perforated catheter.

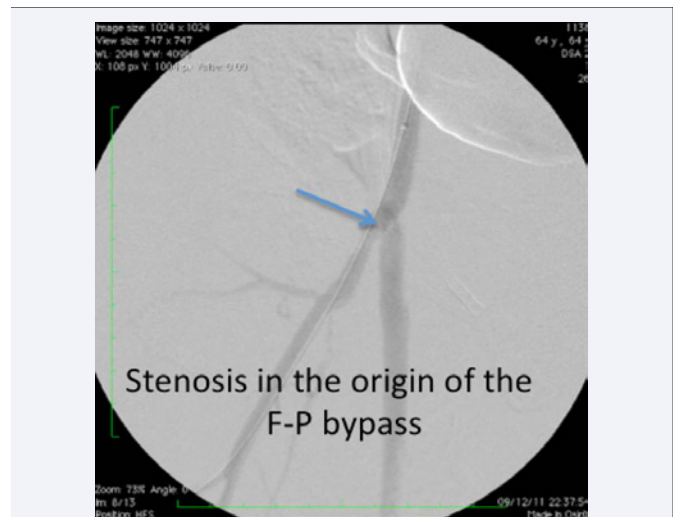


Figure 3 Angiography showing critical stenosis at the origin of the previous saphenous vein femoropopliteal bypass grafting.

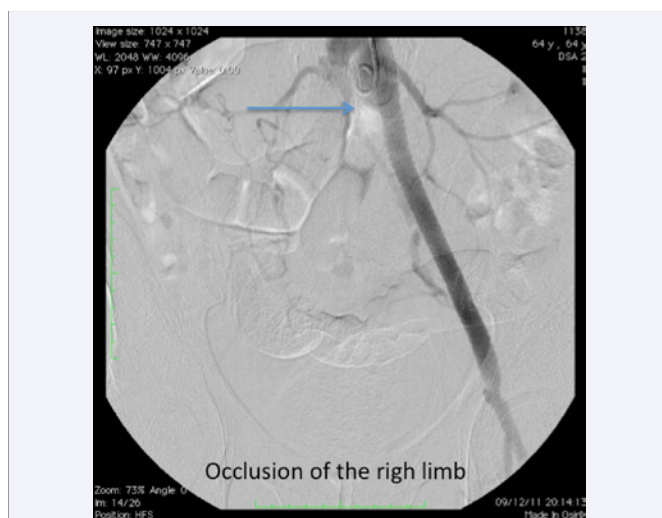


Figure 1 Angiography demonstrating total occlusion of the right limb of the aortobifemoral bypass.

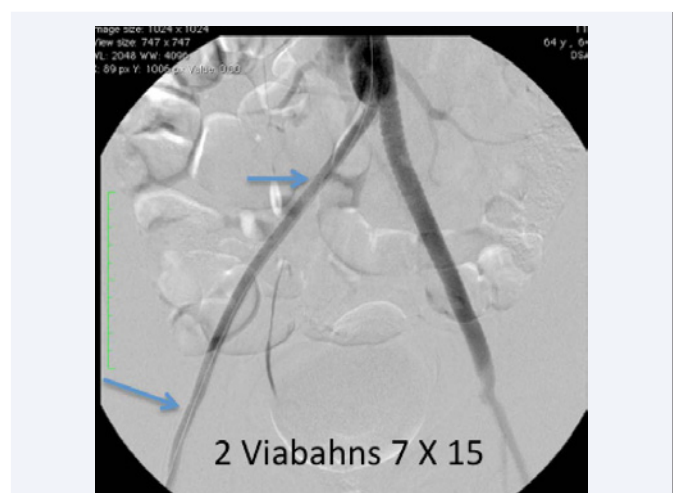


Figure 4 Two Viabahn[®] inserted inside the right Dacron limb.

other hand, late complications are very uncommon in OSR patients and much more common in EVAR patients. Approximately sixty-seven percent of late EVAR complications were endoleaks, 11.5% prosthesis migration and 11.5% occlusion. Therefore, follow-ups demonstrate that the long-term mortality is similar between the two groups [6].

A study demonstrated that 7.9% of EVAR patients require an intervention and 5.8% requires multiple reinterventions. This has been questioned and became the Achilles heel of endovascular interventions. By the other hand, just 3.6% of OSR patients require one reintervention and 1.6% requires multiple reinterventions [3]. Although OSR patients don't have as many late complications as EVAR, surveillance is needed because a considerable number of complications do exist.

Occlusion of the prosthesis is a rare complication after

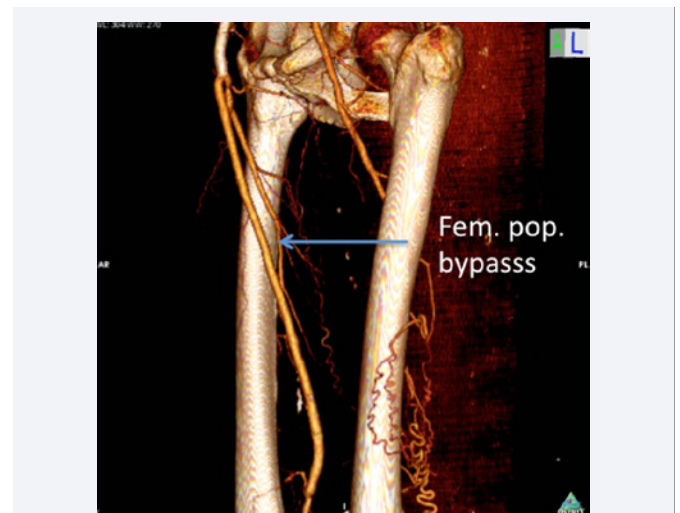


Figure 7 Post procedure angio CT demonstrating good result of the balloon angioplasty of the origin of the saphenous vein and a patent vein graft to the popliteal artery and no residual stenosis.

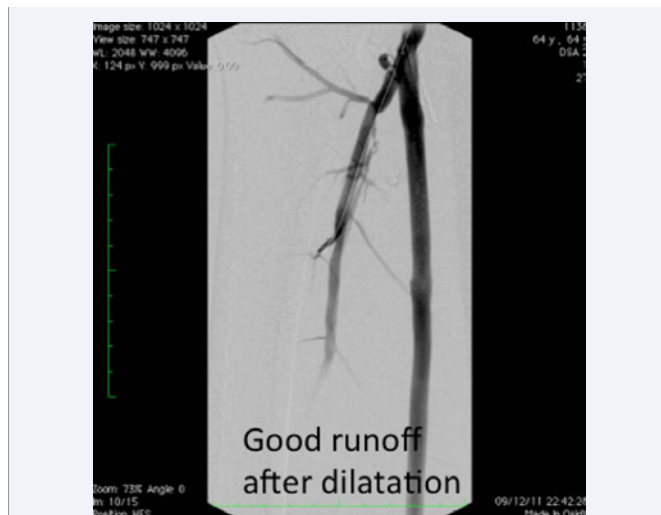

Figure 5 Angiography after balloon angioplasty of the origin of the saphenous vein graft femoropopliteal bypass showing good distal runoff.

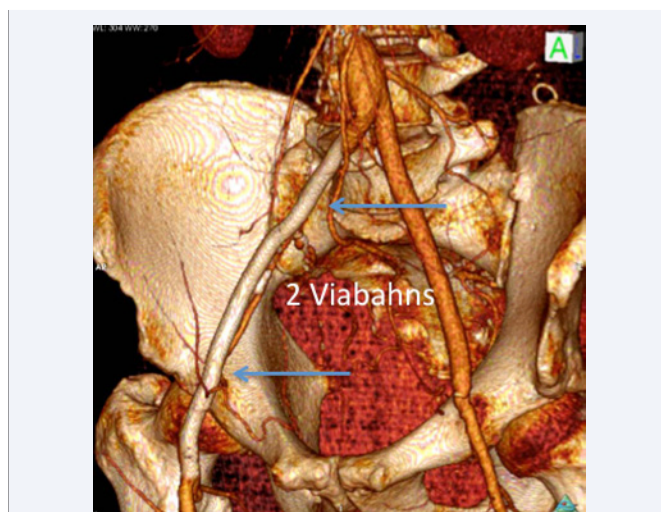


Figure 6 Post procedure angio CT showing the 2 Viabahn's inside the right limb with good distal flow.

conventional AAA repair and it is usually caused by coexistent iliac occlusive disease. The DREAM trial - a randomized trial comparing conventional and endovascular repair of abdominal aortic aneurysms - followed 178 open and 173 EVAR cases and found a total of 3 occlusions after open repair and 12 after EVAR [7]. Treatment of graft thrombosis can be performed with open or endovascular approach. Intra-arterial thrombolysis is being increasingly used in the graft acute thrombosis context, with good results [8,9].

A recent study of EVAR, with the Viabahn[®] stent for complex aortoiliac occlusions, compared to OSR showed that the primary occlusion rate was 0.58/100 person-years in the EVAR group and 0.31 in the OSR group. No significant difference in primary patency of the limb at 2 years of follow-up, was found between the groups (94% in the EVAR group vs 97% in the OSR group, $p = 0.50$). The average hospital length of stay was shorter for patients treated with EVAR and the complication rate was 4% for EVAR vs 18% for OSR ($p = 0.32$). The authors consider that the Viabahn[®] has four main advantages: (1) it is a covered stent, providing a direct barrier to the in-growth of neointimal hyperplasia; (2) it is extremely flexible, minimizing the risk of occlusion due to kinking in the tortuous external iliac artery; (3) it is low profile, allowing the 7-mm and 8-mm devices to be deployed via a 7F introducer sheath [10]; (4) it has long lengths up to 10 cm and 15 cm and more recently 20 cm, reducing the cost impact of using multiple grafts.

We report a case of serious late complication after conventional AAA repair that was treated successfully with endovascular therapy. It was an acute occlusion of the right limb of an aortobifemoral bypass performed 14 years ago. There are many treatment options, but we decided for an endovascular approach with thrombolysis and covered stent implantation (Viabahn[®]) inside the occluded limb. We preferred a covered stent to avoid distal embolization and for the possible better long-term permeability. There are a few studies showing good results when covered stents are used to treat extensive aortoiliac

disease but long-term results are not currently available [11,12]. An alternative treatment would have been balloon expandable covered stents such as ATRIUM V12^R but we didn't have it immediately available at that time in the hybrid room and they are shorter in length. The patient also had a severe stenosis at the origin of the saphenous vein graft used for previous femoropopliteal bypass 8 years ago, which was treated by balloon angioplasty. Probably this stenosis contributed to the occlusion of the right limb of the aortofemoral bypass because of bad distal runoff. We decided not to stent because it was located in a possible bending zone.

In conclusion, the treatment options in patients with aortic disease should be individualized and considered complementary and not competitive.

REFERENCES

- Huang Y, Gloviczki P, Oderich GS, Duncan AA, Kalra M, Fleming MD, et al. Outcome after open and endovascular repairs of abdominal aortic aneurysms in matched cohorts using propensity score modeling. *J Vasc Surg.* 2015; 62: 304-311.
- Parodi JC, Palmaz JC, Barone HD. Transfemoral intraluminal graft implantation for abdominal aortic aneurysms. *Ann Vasc Surg.* 1991; 5: 491-499.
- Al-Jubouri M, Comerota AJ, Thakur S, Aziz F, Wanjiku S, Paolini D, et al. Reintervention after EVAR and open surgical repair of AAA: a 15-year experience. *Ann Surg.* 2013; 258: 652-657.
- United Kingdom EVAR Trial Investigators, Greenhalgh RM, Brown LC, Powell JT, Thompson SG, Epstein D, et al. Endovascular versus open repair of abdominal aortic aneurysm. *N Engl J Med.* 2010; 362: 1863-1871.
- Becquemin JP. The ACE trial: a randomized comparison of open versus endovascular repair in good risk patients with abdominal aortic aneurysm. *J Vasc Surg.* 2009; 50: 222-224.
- Ren S, Fan X, Ye Z, Liu P. Long-term outcomes of endovascular repair versus open repair of abdominal aortic aneurysm. *Ann Thorac Cardiovasc Surg.* 2012; 18: 222-227.
- De Bruin JL, Baas AF, Buth J, Prinssen M, Verhoeven EL, Cuypers PW, et al. Long-term outcome of open or endovascular repair of abdominal aortic aneurysm. *N Engl J Med.* 2010; 362: 1881-1889.
- Mahler F, Schneider E, Hess H, Steering Committee, Study on Local Thrombolysis. Recombinant tissue plasminogen activator versus urokinase for local thrombolysis of femoropopliteal occlusions: a prospective, randomized multicenter trial. *J Endovasc Ther.* 2001; 8: 638-647.
- Wissgott C, Richter A, Kamusella P, Steinkamp HJ. Treatment of critical limb ischemia using ultrasound-enhanced thrombolysis (PARES Trial): final results. *J Endovasc Ther.* 2007; 14: 438-443.
- Psacharopulo D, Ferrero E, Ferri M, Viazzo A, Singh Bahia S, Trucco A, et al. Increasing efficacy of endovascular recanalization with covered stent graft for TransAtlantic Inter-Society Consensus II D aortoiliac complex occlusion. *J Vasc Surg.* 2015; 62: 1219-1226.
- Grimme FA, Goverde PA, Van Oostayen JA, Zeebregts CJ, Reijnen MM. Covered stents for aortoiliac reconstruction of chronic occlusive lesions. *J Cardiovasc Surg (Torino).* 2012; 53: 279-289.
- Hajibandeh S, Hajibandeh S, Antoniou SA, Torella F, Antoniou GA. Covered vs Uncovered Stents for Aortoiliac and Femoropopliteal Arterial Disease: A Systematic Review and Meta-analysis. *J Endovasc Ther.* 2016; 23: 442-452.

Cite this article

Saadi MP, Saadi RP, Tagliari AP, Saadi EK (2016) Endovascular Treatment of a Late Complication of an Open Repair of Abdominal Aortic Aneurysm. *JSM Gastroenterol Hepatol* 4(3): 1065.