SciMedCentral

JSM Atherosclerosis

Research Article

STREAMER (STentREstenosisAndMEdication Release): Failure of Local Delivery of Paclitaxel for the Prevention of Restenosis in Stenting of TASC C-D Femoropopliteal Segment

DELLA SCHIAVA Nellie[1]*, Iris Naudin[1,2], Marine Bordet[1,2], Matthieu Arsicot[1,2], PhilippeTresson[1], Christine Pivot[3], Jerome Guitton[4], Delphine Maucort-Boulch[5], Patrick Feugier[1,2], Antoine Millon[1,2], and Patrick Lermusiaux[1,2]

[1]*Department of Vascular and Endovascular Surgery, University Hospital of Lyon, France*
[2]*Claude Bernard Lyon 1 University, Lyon, France*
[3]*Department of Pharmacy, CHU Lyon, France*
[4]*Department Clinical Pharmacology, CHU Lyon, France*
[5]*Department of Biostatistics, CHU Lyon, France*

***Corresponding author**
DELLA SCHIAVA Nellie, Department of Vascular and Endovascular Surgery, Hôpital EHerriot, University Hospital of Lyon, 5 Placed'Arsonval, 69437 Lyoncedex03, France; Tel: 33-4-72-11-76-76, 33-6-84-17-27-88; Fax: 33-4-72-11-75-57; Email: dellaschiava.nellie@neuf.fr

Submitted: 22 November 2018

Accepted: 11 December 2018

Published: 13 December 2018

ISSN: 2573-1270

OPEN ACCESS

Keywords
- Restenosis
- Paclitaxel
- Critical limb ischemia
- TASC C and D
- Femoral-popliteal artery
- Drug eluted balloon

Abstract

Background and objective: Stenting of long lesions TASC C-D of the superficial femoral and/or popliteal artery (SFPA)in patients with critical limb ischemia (CLI) is associated with a restenosis rate of around 50% at one year. The aim of the present study was to evaluate feasibility and efficacy of a new local delivery of paclitaxel through a microporous PTFE balloon to prevent in-stent restenosis in these patients.

Methods: Prospective, single-centre, non-randomized study included patients with CLI presenting *de novo* atherosclerotic lesions of the SFPA >15 cm in length, grade C or D of the TASC II classification. Paclitaxel was delivered after stent implantation, using a microporous balloon. The primary endpoint was the rate of in-stent restenosis at 12 months.

Results: From December 2013 to August 2014, 15 patients were included; 9 were followed up until 1 year, of whom 8 had total thrombosis of the SFPA. Three patients dropped out of the study and 3 procedures failed. The average length of the stented segment was 352 mm. There was no delivery failure or adverse effects. During follow-up, there were 5 thromboses and 2 restenoses, leading to 2 bypasses, 3 angioplasties and one fibrinolysis, yielding a restenosis rate of 78% and a TLR rate of 67% at one year.

Conclusion: Our results suggest that local delivery of paclitaxel with this method of local delivery incurred no adverse effects but is not effective in preventing restenosis of long stenting of the SPFA in patients with CLI.

INTRODUCTION

The Trans-Atlantic Inter-Society Consensus Document II (TASC II) classification recommends surgery for multiple or long occlusive lesions type C or D of the superficial femoral and/or popliteal artery (SFPA), regardless of the clinical symptoms [1]. Technical progress has enabled endovascular treatment of these lesions. However, percutaneous transluminal angioplasty (PTA) of TASC C and D lesions in patients with critical limb ischemia (CLI) is associated with a restenosis rate of around 50% at one year [2,3]. Local delivery of paclitaxel has been used as a strategy to prevent restenosis for several years, such as with active coronary stents [4], drug-eluting balloons [5] or implantation of active stents for peripheral artery disease (PAD)[6]. In all contexts, the dose of paclitaxel was in the range of 3 µg/mm^2 [5-7].

However, studies showing the efficacy of active stents and balloons in femoropopliteal lesions were mainly performed on

TASC II A and B lesions. In 1997, Axel et al demonstrated the feasibility of local delivery of paclitaxel to the arterial wall using a microporous balloon [8]. A further animal study showed that diffusion of the drug was greater with a microporous balloon than with a coated balloon [9]. A microporous balloon made of polytetrafluoroethylene (PTFE), with a diameter compatible with the femoral and popliteal arteries, can be used for the local delivery of medication, notably fibrinolytics (Clearway, ATRIUM, MAQUET Getinge Group, Germany). Latif and Hennebry used this balloon for local delivery of paclitaxel in the lower limb arteries of 2 patients [10] and subsequently initiated the IRRITAX study (Local paclitaxel delivery for SFA disease, ClinicalTrials.gov, NCT00821028) in 2009. The IRRITAX study was a randomized study that included patients with claudication and TASC A, B or C lesions, but the results have not been published to date. The balloon itself does not contain any medication, which removes the risk of medication loss during the balloon transit and placement, and it can be moved and used to diffuse the medication as many times as necessary, making it possible to treat long lesions with a single device. To date, studies of local delivery of paclitaxel in the SFPA have not reported any drug-related adverse effects [3,10,11]. Intra-arterial chemotherapy using paclitaxel at doses equivalent to intravenous chemotherapy (175mg/m^2) did not lead to any specific complications in the study by Damascelli et al. [12]. Animal studies with an active stent (Zilver PTX Drug Eluting Stent, Cook Medical, Bloomington, Ind) at doses of up to 12 µg/mm^2 also failed to cause any local or general complications [13].

We hypothesized that local delivery of paclitaxel through a microporous PTFE balloon would reduce the rate of short-term restenosis after stenting of long, TASC C or D lesions of the SPFA in patients with CLI. In this context, we performed a pilot study to evaluate the feasibility and safety of this approach, with a view to designing a subsequent randomized, multicentre trial.

MATERIALS AND METHODS

This was a single-center, prospective, open-label, non-randomized feasibility study conducted between March 2013 and March 2015. The study was approved by the local Ethics Committee, and was also approved by the French national authority for the protection of privacy and personal data (CNIL), and the French national Health Products Safety Agency (ANSM). This study has been registered on Clinicaltrials.gov:NCT02835586

Study population

All adult (>18 years) patients presenting with *de novo* TASC C or D atherosclerotic lesions of the SFPA, and with CLI (stages III and IV of the Fontaine classification, with an ankle pressure <50 mmHg), and managed in our Department between March 2013 and March 2014 were eligible for inclusion. Intra-stent restenosis and non-atherosclerotic lesions were excluded. Patient with active cancer, neutropenia, or a known allergy to paclitaxel, and patients receiving chemotherapy or immunosuppressants were also excluded. All patients provided written informed consent before inclusion.

Study endpoints

The primary endpoint was the rate of restenosis at 12 months. Lesions were considered significant if narrowing was >50% on Doppler ultrasound with a peak systolic velocity >2.5.

Secondary endpoints were:

- the rate of restenosis at 1 and 6 months.

- the rate of primary and secondary patency at 1, 6 and 12 months.

- the occurrence of adverse effects related to the drug (leukopenia, thrombopenia).

- need for repeat intervention on the SFPA (target lesion revascularization, TLR) at 1, 6 and 12 months.

- need for repeat intervention on the same lower limb (target extremity revascularization, TER) at 1, 6 and 12 months.

- the rate of limb salvage at 1, 6, and 12 months.

- the cumulative rate of morbidity and mortality at 30 days defined as the occurrence of any one or more of the following criteria : death, myocardial infarction, unstable angina, stroke or transient ischemic attack (TIA), major amputation, re-admission or re-intervention for any of: hematoma, active bleeding, thrombosis, false-aneurysm or arteriovenous fistula.

- Comparison of blood levels of paclitaxel between patients presenting restenosis and those without restenosis.

Study procedures

Inclusion and follow-up: All patients who met the inclusion criteria had a biology work-up prior to the intervention, including full blood count, creatinine, C-reactive protein (CRP) and troponin. They also underwent Doppler ultrasound with morphological and hemodynamic assessment of the stenosis, measure of systolic blood pressure at the ankle, calculation of the ankle-brachial index, and assessment of limb vascularization.

Morphological imaging by CT angiography, MRI angiography, or arteriogram was performed in addition to the Doppler ultrasound to determine the exact TASC type of the lesion(s).

On day 1 after the intervention, blood tests were repeated, measuring the same variables as pre-intervention. Blood paclitaxel levels were measured at 24 hours after the injection. Doppler ultrasound was also performed again on day 1 post-intervention.

At 1, 6 and 12 months post-intervention, patients underwent clinical examination with the surgeon to check for complications or criteria for study withdrawal. Doppler ultrasound was performed at all 3 visits. Morphological assessment was performed again if the clinical outcome was unfavourable. At 6 months, plain X-ray of the stents was performed to search for possible stent fracture.

Endovascular procedure: All interventions were performed in the operating theatre. The type of anesthesia was left at the discretion of the anesthesiologist, depending on whether or not a simultaneous intervention to treat wounds was planned.

Patients received an intravenous bolus of heparin at a dose of 50 IU/kg once the introducer was in place. The ipsilateral or contralateral femoral approach was used, depending on where the lesion was located. The reperfusion procedure was standard,

making every attempt to remain within the lumen, with a hydrophilic guidewire and a 4 or 5 French catheter. Reperfusion was subjectively considered as sub-intimal if it was necessary to apply great force to advance the guidewire, or if the guidewire took a helical path, or if re-entry difficulties were experienced. After catheterization of the lesion, we performed pre-dilation with a 3 or 4mm balloon, and then nitinol stents were implanted. The stents were dilated to the target diameter with a non-coated balloon. The diameter chosen for the stent was the same diameter as the artery.

Paclitaxel was prepared in the central pharmacy of the hospital. The dose was extrapolated from the dose fixed on active, paclitaxel-coated stents and by calculating the lesion surface area to be treated, as described in the IRRITAX protocol, namely:

dose= 22/7 X diameter (mm) X length (mm) X 3 micrograms/mm^3

For example, for stents with a diameter of 7 mm, and a length of 30 cm, the dose of paclitaxel is approximately 20 mg. Paclitaxel was diluted to 0.75 mg/mL in NaCl 0.9%, filtered at 0.22 µm, and conditioned in syringes of 10 mL (i.e. 7.5 mg of paclitaxel per syringe). The excipients used were anhydrous ethanol and polyethoxylated castor oil.

Paclitaxel was transferred into sterile Luer-Lok syringes (Termo Fisher scientific, Waltham, USA) of 10 mL. Four mL of solution, corresponding to 3 mg of paclitaxel, were injected into each 5 cm segment of the lesion using the microporous delivery balloon. The paclitaxel solution was injected through the syringe by manual inflation. Excess solution was returned to the pharmacy for destruction.

Paclitaxel levels in the blood were measured 2 minutes after intra-arterial injection through the femoral sheath. A second blood test to measure paclitaxel levels was performed intravenously at 24 hours after injection.

Any associated interventions for trophic problems were performed at the end of the procedure.

Dual antiplatelet therapy (clopidogrel 75 mg daily and aspirin 75 mg daily) was initiated immediately after the intervention and pursued for 3 months, then clopidogrel alone was continued long-term. Patients receiving vitamin K antagonists (VKA) were given an association of VKA and aspirin 75 mg for the long term.

STATISTICAL ANALYSIS

Quantitative data are presented as median [interquartile]. Results are presented as number (percentage). The rates of restenosis, patency, TLR, TER and cumulative morbidity and mortality are given as percentages. Kaplan-Meier curves were constructed for the rates of restenosis, patency, TLR and TER.

Blood paclitaxel levels were compared between patients with vs patients without restenosis using the Mann Whitney test.

RESULTS

Study population

From March 2013 to March 2014, 15 patients met the inclusion criteria and were eligible for inclusion (9 women, 6 men, average age 77years (67-87).

Among these 15 patients, 12 were included, and 3 were not (1 had a kidney transplant, one had severe cardiac decompensation and one actually had a TASC type B lesion on pre-intervention arteriogram). Among the 12 patients included, there were 3 procedural failures, and 9 patients actually received a dose of paclitaxel, and comprised the final study population. There were 5 women and 4 men, average age was 77 years (67-87). See the Flow Chart in Figure 1.

The characteristics and comorbidities of the study population are presented in Table 1,2. All 9 patients were followed up to one year; no patient was lost to follow-up.

The lesions were located on the superficial femoral artery in 6, and the superficial femoral and popliteal artery in 3 cases. There were 8 occlusions and 1 stenosis. No patient underwent dilation of another vascular site during the same procedure.

Endovascular procedure

Six patients underwent intervention with local anesthesia and neuroleptanalgesia, and 3 patients had loco-regional anesthesia. The antegrade approach was used in all cases, with ipsilateral puncture in 4, and 5 cross-overs. The average length of the lesions treated was 352 mm (of 200 mm to 420 mm), and an average of 2.7 stents were implanted per patient. In the cases with thrombosis, reperfusion was subintimal in 4 cases, and intraluminal in 4 cases. Two patients had toe amputation at the end of the procedure.

The average dose of paclitaxel injected was 22.79 mg, requiring the balloon to be moved on average 7 times. There were no technical complications with regard to the use of the drug or its local delivery.

The average dose of paclitaxel in the blood was 1700 ng/mL at 2 minutes, and 3.6 ng/mL at 24 hours.

With these 2 findings, we can estimate that the dose delivered to the vessel wall was 2856 ng/ml.

Primary endpoint

We observed 5 cases of thrombosis and 2 cases of restenosis during the 12 months of follow-up, yielding a restenosis rate of 78%. The Kaplan-Meier curve of restenosis-free survival up to 12 months is presented in Figure 1.

These patients required 3 repeat angioplasties, 2 bypasses and 1 fibrinolysis, leading to a TLR of 67% at 1 year. One patient did not undergo repeat intervention because the restenosis was asymptomatic. The Kaplan-Meier curve up of TLR-free survival up to 12 months is presented in Figure 2.

The rates of primary and secondary patency were respectively 22% and 89% at 1 year. One patient who had repeat angioplasty suffered repeat thrombosis of the popliteal artery as an immediate complication. This female patient was very elderly and had chronic wounds that caused little pain, and was thus followed-up with watchful waiting and had no repeat intervention up to 1 year. The Kaplan-Meier curve describing maintenance of primary and secondary patency is presented in Figure 3.

No patient underwent revascularisation of another site during the same procedure, giving a TER of 0% at 1 year. No

Table 1: Baseline characteristics and comorbidities of the study population (n=9).

	n (%)
Smoking status	4 (44 %)
Current	1 (11 %)
Former	3 (33 %)
Hypertension	7 (78 %)
Dyslipidemia	4 (44 %)
Diabetes	4 (44 %)
Renal insufficiency	4 (44 %)
Dialysis	1 (11 %)
History of coronary artery disease	2 (22 %)
History of revascularization of the treated limb	1 (11 %)
Clinical stage	
Ischemic rest pain	0
Tissue loss	9 (100 %)

Table 2: Lesions and endovascular procedure characteristics.

Type of lesions	
Occlusion	8
Stenosis	1
Localization of lesions	
SFA	6
SFA and popliteal artery	3
Average length of the stented segment	322 mm
Average number of stents	2,7
Number of patent leg artery	
1	4
2	3
3	2

adverse paclitaxel-related effects were observed. Limb salvage rate was 100%, and 3 patients' wounds were completely healed at 1 year (33%).

The cumulative morbidity and mortality was 0%.

Paclitaxel levels in the blood could not be compared because of the small number of patients with no restenosis (n=2).

DISCUSSION

Local delivery of paclitaxel using a microporous balloon as a means to limit the risk of restenosis after long stenting of the SFPA in patients with CLI is feasible and safe, but does not appear to be efficacious. This lack of efficacy could be related to the method of delivery, the drug itself, or the type of lesions.

The use of a microporous catheter to deliver a drug to the arterial wall was first demonstrated in 1990 [14]. Since then, this type of catheter has successfully been used by many other teams[15]. Numerous recent studies have shown the benefit of active stents on restenosis, but most included short lesions of the superficial femoral artery [11,16-19]. Indeed, almost all the studies included lesions <18 cm, with an average of around 6 to 8cm. This could be explained by the fact that currently, only short balloons (up to 150 mm) are available, thus requiring the use of several balloons for the treatment of long lesions. This raises several challenges, such as the cost per patient, the risk of toxicity, and the absence of marketing authorization for this indication. Furthermore, in studies to date, the patient populations were heterogeneous, with a low level of disease severity (Rutherford class 2 to 4). Only the BIOLUX P-I and LEVANT I studies included patients in Rutherford class 5 [11,17]. The lesions in studies to date were also heterogeneous (*de novo* and restenosis), with <50% thrombosis, and certain lesion types were excluded (e.g. heavily calcified lesions). Finally, only the study by Micari et al., included TASC C and D lesions [20]. In their study, Micari et al., included 105 patients with lesions >15cm (251 ± 71 mm), with almost 50% being total occlusions. Only 11% of patients underwent stent implantation, and primary patency at one year was 83%. No patient had trophic disorders. In our study, all patients had

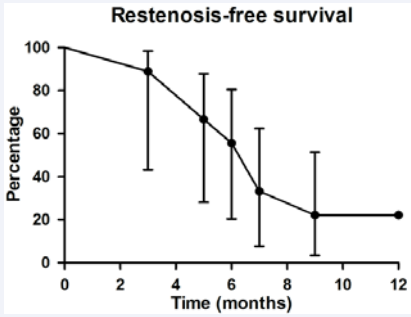

Figure 1 Kaplan-Meier curve for restenosis-free survival with IC 95 %.

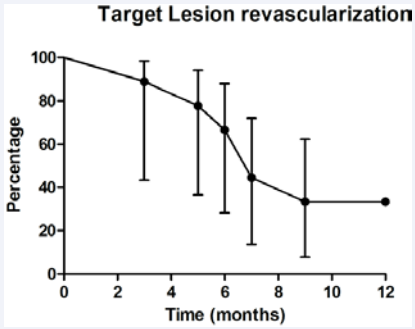

Figure 2 Kaplan-Meier curve for target lesion revascularization with IC 95%.

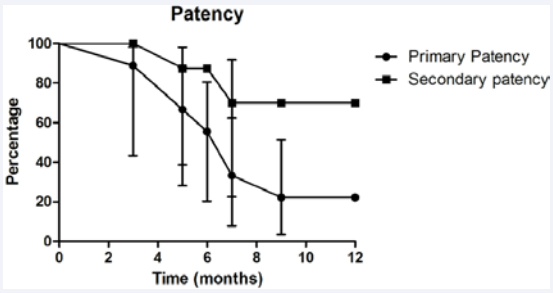

Figure 3 Kaplan-Meier curve for patency with IC 95 %.

CLI with longer lesions, and 90% had occlusion. Stenting was systematic in our study. Conversely, our results are in line with those of the STELLA-PTX registry, in which Davaine et al reported that paclitaxel-eluting stents did not achieve their goal in terms of prevention of in-stent restenosis for TASC C/D femoropopliteal lesions [21]. Our study presents the advantage of being a more homogeneous group of patients, with well-defined lesions, and is the only study, to the best of our knowledge, to investigate the efficacy of paclitaxel injected directly after stenting for *de novo* lesions. Published studies to date often used the active balloon after first performing pre-dilation, and the stenting rate was generally low, at less than 20%.

Furthermore, in our study, paclitaxel was delivered directly intra-stent over the full length of the lesion, without any possibility of medication being lost during manipulation of the balloon between the puncture site and the target lesion. This mode of local delivery is therefore theoretically more reproducible and better controlled. We also measured paclitaxel levels in the blood, which has rarely been done in other studies heretofore [11]. Conversely, there are some pre-clinical studies that have evaluated the impact of paclitaxel administration on the vessel wall in the femoral or iliac arteries [8,22,23]. The measurements performed in our study only allow indirect evaluation of the level of paclitaxel delivered within the artery. Indeed, we were able to ascertain the average dose injected (22.79 mg, corresponding to 4556 ng/mL for volemia of 5 L), and the average circulating dose at 2 minutes (1700 ng/mL), so we can estimate that the dose delivered to the vessel wall was 2856 ng/mL. A study of an animal model of a paclitaxel-coated stent reported rapid delivery of paclitaxel, which remained detectable in the vessel wall up for the 56 days of the study [13]. The stents contained between 220 and 880 µg of paclitaxel. In our study, the total dose was 26 times greater, taking into account the length of the treated segments (22 790 µg vs 880 µg). The maximal arterial concentration was observed 30 minutes after implantation [13]. Measurement of the circulating levels of paclitaxel in the blood were performed at 20 minutes in two cases (versus at 2 minutes in our study), and showed levels substantially lower (at 6.0 ng/mL) than those observed in our study. This could be explained by superior local drug delivery with coated stents [13]. The animal study by Yasdani et al., reported paclitaxel levels in the vessel wall, that were quite similar to those obtained with coated stents [24]. In their study, the length of the balloon and the total dose of paclitaxel carried by the balloon were not clearly indicated, except in a subgroup in which several balloons were used in 2 vessels of the same limb, with a total dose of paclitaxel of 21.5 ± 8mg, which is quite similar to that of our study [24]. However, it is not possible to extrapolate results from animal studies performed in healthy arteries to the context of atherosclerotic and calcified human arteries. In particular, the quantity of paclitaxel that spreads in a severely calcified artery remains unknown. It is also difficult to determine whether a calcified arteries still have the potential for intimal and smooth muscle cell proliferation. After the administration of paclitaxel, re-endothelialisation plays an important role. At low doses, endothelial cells are inhibited less than muscle cells, whereas at higher doses, the proliferation of both cell types is inhibited (8). We therefore propose several hypotheses that may explain the lack of efficacy of local paclitaxel delivery using a microporous balloon. Firstly, paclitaxel is not delivered in the vessel wall. The size of the pores, ranging from 2 to 50 µm, is sufficient to allow infusion of paclitaxel out of the balloon [25]. Paclitaxel is known for its adhesion property, but in the experimental study by Anderson et al [25], which tested cremophor-paclitaxel as used in our study, the adsorption of the drug on the balloon was negligible. Conversely, paclitaxel demonstrates significant adsorption on the balloon when other excipients are used, such as urea or iodixanol. Differences in experimental protocols between studies preclude comparison of the findings across studies. The use of the albumin-bound paclitaxel nanoparticle Abraxane® (130 nm) showed superior uptake into the tissue, but cremophor-paclitaxel and Abraxane® inhibited the growth of both smooth muscle cells and endothelial cells, which could comprise vessel wall healing [25,26]. Insufficient apposition of the balloon to the vessel wall could also explain the poor infusion in the wall, and it may be useful to over-size the microporous balloon with respect to the artery. Different pressure conditions and infusion durations could impact on the quantity of paclitaxel delivered, as well as on the depth of penetration [9,25]. In our study, we manually injected paclitaxel in order to precisely control the quantity. However, this method of delivery does not allow control of the pressure, and thus, of the depth of penetration into the vessel wall. It is also possible that the efficacy of paclitaxel could be different depending on whether the intraluminal or subintimal approach is used. It is often difficult to ascertain whether recanalization is intraluminal or subintimal. In our study, we chose to deliver paclitaxel after performing stenting of the lesions. It is therefore plausible that the delivery of paclitaxel was reduced by the nitinol. Performing pre-dilation, followed by paclitaxel then stent implantation might conceivably yield better results. Indeed, systematic stenting is also a debatable approach. However, to the best of our knowledge, no study has shown the superiority of balloon angioplasty of angioplasty with stent implantation in this indication. We therefore do not believe that the systematic stenting can explain high rate of restenosis.

Finally, contrary to many previous studies, our patients had trophic disorders. The resulting inflammatory syndrome likely played a role in the rate of restenosis [27].

As regards the safety, our results are in line with previous literature reports, which have failed to show any toxic effect of paclitaxel at the dose used [3,11-13].

The high rate of restenosis in our study should not discourage the use of a microporous balloon for the local delivery of anti-proliferative drugs, but the method of delivery, as well as the excipients (nanoparticles) need to be further refined. One of the advantages of this technique is to deliver a precise dose of the drug to the vessel wall, contrary to coated balloons, which lose an unquantifiable amount of drug during navigation of the balloon towards the lesion site. Finally, the use of the paclitaxel requires the use of an excipient, of which some such as urea, have been shown to be potentially toxic to cells [25].

The main limitation of our study is the small sample size. However, the ability to recruit eligible patients and successfully perform local delivery of paclitaxel was one of the objectives of this pilot study. The low number of patients included over a one-year period, the complexity of the protocol, as well as

the high level of restenosis at one year suggest that a larger, multicenter study in this indication may not successfully achieve sufficient patient accrual. Pilot studies are useful to verify the capacity to successfully recruit sufficient numbers of patients, calculate a sample size for a larger study, and test the logistics of the protocol [28,29]. In the case at hand, many patients were excluded, because they were often admitted in emergency situations that precluded successful performance of the complex logistics required by the study protocol. For some other patients, the operator failed to cross the lesion. Finally, a significant proportion of patients had cancer or other concomitant diseases that precluded their inclusion, or that were associated with a life-expectancy of less than 12 months. All these factors combine to illustrate the potential barriers to recruitment for a larger, multicenter randomized trial.

CONCLUSION

Local delivery of paclitaxel as performed in this study does not appear to improve the results of endovascular treatment of long lesions of the SFPA in a population of patients with critical limb ischemia. We nonetheless believe that this technique could be further refined and improved, particularly through the use of nanoparticles of paclitaxel or sirolimus, with a view to further testing in new studies.

REFERENCES

1. Norgren L, Hiatt WR, Dormandy JA, Nehler MR, Harris KA, Fowkes FG, et al. Inter-society consensus for the management of peripheral arterial disease. J Vasc Surg. 2007; 45: 81-157.
2. Schillinger M, Sabeti S, Dick P, Amighi J, Mlekusch W, Schlager O, et al. Sustained benefit at 2 years of primary femoropopliteal stenting compared with balloon angioplasty with optional stenting. Circulation. 2007; 115: 2745-2749.
3. Tepe G, Zeller T, Albrecht T, Heller S, Schwarzwälder U, Beregi JP, et al. Local delivery of paclitaxel to inhibit restenosis during angioplasty of the leg. N Engl J Med. 2008; 358: 689-699.
4. Mauri L, Silbaugh TS, Wolf RE, Zelevinsky K, Lovett A, Zhou Z, et al. Long-term clinical outcomes after drug-eluting and bare-metal stenting in Massachusetts. Circulation. 2008; 118: 1817-1827.
5. Cassese S, Byrne RA, Ott I, Ndrepepa G, Nerad M, Kastrati A, et al. Paclitaxel-coated versus uncoated balloon angioplasty reduces target lesion revascularization in patients with femoropopliteal arterial disease: a meta-analysis of randomized trials. Circ Cardiovasc Interv. 2012; 5: 582-589.
6. Dake MD, Ansel GM, Jaff MR, Ohki T, Saxon RR, Smouse HB, et al. Paclitaxel-eluting stents show superiority to balloon angioplasty and bare metal stents in femoropopliteal disease: twelve-month Zilver PTX randomized study results. Circ Cardiovasc Interv. 2011; 4: 495-504.
7. Gershlick AH. Drug eluting stents in 2005. Heart Br Card Soc. 2005; 91: 24-31.
8. Axel DI, Kunert W, Göggelmann C, Oberhoff M, Herdeg C, Kuttner A, et al. Paclitaxel inhibits arterial smooth muscle cell proliferation and migration *in vitro* and *in vivo* using local drug delivery. Circulation. 1997; 96: 636-645.
9. Alfke H, Wagner HJ, Calmer C, Klose KJ. Local intravascular drug delivery: *in vitro* comparison of three catheter systems. Cardiovasc Intervent Radiol. 1998; 21: 50-56.
10. Latif F, Hennebry TA. Successful revascularization of re-stenosis of lower extremity arteries with localized delivery of paclitaxel. Catheter Cardiovasc Interv. 2008; 72: 294-298.
11. Scheinert D, Duda S, Zeller T, Krankenberg H, Ricke J, Bosiers M, et al. The LEVANT I (Lutonix paclitaxel-coated balloon for the prevention of femoropopliteal restenosis) trial for femoropopliteal revascularization: first-in-human randomized trial of low-dose drug-coated balloon versus uncoated balloon angioplasty. JACC Cardiovasc Interv. 2014; 7: 10-19.
12. Damascelli B, Patelli GL, Lanocita R, Di Tolla G, Frigerio LF, Marchianò A, et al. A novel intraarterial chemotherapy using paclitaxel in albumin nanoparticles to treat advanced squamous cell carcinoma of the tongue: preliminary findings. AJR Am J Roentgenol. 2003; 181: 253-260.
13. Dake MD, Van Alstine WG, Zhou Q, Ragheb AO. Polymer-free paclitaxel-coated Zilver PTX Stents--evaluation of pharmacokinetics and comparative safety in porcine arteries. J Vasc Interv Radiol. 2011; 22: 603-610.
14. Wolinsky H, Thung SN. Use of a perforated balloon catheter to deliver concentrated heparin into the wall of the normal canine artery. J Am Coll Cardiol. 1990; 15: 475-481.
15. Gonschior P, Pahl C, Huehns TY, Gerheuser F, Erdemci A, Larisch K, et al. Comparison of local intravascular drug-delivery catheter systems. Am Heart J. 1995; 130: 1174-1181.
16. Laird JR, Schneider PA, Tepe G, Brodmann M, Zeller T, Metzger C, et al. Durability of Treatment Effect Using a Drug-Coated Balloon for Femoropopliteal Lesions: 24-Month Results of IN.PACT SFA. J Am Coll Cardiol. 2015; 66: 2329-2338.
17. Scheinert D, Schulte K-L, Zeller T, Lammer J, Tepe G. Paclitaxel-releasing balloon in femoropopliteal lesions using a BTHC excipient: twelve-month results from the BIOLUX P-I randomized trial. J Endovasc Ther. 2015; 22: 14-21.
18. Rosenfield K, Jaff MR, White CJ, Rocha-Singh K, Mena-Hurtado C, Metzger DC, et al. Trial of a Paclitaxel-Coated Balloon for Femoropopliteal Artery Disease. N Engl J Med. 2015; 373: 145-153.
19. Tepe G, Schnorr B, Albrecht T, Brechtel K, Claussen CD, Scheller B, et al. Angioplasty of femoral-popliteal arteries with drug-coated balloons: 5-year follow-up of the THUNDER trial. JACC Cardiovasc Interv. 2015; 8: 102-108.
20. Micari A, Vadalà G, Castriota F, Liso A, Grattoni C, Russo P, et al. 1-Year Results of Paclitaxel-Coated Balloons for Long Femoropopliteal Artery Disease: Evidence From the SFA-Long Study. JACC Cardiovasc Interv. 2016; 9: 950-956.
21. Davaine JM, Querat J, Kaladji A, Guyomarch B, Chaillou P, Costargent A, et al. Treatment of TASC C and D Femoropoliteal Lesions with Paclitaxel eluting Stents: 12 month Results of the STELLA-PTX Registry. Eur J Vasc Endovasc Surg. 2015; 50: 631-637.
22. Gongora CA, Shibuya M, Wessler JD, McGregor J, Tellez A, Cheng Y, et al. Impact of Paclitaxel Dose on Tissue Pharmacokinetics and Vascular Healing: A Comparative Drug-Coated Balloon Study in the Familial Hypercholesterolemic Swine Model of Superficial Femoral In-Stent Restenosis. JACC Cardiovasc Interv. 2015; 8: 1115-1123.
23. Fernández-Parra R, Laborda A, Lahuerta C, Lostale F, Aramayona J, de Blas I, et al. Pharmacokinetic Study of Paclitaxel Concentration after Drug-Eluting Balloon Angioplasty in the Iliac Artery of Healthy and Atherosclerotic Rabbit Models. J Vasc Interv Radiol. 2015; 26: 1380-1387.
24. Yazdani SK, Pacheco E, Nakano M, Otsuka F, Naisbitt S, Kolodgie FD, et al. Vascular, downstream, and pharmacokinetic responses to treatment with a low dose drug-coated balloon in a swine femoral artery model. Catheter Cardiovasc Interv. 2014; 83: 132-140.

25. Anderson JA, Remund T, Pohlson K, Lamichhane S, Evans C, Evans R, et al. *In vitro* and *in vivo* evaluation of effect of excipients in local delivery of paclitaxel using microporous infusion balloon catheters. J Biomed Mater Res B Appl Biomater. 2017; 105: 376-390.

26. Granada JF, Tellez A, Baumbach WR, Bingham B, Keng YF, Wessler J, et al. *In vivo* delivery and long-term tissue retention of nano-encapsulated sirolimus using a novel porous balloon angioplasty system. EuroIntervention. 2016; 12: 740-747.

27. Hsieh IC, Chen CC, Hsieh MJ, Yang CH, Chen DY, Chang SH, et al. Prognostic Impact of 9-Month High-Sensitivity C-Reactive Protein Levels on Long-Term Clinical Outcomes and In-Stent Restenosis in Patients at 9 Months after Drug-Eluting Stent Implantation. PLoS One. 2015; 10: e0138512.

28. Thabane L, Ma J, Chu R, Cheng J, Ismaila A, Rios LP, et al. A tutorial on pilot studies: the what, why and how. BMC Med Res Methodol. 2010; 10: 1.

29. Arain M, Campbell MJ, Cooper CL, Lancaster GA. What is a pilot or feasibility study? A review of current practice and editorial policy. BMC Med Res Methodol. 2010; 10: 67.

Cite this article

Schiava ND, Naudin I, Bordet M, Arsicot M, Tresson P, et al. (2018) STREAMER (STentREstenosisAndMEdication Release): Failure of Local Delivery of Paclitaxel for the Prevention of Restenosis in Stenting of TASC C-D Femoropopliteal Segment. JSM Atheroscler 3(1): 1042.