

Research Article

Oral Administration of Forskolin and Rutin Contributes to Reduce Intraocular Pressure and Improve PERG (Pattern Electroretinogram) Amplitude in Glaucomatous Patients

Dario Sisto¹, Nicola Lavermicocca², Donato Errico³ and Dario Rusciano^{4*}

¹Department of Ophthalmology, Ospedale G Tatarella, Italy

²Department of Ophthalmology, Ospedale S. Maria Degli Angeli, Italy

³Department of Ophthalmology, Ospedale Cardinale Giovanni Panico, Italy

⁴Sooft italia SpA, Via Salvatore Quasimodo, Italy

***Corresponding author**

Dario Rusciano, Sooft italia SpA, Via Salvatore Quasimodo 136, 00144 Roma, Italy, Tel: +39 06 83766253; Fax: +39 06 83766793; Email: dario.rusciano@sooft.it

Submitted: 26 June 2014

Accepted: 07 August 2014

Published: 09 August 2014

ISSN: 2333-7117

Copyright

© 2014 Rusciano et al.

OPEN ACCESS**Keywords**

- Glaucoma
- IOP
- Forskolin
- Neuroprotection
- Pattern electroretinogram

Abstract

Purpose: The goal of this study was the clinical evaluation of the neuroprotective properties of a dietary supplementation of forskolin, rutin and vitamins B1 and B2 on retinal ganglion cell activity. To this purpose, we focused both on IOP and the Pattern Electroretinogram (PERG). PERG is known to be significantly altered in glaucoma, and a decrease of PERG signal amplitude is an early sign of glaucoma progression.

Methods: 45 patients affected by POAG were evaluated in this study. Patients were randomly divided into 2 groups: Group A: 30 patients (60 eyes) with IOP compensated by topical pharmacological treatment, and taking the neuroprotective food supplement. Group B: 15 patients (30 eyes) treated with hypotonizing drugs alone. IOP and PERG were evaluated in both groups at enrolment (T0), and after 2 (T1), 4 (T2) and 6 (T3) months.

Results: In group A, IOP significantly decreased from 15.6 mmHg (T0) to 14.6 (T1), 14.5 (T2) and 14.6 (T3) mmHg, while no differences were found in the control group B. As concerns PERG, while latency remained unchanged in both groups, we observed in group A – but not in group B – a progressive increase of amplitude from 3.4 μ V (T0) to 3.6 (T1), 4.3 (T2), and 4.8 (T3) μ V, achieving statistically significant differences at T2 and T3.

Conclusion: The results of the present clinical pilot study suggest a short-term neuroactive effect of the food supplement, as evidenced by the improvement of PERG amplitude in treated, but not in control patients.

ABBREVIATIONS

POAG: Primary Open Angle Glaucoma; RGC: Retinal Ganglion Cells; IOP: Intraocular Pressure; BDNF: Brain-Derived Neurotrophic Factor; CNTF: Ciliary Neurotrophic Factor; TrkB: Tropomyosin-Related Kinase B; cAMP: Cyclic Adenosine Monophosphate; AH: Aqueous Humor

INTRODUCTION

Primary Open Angle Glaucoma (POAG) is a progressive neuropathy of the optic pathway, characterized by loss of Retinal

Ganglion Cells (RGC), cupping of the optic nerve head and visual field deficits [1,2]. Elevated Intraocular Pressure (IOP) is the main risk factor for development and progression of POAG [3], although it is no longer considered a peculiar characteristic of the disease [4–8]. Impaired ocular blood flow is another possible cause contributing to glaucoma development and/or progression, especially when IOP is apparently normal [9].

It is increasingly documented that a neurodegenerative cascade occurs in all POAG patients, even those with normal IOPs [10]. Neurodegeneration in glaucoma is related to progressive

death of retinal ganglion cells (RGCs) and their axons, resulting in optic nerve atrophy and, ultimately, vision loss [11-17]. Histological studies have described a selective loss of RGCs and their axons in glaucomatous patients and roughly 1/3 of RGCs is already lost, when visual field defects become apparent in automated visual field testing [18].

Without some form of intervention, RGC death in glaucoma is fatally progressive [13,14]. Therefore, a synergistic therapeutic approach appears necessary, aimed not only at reducing IOP, but also at avoiding progression of the neurodegenerative events.

Similarly to other neurodegenerative disorders, several factors contribute to neurodegeneration in patients with glaucoma. Many authors have reported that disruption of axonal transport of neurotrophins, caused by either vascular ischemia or by mechanical compression, occurs in glaucoma [17,19]. Neurotrophins are essential for cell survival and axon regeneration, and RGCs fail to regenerate in their absence [20,21]. RGC loss can be delayed by application of neurotrophic factors such as Brain-Derived Neurotrophic Factor (BDNF) or ciliary neurotrophic factor (CNTF) [22,23].

Several studies have shown that the binding of BDNF to its receptor tropomyosin-related kinase B (TrkB), is important for RGC survival and axon regeneration [24,25], but BDNF cannot promote long-term survival *in vivo*, because of the down-regulation of TrkB further to cognate ligand binding [26,27]. In this regard, the elevation of cyclic adenosine monophosphate (cAMP) can enhance RGC response to BDNF, thus promoting survival and axon growth [28,29].

Nonetheless, IOP still remains the main, if not the only, target for the pharmacologic treatment of this disease [3,30,31]. The first therapeutic approach still relies on the administration of hypotensive eye drops, with the intent of lowering IOP to a target value generally 20%–30% lower than the presenting value [6]. However, some patients may either initially be, or become, unresponsive to some of these drugs so that different combinations of them are required to maintain IOP at the desired value [7,8].

Forskolin is a natural compound extracted from the roots of the Indian Coleus plant (*Coleus Forskohlii*) [32]. It is a receptor-independent adenylate-cyclase activator, so that the concentration of the second-messenger cAMP rapidly increases in forskolin-stimulated cells [33,34]. Human non-pigmented ciliary epithelial cells have been shown to contain adenylate-cyclase (subtypes II and IV), the activity of which contributes to the regulation of aqueous humor (AH) dynamics [3]. Forskolin treatment results in a reduced rate of aqueous secretion (and, consequently, IOP) from the ciliary epithelium in response to activation of adenylate-cyclase [30,31], that may explain the hypotensive effect of topical administration of forskolin, as shown in humans [30] and experimental animals [35,36]. Moreover, forskolin-mediated activation of cAMP may contribute to neuronal cell survival and growth, by stimulating the paracrine circuit involving the neurotrophin BDNF and its receptor TrkB [37-40].

However, glaucomatous neurodegeneration is a multifactorial process that includes oxidative stress as a main contributor in the promotion of *apoptotic RGC death* [14,15].

In this regard, flavonoids are a large family of compounds derived from vegetables and fruits [41], which have shown antioxidant and neuroprotective activities in different neurodegenerative disorders [42,43]. In particular, some studies have described the potential protective effects of flavonoids on RGC degeneration [44,45].

Rutin is a natural bioflavonoid that has been shown to improve ocular blood flow and electroretinogram recovery in experimental glaucoma models [32,33]. It has a free radical scavenging activity and may thus protect sensitive cells from ischemia/reperfusion damage [34], as may happen during retinal vein occlusion, or suddenly elevated IOP.

It is known that vitamin B1 and B2 deficiency can affect the tissues of the eye. The recent Rotterdam study, a prospective population-based cohort of 3502 participants, showed that a low intake of retinol equivalents and vitamin B1 appears to be associated with an increased risk of open-angle glaucoma [46].

Vitamin B2 deficiency is associated with cataract [47]; this vitamin preserves levels of glutathione, the major endogenous antioxidant which, in turn, neutralizes detrimental compounds such as free radicals and reactive oxygen, that, as mentioned above, are implicated in apoptotic death of RGCs [14,15].

A food supplement is commercially available in Italy, containing 150 mg of *coleus forskohlii* extract titrated at 10% in forskolin, and enriched with rutin (200 mg) and vitamins B1 (0.55 mg) and B2 (0.7 mg) (Kronek®, SOOFT Italia). Such a food supplement would then deliver 15 mg of forskolin in each tablet.

The goal of this study was to evaluate the neuroprotective properties of Kronek on RGCs in glaucoma. To this purpose, we focused on tonometry and Pattern Electroretinogram (PERG), a recognized clinical tool proposed to monitor progression of glaucomatous optic neuropathy [48] through the measurement of RGC bioelectric activity. It is known that PERG is significantly altered in glaucoma patients, even before changes in the visual field become apparent [48–51].

MATERIALS AND METHODS

The research followed the tenets of the Declaration of Helsinki. Upon recruitment each patient gave informed consent. Approval was obtained from the local Ethics Committee.

Three different glaucoma centers participated in this open, prospective, and randomized case-control trial. A total of 45 POAG patients of both sexes, aged between 30 and 70 years, with IOP values ≤ 18 mmHg under therapy (beta blockers, prostaglandins, alpha-agonists or their fixed associations), and stable for at least 3 months, were included. Patients with other concomitant systemic pathologies (preventing them from taking the food supplement) or cataract, were excluded. Enrolled patients, with IOP compensated by topical therapy, took either the hypotonizing treatment plus the food supplement with Forskolin, Rutin and vitamins B1 and B2, one tablet, twice daily for 6 months (group A, 30 patients, 60 eyes), or the hypotonizing treatment alone (group B, 15 patients, 30 eyes). As endpoints, we focused on IOP and PERG that were evaluated at enrolment (T0), and then after 2 (T1), 4 (T2) and 6 (T3) months with Retimax (CSO Strumenti di talmici, Florence, Italy). At each visit, patients were

asked to return the empty used boxes of the food supplement, and inquired about any side effects.

Inclusion criteria

- Caucasian patients aged between 30 and 70 years
- No systemic pathologies or cataract
- Visual Acuity $\geq 8/10$
- Refractive defect between $-5D$ e $+3D$
- Astigmatism not beyond $\pm 1D$
- Normal corneal pachimetry (> 520 e $< 580 \mu\text{m}$)
- IOP ≤ 18 mmHg under therapy, and stable for at least 3 months
- MD worse than -6 dB at enrolment

At enrolment, IOP of all patients was measured in the morning by Goldman applanation tonometry, and the average value of 3 consecutive measurements is reported (T0).

PERG was recorded simultaneously from both eyes using ISCEV standard for clinical pattern.

Electroretinography [52] using skin electrodes that overcomes some limitations of current standard PERG techniques with corneal electrodes [53], the reproducibility of which depends on both the operator's skills and patient's compliance [54]. Moreover, PERG waveforms recorded in individual eyes are not contaminated by the responses originating from the contralateral eye, as may happen with some corneal electrodes [55,56]. HK Loop electrodes were hooked into the lower fornix. HK Loops were folded so that the contact windows on otherwise insulated wire were positioned on the bulbar conjunctiva, about 5 mm under the limbus. HK Loop electrodes did not touch the cornea. To achieve this, the limbs of the HK loop diverged widely (15–20 mm) before entering the fornix. The lead was then taped to the cheek, while reference and ground electrodes were fixed on the ipsilateral temple and the forehead, respectively.

The pattern stimulus consisted of a horizontal black and white checkerboard with a check size of 0.8° , 30° square field visual angle, 95% Michelson contrast, 40 candles/m² of mean luminance, reversed in counterphase at 2 Hz (4 reversals per second). Signals were band pass filtered (1–30 Hz), amplified (50,000 V/v), and averaged (200 sweeps). Subjects with undilated pupils were classified into a refractive group, refracted for the viewing distance (573 mm), and asked to stare on a target at the center of the stimulus.

Subjects were allowed to blink freely. Recording time was approximately 3 min. Sweeps contaminated by eye blinks or gross eye movements were automatically rejected over a threshold voltage of 25 microvolts.

Baseline PERG values were recorded at enrolment (T0), and new measurements made after 2 (T1), 4 (T2) and 6 (T3) months from baseline.

Statistics

The differences of PERG responses between groups were evaluated by a non-parametric statistics (Mann-Whiney).

Changes in PERG responses within the same group with respect to baseline were evaluated by one-way repeated measures ANOVA. In all analyses, a conservative p value less than 0.05 was considered as statistically significant.

RESULTS

Patients' demography and enrolment values are summarized in Table 1. No significant differences ($p \geq 0.05$) in PERG responses or IOP values were observed at baseline between groups, indicating their homogeneity. Control patients happened to be of somewhat younger age than treated patients, but this is not expected to influence progression or compliance to treatment. No cases of intolerance or any other side effects due to the food supplement intake were reported, and no drop-off of patients occurred: all the enrolled patients completed the study protocol.

Figure 1a shows that the IOP decreased in group A patients from 15.6 mmHg (T0) to 14.6 (T1), 14.5 (T2) and 14.6 (T3) mmHg. The difference at each further time-point was statistically significant with respect to T0. No such differences were evident for the control group B (Figure 1b).

Figure 2 illustrates the variations of latency and amplitude PERG values for both treated and control groups. Group A patients showed a stable P50 peak time, whereas the P50-N95 peak amplitude increased from 3.4 μV (T0) to 3.6 (T1), 4.3 (T2), and 4.8 (T3) μV , achieving statistically significant differences at T2 and T3 (Figure 2a). In group B, there was no statistically significant trend of improvement (Figure 2b) of the P50-N95 amplitude.

DISCUSSION

RGC degeneration is the key hallmark of POAG [11–18]. Therefore, a major goal of neuroprotection for POAG treatment is the prevention or at least the delay of RGC death through the use of specific agents that might rescue and/or promote regeneration of already compromised RGCs.

In this paper, we used PERG analysis to obtain a direct and objective measure of RGC activity. In fact, it is known that PERG is sensitive to early RGC dysfunction caused by ocular hypertension and early glaucoma even before changes of the ONH structure or the visual field tests are apparent [48–51].

The obtained results of this clinical pilot study clearly indicate that oral treatment of tonometrically compensated POAG patients with an association of forskolin, rutin and vitamins B1 and B2 was able to further decrease IOP (Figure 1a) and improve, in the

Table 1: Patients' demography and enrolment values.

	Treated	Controls
Number	30	15
Mean age	60.3 \pm 10.7	51.1 \pm 12
Male/female	16/14	9/6
IOP	15 \pm 1.7	16.4 \pm 1.7
PERG Latency (msec)	48.9 \pm 4.4	50.4 \pm 5.8
PERG Amplitude (μV)	3.3 \pm 2.2	3.6 \pm 1.6

Abbreviations: msec: Milliseconds; μV : Microvolts

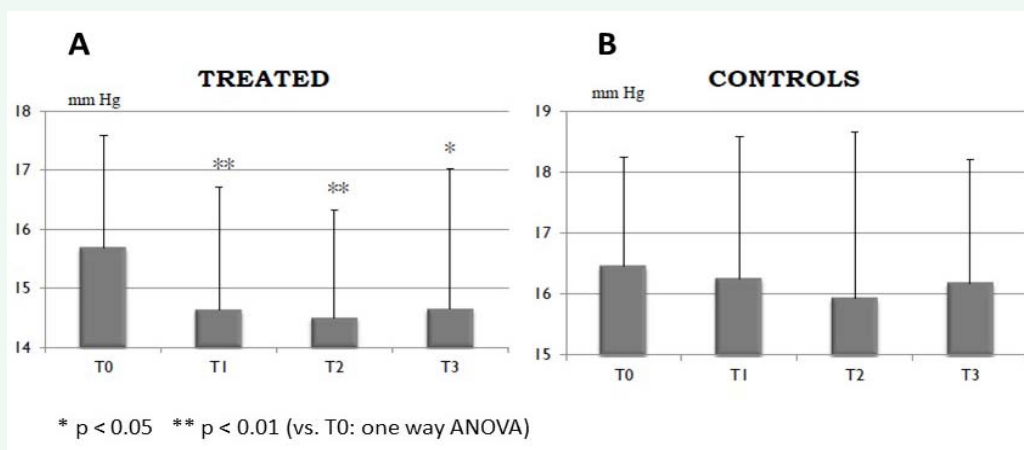


Figure 1 IOP values (mmHg) at enrolment (T0), and after 2 (T1), 4 (T2) and 6 (T3) months in treated (a) and control (b) POAG patients. # p<0.05; ## p<0.01(vs. T0: Student's t test).

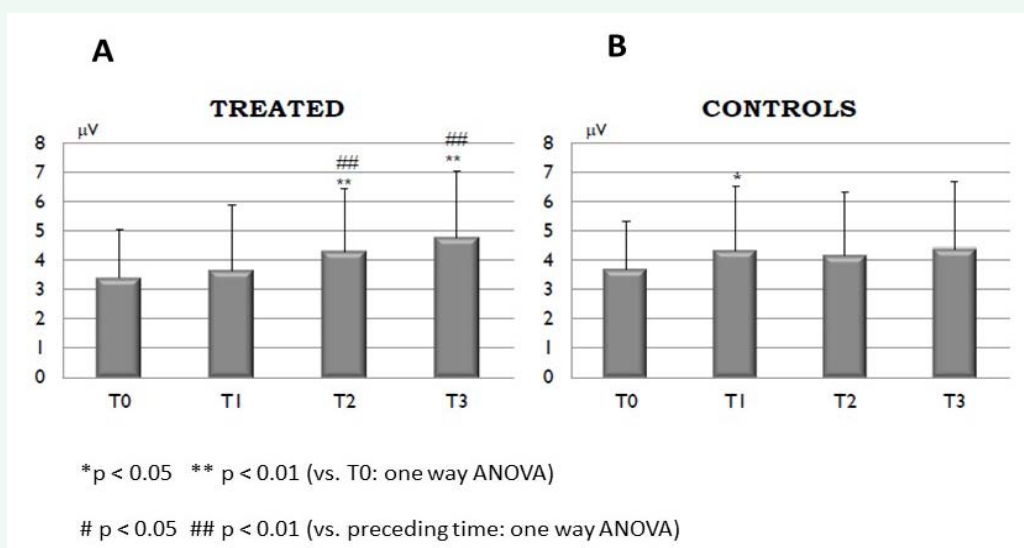


Figure 2 PERG amplitude (µV) at enrolment (T0), and after 2 (T1), 4 (T2) and 6 (T3) months in treated (a) and control (b) POAG patients. # p<0.05; ## p<0.01(vs. T0: Student's t test).

short-term (3 and 6 months), the PERG amplitude signal (Figure 2a), as shown by the increased P50-N95 amplitude.

None of the above effects were ever evident in the control group taking the hypotonizing treatment alone (Figures 1b and 2b).

The treatment group showed no differences in the latency of the P50-N95 wave (Table 1), in accordance with several literature data reporting that it is mostly the PERG amplitude that is significantly reduced in early glaucoma [57-59].

Accordingly, Parisi *et al.* correlated the improvement of the PERG signal after treatment of POAG patients with the potential neuroprotective compound cytidine-5'-diphosphocholine (citicoline), to the improvement of their retinal function [60].

The effect of forskolin could be truly neuroprotective, considering that all the patients had good IOP control (<

18 mmHg) before entering the study, and that the further IOP-lowering effect, around 1 mmHg, (Figure 1a), although statistically significant, should not be considered clinically relevant, according to the AGIS data [61]. Indeed, these effects on IOP were expected, on the basis of several clinical reports already showing the complementary effects of forskolin treatment with different hypotonizing drugs, or their different associations [62,63].

This low but significant IOP decrease has little meaning by itself in the control of IOP and neurodegeneration, but is an important marker of the actual presence of the forskolin molecule in the eye, where it can exert its neuroprotective activity.

Since IOP is only one among a number of different risk factors, the beneficial effects of the forskolin/rutin association on RGC function, as evaluated by PERG recordings, may be due to several mechanisms.

Many diverse factors can contribute to glaucomatous neurodegeneration, among which is the disruption of the axonal transport of neurotrophins [17,19–23]; the neuroprotective activity of forskolin could probably involve the modulation of neurotrophin/growth factor signaling, and in particular of BDNF signaling. Several studies have shown that the binding of BDNF to its receptor TrkB is important for RGC survival and axon regeneration [24,25]. Forskolin promotes the survival of retina neurons through the induction of BDNF mRNA, and of primary cultures of cortical neurons by stimulating the expression of both the full-length and truncated TrkB isoforms [64].

Moreover, forskolin has been shown to protect Neuro 2A neuronal cells from a surrogate of the organophosphate chemical warfare agents, soman and sarin [65], and to attenuate the adverse effects of long-term Schwann cell denervation on peripheral nerve regeneration *in vivo* [66], consistent with its property to modulate neurotrophin signaling.

It is known that forskolin raises levels of cAMP through the induction of enzyme adenylate cyclase [67,68], and the modulation of BDNF signaling could be mainly linked to this activity.

Embryonic and postnatal RGCs exhibited almost no responsiveness to peptide trophic factors unless their intracellular cAMP was simultaneously elevated [28] and BDNF does not promote long-term survival *in vivo*, as a result of the down-regulation of TrkB, following binding of BDNF [26,27]. In this regard, the elevation of cAMP can enhance the RGC response to BDNF for survival and axon growth [28,29]. cAMP increase, acting through the cAMP response element binding protein-activated transcription factor, can potentiate the neurotrophin BDNF signal cascade either by blocking BAX/BAD pro-apoptotic signals or up-regulating anti-apoptotic BCL-2 expression [69], and can rapidly recruit TrkB to the plasma membrane of CNS neurons [39].

As for the neuroprotective activity of rutin on RGC function, it is reasonable to suppose it involves oxidative stress control. Oxidative stress has been implicated in many types of ocular diseases and can contribute to glaucomatous neurodegeneration, causing *apoptotic cell death* of RGCs [14,15]. Rutin has been shown to possess a strong antioxidant activity [70–73], and to be a good neuroprotective agent *in vitro* and *in vivo* [74–76]. In a recent work, rutin was demonstrated to protect RGCs from hypoxia-, glutamate- or oxidative stress, inhibiting both apoptotic and necrotic pathways, by the suppression of caspase-3 and calpain activities, respectively [77]. Along the same line, Falsini *et al.* reported a modest beneficial effect on PERG amplitude values of another flavonoid with antioxidant properties, epigallocatechin gallate, given for 3 months as dietary supplementation to POAG patients [78]. Moreover, rutin has vasoactive properties and improves ocular blood flow [79,80].

CONCLUSION

In conclusion, the results of the present clinical study suggest a neuroactive effect of forskolin and rutin supplementation evidenced by PERG analysis on RGC function.

To date, IOP is still the main risk factor contributing to the initiation and progression of glaucoma, but in several

cases, glaucoma may continue to progress despite good IOP management. Therefore, neuroprotection appears to be a valid complementary strategy to treat glaucoma patients. A better and deeper understanding of the molecular mechanisms involved in the control of the IOP and the survival of RGC, as detailed in the discussion above, should help in identifying new targets for both a more efficient IOP control and for neuroprotection.

However, long-term clinical studies evaluating the progression of glaucomatous disease with standard diagnostic procedures also including visual field analyses are needed to confirm the potential use of forskolin and rutin supplementation as neuroprotective agents to complement the hypotensive therapy of glaucoma.

ACKNOWLEDGEMENT

The authors wish to thank Dr Antony Bridge wood for critical proofreading of the manuscript.

Conflict of interest

D. Sisto, N. Lavermicocca, D. Errico declare that no competing financial interests exist. D. Rusciano is an employee of Sooft italia SpA, the producer of the food supplement used in this study.

REFERENCES

1. Agarwal R, Gupta SK, Agarwal P, Saxena R, Agrawal SS. Current concepts in the pathophysiology of glaucoma. See comment in PubMed Commons below Indian J Ophthalmol. 2009; 57: 257-266.
2. Yücel Y, Gupta N. Glaucoma of the brain: a disease model for the study of transsynaptic neural degeneration. See comment in PubMed Commons below Prog Brain Res. 2008; 173: 465-478.
3. Bahrami H. Causal inference in primary open angle glaucoma: specific discussion on intraocular pressure. See comment in PubMed Commons below Ophthalmic Epidemiol. 2006; 13: 283-289.
4. Coleman AL, Miglior S. Risk factors for glaucoma onset and progression. See comment in PubMed Commons below Surv Ophthalmol. 2008; 53 Suppl1: S3-10.
5. Singh K, Shrivastava A. Intraocular pressure fluctuations: how much do they matter? See comment in PubMed Commons below Curr Opin Ophthalmol. 2009; 20: 84-87.
6. Friedman DS, Wilson MR, Liebmann JM, Fechtner RD, Weinreb RN. An evidence-based assessment of risk factors for the progression of ocular hypertension and glaucoma. See comment in PubMed Commons below Am J Ophthalmol. 2004; 138: S19-31.
7. Boland MV, Quigley HA. Risk factors and open-angle glaucoma: classification and application. See comment in PubMed Commons below J Glaucoma. 2007; 16: 406-418.
8. Leske MC. Open-angle glaucoma -- an epidemiologic overview. See comment in PubMed Commons below Ophthalmic Epidemiol. 2007; 14: 166-172.
9. Sato EA, Ohtake Y, Shinoda K, Mashima Y, Kimura I. Decreased blood flow at neuroretinal rim of optic nerve head corresponds with visual field deficit in eyes with normal tension glaucoma. See comment in PubMed Commons below Graefes Arch Clin Exp Ophthalmol. 2006; 244: 795-801.
10. Crish SD, Calkins DJ. Neurodegeneration in glaucoma: progression and calcium-dependent intracellular mechanisms. See comment in PubMed Commons below Neuroscience. 2011; 176: 1-11.
11. McKinnon SJ. Glaucoma, apoptosis, and neuroprotection. See comment

- in PubMed Commons below *Curr Opin Ophthalmol*. 1997; 8: 28-37.
12. Levin LA. Mechanisms of optic neuropathy. See comment in PubMed Commons below *Curr Opin Ophthalmol*. 1997; 8: 9-15.
13. Vrabc JP, Levin LA. The neurobiology of cell death in glaucoma. See comment in PubMed Commons below *Eye (Lond)*. 2007; 21: S11-14.
14. Wax MB, Tezel G. Neurobiology of glaucomatous optic neuropathy: diverse cellular events in neurodegeneration and neuroprotection. See comment in PubMed Commons below *Mol Neurobiol*. 2002; 26: 45-55.
15. Quigley HA. Neuronal death in glaucoma. See comment in PubMed Commons below *Prog Retin Eye Res*. 1999; 18: 39-57.
16. Levin LA. Neuroprotection and regeneration in glaucoma. See comment in PubMed Commons below *Ophthalmol Clin North Am*. 2005; 18: 585-596, vii.
17. Nickells RW. Retinal ganglion cell death in glaucoma: the how, the why, and the maybe. See comment in PubMed Commons below *J Glaucoma*. 1996; 5: 345-356.
18. Kerrigan-Baumrind LA, Quigley HA, Pease ME, Kerrigan DF, Mitchell RS. Number of ganglion cells in glaucoma eyes compared with threshold visual field tests in the same persons. See comment in PubMed Commons below *Invest Ophthalmol Vis Sci*. 2000; 41: 741-748.
19. Cordeiro MF, Erskine L. Back to basics - ephrins, axonal guidance, neuroprotection and glaucoma. See comment in PubMed Commons below *Br J Ophthalmol*. 2007; 91: 1106.
20. Quigley HA, Nickells RW, Kerrigan LA, Pease ME, Thibault DJ, Zack DJ. Retinal ganglion cell death in experimental glaucoma and after axotomy occurs by apoptosis. See comment in PubMed Commons below *Invest Ophthalmol Vis Sci*. 1995; 36: 774-786.
21. Berkelaar M, Clarke DB, Wang YC, Bray GM, Aguayo AJ. Axotomy results in delayed death and apoptosis of retinal ganglion cells in adult rats. See comment in PubMed Commons below *J Neurosci*. 1994; 14: 4368-4374.
22. Mey J, Thanos S. Intravitreal injections of neurotrophic factors support the survival of axotomized retinal ganglion cells in adult rats *in vivo*. See comment in PubMed Commons below *Brain Res*. 1993; 602: 304-317.
23. Parrilla-Reverter G, Agudo M, Sobrado-Calvo P, Salinas-Navarro M, Villegas-Pérez MP, Vidal-Sanz M. Effects of different neurotrophic factors on the survival of retinal ganglion cells after a complete intraorbital nerve crush injury: a quantitative *in vivo* study. See comment in PubMed Commons below *Exp Eye Res*. 2009; 89: 32-41.
24. Nakazawa T, Tamai M, Mori N. Brain-derived neurotrophic factor prevents axotomized retinal ganglion cell death through MAPK and PI3K signaling pathways. See comment in PubMed Commons below *Invest Ophthalmol Vis Sci*. 2002; 43: 3319-3326.
25. Cheng L, Sapieha P, Kittlerova P, Hauswirth WW, Di Polo A. TrkB gene transfer protects retinal ganglion cells from axotomy-induced death *in vivo*. See comment in PubMed Commons below *J Neurosci*. 2002; 22: 3977-3986.
26. Chen H, Weber AJ. Brain-derived neurotrophic factor reduces TrkB protein and mRNA in the normal retina and following optic nerve crush in adult rats. See comment in PubMed Commons below *Brain Res*. 2004; 1011: 99-106.
27. Pernet V, Di Polo A. Synergistic action of brain-derived neurotrophic factor and lens injury promotes retinal ganglion cell survival, but leads to optic nerve dystrophy *in vivo*. *Brain J Neurol*. 2006; 129:1014-1026.
28. Meyer-Franke A, Kaplan MR, Pfrieger FW, Barres BA. Characterization of the signaling interactions that promote the survival and growth of developing retinal ganglion cells in culture. See comment in PubMed Commons below *Neuron*. 1995; 15: 805-819.
29. Goldberg JL, Espinosa JS, Xu Y, Davidson N, Kovacs GT, Barres BA. Retinal ganglion cells do not extend axons by default: promotion by neurotrophic signaling and electrical activity. See comment in PubMed Commons below *Neuron*. 2002; 33: 689-702.
30. Vass C, Hirn C, Sycha T, Findl O, Bauer P, Schmetterer L. Medical interventions for primary open angle glaucoma and ocular hypertension. See comment in PubMed Commons below *Cochrane Database Syst Rev*. 2007; : CD003167.
31. Parikh RS, Parikh SR, Navin S, Arun E, Thomas R. Practical approach to medical management of glaucoma. See comment in PubMed Commons below *Indian J Ophthalmol*. 2008; 56: 223-230.
32. Vishwakarma RA, Tyagi BR, Ahmed B, Husain A. Variation in forskolin content in the roots of *Coleus forskohlii*. See comment in PubMed Commons below *Planta Med*. 1988; 54: 471-472.
33. Seamon KB, Daly JW. Forskolin: a unique diterpene activator of cyclic AMP-generating systems. See comment in PubMed Commons below *J Cyclic Nucleotide Res*. 1981; 7: 201-224.
34. Barber R, Goka TJ. Adenylate cyclase activity as a function of forskolin concentration. See comment in PubMed Commons below *J Cyclic Nucleotide Protein Phosphor Res*. 1985; 10: 23-29.
35. Detry-Morel M. Currents on target intraocular pressure and intraocular pressure fluctuations in glaucoma management. See comment in PubMed Commons below *Bull Soc Belge Ophtalmol*. 2008: 35-43.
36. Bayer A, Tas A, Sobaci G, Henderer JD. Efficacy of latanoprost additive therapy on uncontrolled glaucoma. See comment in PubMed Commons below *Ophthalmologica*. 2002; 216: 443-448.
37. Juric DM, Loncar D, Carman-Krzan M. Noradrenergic stimulation of BDNF synthesis in astrocytes: mediation via alpha1- and beta1/beta2-adrenergic receptors. See comment in PubMed Commons below *Neurochem Int*. 2008; 52: 297-306.
38. Nakahashi T, Fujimura H, Altar CA, Li J, Kambayashi J, Tandon NN, et al. Vascular endothelial cells synthesize and secrete brain-derived neurotrophic factor. See comment in PubMed Commons below *FEBS Lett*. 2000; 470: 113-117.
39. Meyer-Franke A, Wilkinson GA, Kruttgen A, Hu M, Munro E, Hanson MG Jr, et al. Depolarization and cAMP elevation rapidly recruit TrkB to the plasma membrane of CNS neurons. See comment in PubMed Commons below *Neuron*. 1998; 21: 681-693.
40. Ji Y, Pang PT, Feng L, Lu B. Cyclic AMP controls BDNF-induced TrkB phosphorylation and dendritic spine formation in mature hippocampal neurons. See comment in PubMed Commons below *Nat Neurosci*. 2005; 8: 164-172.
41. Heim KE, Tagliaferro AR, Bobilya DJ. Flavonoid antioxidants: chemistry, metabolism and structure-activity relationships. See comment in PubMed Commons below *J Nutr Biochem*. 2002; 13: 572-584.
42. Lin B. Polyphenols and neuroprotection against ischemia and neurodegeneration. See comment in PubMed Commons below *Mini Rev Med Chem*. 2011; 11: 1222-1238.
43. Gutierrez-Merino C, Lopez-Sanchez C, Lagoa R, Samhan-Arias AK, Bueno C, Garcia-Martinez V. Neuroprotective actions of flavonoids. See comment in PubMed Commons below *Curr Med Chem*. 2011; 18: 1195-1212.
44. Zhang B, Rusciano D, Osborne NN. Orally administered epigallocatechin

- gallate attenuates retinal neuronal death in vivo and light-induced apoptosis in vitro. See comment in PubMed Commons below Brain Res. 2008; 1198: 141-152.
45. Zhang B, Safa R, Rusciano D, Osborne NN. Epigallocatechin gallate, an active ingredient from green tea, attenuates damaging influences to the retina caused by ischemia/reperfusion. See comment in PubMed Commons below Brain Res. 2007; 1159: 40-53.
46. Ramdas WD, Wolfs RC, Kiefte-de Jong JC, Hofman A, de Jong PT, Vingerling JR, et al. Nutrient intake and risk of open-angle glaucoma: the Rotterdam Study. See comment in PubMed Commons below Eur J Epidemiol. 2012; 27: 385-393.
47. Gupta SK, Selvan VK, Agrawal SS, Saxena R. Advances in pharmacological strategies for the prevention of cataract development. See comment in PubMed Commons below Indian J Ophthalmol. 2009; 57: 175-183.
48. Ventura LM, Porciatti V. Pattern electroretinogram in glaucoma. See comment in PubMed Commons below Curr Opin Ophthalmol. 2006; 17: 196-202.
49. Ventura LM, Sorokac N, De Los Santos R, Feuer WJ, Porciatti V. The relationship between retinal ganglion cell function and retinal nerve fiber thickness in early glaucoma. See comment in PubMed Commons below Invest Ophthalmol Vis Sci. 2006; 47: 3904-3911.
50. Bach M, Sulimma F, Gerling J. Little correlation of the pattern electroretinogram (PERG) and visual field measures in early glaucoma. See comment in PubMed Commons below Doc Ophthalmol. 1997; 94: 253-263.
51. Bach M, Hoffmann MB. Update on the pattern electroretinogram in glaucoma. See comment in PubMed Commons below Optom Vis Sci. 2008; 85: 386-395.
52. Holder GE, Brigell MG, Hawlina M, Meigen T, Vaegan, Bach M, International Society for Clinical Electrophysiology of Vision. ISCEV standard for clinical pattern electroretinography--2007 update. See comment in PubMed Commons below Doc Ophthalmol. 2007; 114: 111-116.
53. Bach M, Hawlina M, Holder GE, Marmor MF, Meigen T, Vaegan, et al. Standard for pattern electroretinography. International Society for Clinical Electrophysiology of Vision. See comment in PubMed Commons below Doc Ophthalmol. 2000; 101: 11-18.
54. Jacobi PC, Walter P, Brunner R, Krieglstein GK. Reproducibility and intraindividual variability of the pattern electroretinogram. See comment in PubMed Commons below Ger J Ophthalmol. 1994; 3: 216-219.
55. Peachey NS, Sokol S, Moskowitz A. Recording the contralateral PERG: effect of different electrodes. See comment in PubMed Commons below Invest Ophthalmol Vis Sci. 1983; 24: 1514-1516.
56. Seiple WH, Siegel IM. Recording the pattern electroretinogram: a cautionary note. See comment in PubMed Commons below Invest Ophthalmol Vis Sci. 1983; 24: 796-798.
57. Bach M, Hiss P, Röver J. Check-size specific changes of pattern electroretinogram in patients with early open-angle glaucoma. See comment in PubMed Commons below Doc Ophthalmol. 1988; 69: 315-322.
58. Korth M, Storck B, Horn F, Jonas J. [Pattern evoked electroretinograms in normal and glaucomatous eyes]. See comment in PubMed Commons below Fortschr Ophthalmol. 1987; 84: 385-387.
59. Porciatti V, Bagnoli P, Alesci R, Fontanesi G. Pharmacological dissociation of the b-wave and pattern electroretinogram. See comment in PubMed Commons below Doc Ophthalmol. 1987; 65: 377-383.
60. Parisi V, Manni G, Colacino G, Bucci MG. Cytidine-5'-diphosphocholine (citicoline) improves retinal and cortical responses in patients with glaucoma. See comment in PubMed Commons below Ophthalmology. 1999; 106: 1126-1134.
61. The Advanced Glaucoma Intervention Study (AGIS): 7. The relationship between control of intraocular pressure and visual field deterioration. The AGIS Investigators. See comment in PubMed Commons below Am J Ophthalmol. 2000; 130: 429-440.
62. Pescosolido N, Librando A. Oral administration of an association of forskolin, rutin and vitamins B1 and B2 potentiates the hypotonising effects of pharmacological treatments in POAG patients. See comment in PubMed Commons below Clin Ter. 2010; 161: e81-85.
63. Vetrugno M, Uva MG, Russo V, Iester M, Ciancaglini M, Brusini P, et al. Oral administration of forskolin and rutin contributes to intraocular pressure control in primary open angle glaucoma patients under maximum tolerated medical therapy. J OculPharmacolTher. 2012; 28: 536-541.
64. Deogracias R, Espliguero G, Iglesias T, Rodríguez-Peña A. Expression of the neurotrophin receptor trkB is regulated by the cAMP/CREB pathway in neurons. See comment in PubMed Commons below Mol Cell Neurosci. 2004; 26: 470-480.
65. Curtin BF, Pal N, Gordon RK, Nambiar MP. Forskolin, an inducer of cAMP, up-regulates acetylcholinesterase expression and protects against organophosphate exposure in neuro 2A cells. See comment in PubMed Commons below Mol Cell Biochem. 2006; 290: 23-32.
66. Sulaiman OA, Gordon T. Transforming growth factor-beta and forskolin attenuate the adverse effects of long-term Schwann cell denervation on peripheral nerve regeneration in vivo. See comment in PubMed Commons below Glia. 2002; 37: 206-218.
67. Metzger H, Lindner E. The positive inotropic-acting forskolin, a potent adenylate cyclase activator. See comment in PubMed Commons below Arzneimittelforschung. 1981; 31: 1248-1250.
68. Insel PA, Ostrom RS. Forskolin as a tool for examining adenylyl cyclase expression, regulation, and G protein signaling. See comment in PubMed Commons below Cell Mol Neurobiol. 2003; 23: 305-314.
69. Pugazhenthai S, Nesterova A, Sable C, Heidenreich KA, Boxer LM, Heasley LE, et al. Akt/protein kinase B up-regulates Bcl-2 expression through cAMP-response element-binding protein. See comment in PubMed Commons below J Biol Chem. 2000; 275: 10761-10766.
70. Bhandary B, Piao CS, Kim DS, Lee GH, Chae SW, Kim HR, et al. The protective effect of rutin against ischemia/reperfusion-associated hemodynamic alteration through antioxidant activity. Arch Pharm Res. 2012; 35: 1091-1097.
71. Jiménez-Aliaga K, Bermejo-Bescós P, Benedí J, Martín-Aragón S. Quercetin and rutin exhibit antiamyloidogenic and fibril-disaggregating effects in vitro and potent antioxidant activity in APP^{Swe} cells. See comment in PubMed Commons below Life Sci. 2011; 89: 939-945.
72. Kamalakkannan N, Stanely Mainzen Prince P. Rutin improves the antioxidant status in streptozotocin-induced diabetic rat tissues. See comment in PubMed Commons below Mol Cell Biochem. 2006; 293: 211-219.
73. Florek E, Ignatowicz E, Wrzosek J, Piekoszewski W. Effect of rutin on total antioxidant status of rats exposed to cigarette smoke. See comment in PubMed Commons below Pharmacol Rep. 2005; 57: 84-89.
74. Youdim KA, Qaiser MZ, Begley DJ, Rice-Evans CA, Abbott NJ. Flavonoid permeability across an in situ model of the blood-brain barrier. See

- comment in PubMed Commons below *Free Radic Biol Med.* 2004; 36: 592-604.
75. Javed H, Khan MM, Ahmad A, Vaibhav K, Ahmad ME, Khan A, et al. Rutin prevents cognitive impairments by ameliorating oxidative stress and neuroinflammation in rat model of sporadic dementia of Alzheimer type. See comment in PubMed Commons below *Neuroscience.* 2012; 210: 340-352.
76. Khan MM, Raza SS, Javed H, Ahmad A, Khan A, Islam F, et al. Rutin protects dopaminergic neurons from oxidative stress in an animal model of Parkinson's disease. See comment in PubMed Commons below *Neurotox Res.* 2012; 22: 1-15.
77. Nakayama M, Aihara M, Chen YN, Araie M, Tomita-Yokotani K, Iwashina T. Neuroprotective effects of flavonoids on hypoxia-, glutamate-, and oxidative stress-induced retinal ganglion cell death. See comment in PubMed Commons below *Mol Vis.* 2011; 17: 1784-1793.
78. Falsini B, Marangoni D, Salgarello T, Stifano G, Montrone L, Di Landro S, et al. Effect of epigallocatechin-gallate on inner retinal function in ocular hypertension and glaucoma: a short-term study by pattern electroretinogram. See comment in PubMed Commons below *Graefes Arch Clin Exp Ophthalmol.* 2009; 247: 1223-1233.
79. Chiou GC, Xu XR. Effects of some natural flavonoids on retinal function recovery after ischemic insult in the rat. See comment in PubMed Commons below *J Ocul Pharmacol Ther.* 2004; 20: 107-113.
80. Park YH, Chiou GC. Structure-activity relationship (SAR) between some natural flavonoids and ocular blood flow in the rabbit. See comment in PubMed Commons below *J Ocul Pharmacol Ther.* 2004; 20: 35-42.

Cite this article

Sisto D, Lavermicocca N, Errico D, Rusciano D (2013) Oral Administration of Forskolin and Rutin Contributes to Reduce Intraocular Pressure and Improve PERG (Pattern Electroretinogram) Amplitude in Glaucomatous Patients. *JSM Biotechnol Bioeng* 2(1): 1036.