

## Case Report

# Metal Clip Identification of Sentinel Node-Positive Breast Cancer after Neo adjuvant Chemotherapy

Ko Un Park and David Nathan Son\*

Department of Surgery, Henry Ford Hospital, USA

## \*Corresponding author

David Nathanson, Department of Surgery, Henry Ford Hospital, 6777 West Maple Road, West Bloomfield, USA. Tel: 248-661-6592; Fax: 313-916-9920; Email: dnathan1@hfhs.org

Submitted: 14 November 2016

Accepted: 20 December 2016

Published: 21 December 2016

## Copyright

© 2016 Son et al.

## OPEN ACCESS

## Keywords

- Sentinel lymph node
- Targeted axillary dissection
- Breast cancer

## Abstract

Breast cancer patients with cN1-3 disease undergoing neo-adjuvant chemotherapy (NACT) and who need a mastectomy for multiple primary tumors in overlapping quadrants are currently advised to undergo a complete axillary lymph node dissection (CALND). In these cases sentinel lymph node biopsy (SLNB) is usually not recommended. However, as demonstrated in this case report this paradigm may be shifting. Frozen section of a SLN containing a metal clip, placed at the time of pre-treatment needle biopsy under ultrasound guidance, may confer multiple benefits. This includes the clipped node demonstrating complete pathologic response, identifying a cohort of patients who might avoid CALND without adversely affecting overall survival, or reveal patients in whom residual metastatic disease perhaps justifies CALND. There is also a cohort of patients in whom the SLN doesn't contain the clip and in whom it is not clear whether a complete pathologic response has been achieved.

## ABBREVIATIONS

NACT: Neoadjuvant Chemotherapy, CALND: Complete Axillary Lymph Node Dissection; SLNB: Sentinel Lymph Node Biopsy

## INTRODUCTION

Neoadjuvant chemotherapy (NACT) is sometimes recommended in patients with clinically node-positive breast cancer (cN1-3) proven by needle biopsy. A metal clip is usually placed in the node at the time of the biopsy [1]. Current guidelines (NCCN.org) suggest that the appropriate surgical approach in these patients upon completion of systemic therapy is to do a complete axillary lymph node dissection (CALND). SLNB after NACT for proven axillary node metastases (mets) is not routinely recommended. However, the ACOSOG Z0011 study, even though it included only clinically node negative patients, shifted the paradigm on the role of CALND by showing no advantage with CALND in patients with pathologically SLN positive disease who undergo breast-conserving surgery [2]. There is insufficient data to warrant avoiding CALND in cN1-3 patients undergoing mastectomy, with or without NACT. Ongoing randomized trials may eventually rationalize doing SLNB in patients undergoing mastectomy, avoiding CALND, when a complete pathologic response to NACT is proven by intra-operative frozen section analysis, a technique currently called Targeted Axillary Dissection (TAD).

The metal clip is in the SLN in about 80% of patients with cN1 disease [1]. We describe a case report of a patient with cN1 breast cancer who had a metal clip placed at the time of sentinel lymph node biopsy (SLNB) which was successfully identified, removed and evaluated by frozen section analysis during SLNB after NACT.

## CASE PRESENTATION

A 61 year old female presented with a 2 centimeter palpable lump in the upper outer quadrant of the right breast, and a suspicious ALN on physical examination. Two dimensional mammograms, ultrasound and MRI-detected multi-centric masses in the right breast were identified, spanning an area of six centimeters. Both breast masses were biopsied with a needle core. Histopathology confirmed moderately differentiated invasive ductal carcinoma in all three areas. The breast molecular markers confirmed the tumor was estrogen receptor positive, progesterone receptor negative, Her-2/neu gene amplification positive by FISH assay, and Mib-1 staining 15% of tumor cells. Needle biopsy of the Axillary LN showed metastatic carcinoma (Figure 1). A metal clip was placed in the node. She received NACT with 4 courses of Adriamycin, Cyclophosphamide, and Taxol and anti-Her2 therapy with trastuzumab and pertuzumab.

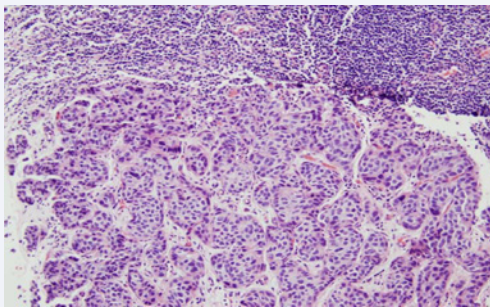
Pre-operative MRI demonstrated slight interval decrease in size of the breast masses and confirmed the masses did span an area of 6cm. Thus, mastectomy was performed. Careful discussion with the patient confirmed that she was interested in avoiding

CALND if there was no residual tumor in the clipped node. She agreed to undergo a SLNB using methylene blue dye and Tc-99m filtered sulfur colloid with the understanding that a CALND would be done if there was residual tumor in the node. A blue and hot node sentinel lymph node was removed from the lower axilla and intra operative imaging (Faxitron Bioptics LLC, Tucson, AZ) confirmed the presence of the metal clip (Figure 2). Among the two sentinel lymph nodes retrieved, frozen section pathology came back positive for metastatic carcinoma in the node with the metal clip and she underwent a CALND (Figure 3). Seventeen lymph nodes were retrieved, one of which contained metastasis without extranodal extension. Final pathology was aypT2N1 poorly differentiated multicentric invasive ductal carcinoma.

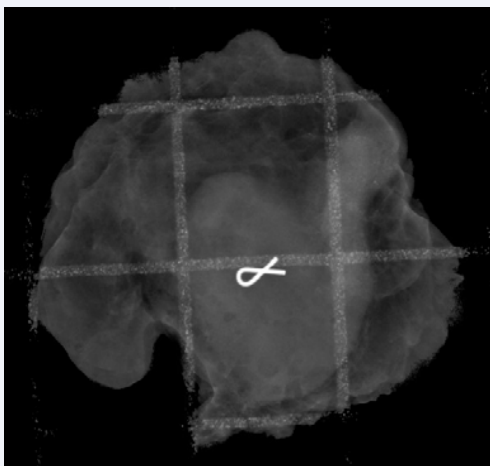
## DISCUSSION

Although a high rate of complete pathologic response in clinically node-positive breast cancer has been observed after NACT, particularly those that over express HER-2/neu, [3], we still don't have clear guidelines about which patients can safely avoid CALND [3]. Most surgeons feel that it is safer to do a modified radical mastectomy (MRM), even when there is a complete pathologic response in the SLN. In our case there was residual nodal tumor and we therefore elected to do a MRM.

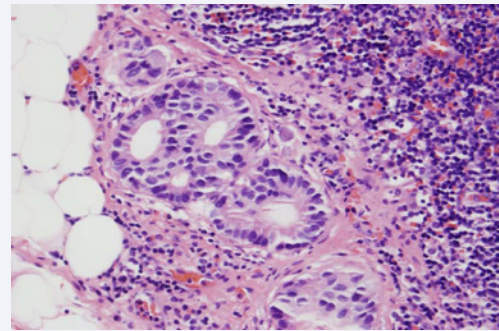
Our patient fitted into the majority cohort in whom the



**Figure 1** Ultrasound guided core needle biopsy of axillary lymph node demonstrating metastatic carcinoma. Hema toxylin and Eosin (H and E) X20.



**Figure 2** Sentinel lymph node imaged with intra operative radiograph shows previously placed metal clip.



**Figure 3** Completion axillary lymph node dissection shows evidence of residual metastatic carcinoma in the lymph node. Hematoxylin and Eosin (H and E) X40.

pre-operatively biopsied node containing the metal clip was the same as the SLN [1]. However, at least twenty percent of patients have a SLN that does not contain the clip [1,5, 6]. Future management of such patients will need to concentrate on how to identify the clipped node in one hundred percent of cases. This issue is currently being addressed in increasing numbers of studies. Claude et al recently reported the use of radioactive seed to identify the clipped node for TAD [6] a novel technique where a radioactive seed is used to localize and remove the node with the clip, placed before NACT [7]. This technique was shown to significantly reduce the 'failure to find rate' of the needle-biopsied node from 10.1% if SLNB was used alone, to 1.4% when the clipped node was retrieved during the SLNB. Similarly the clipped node was removed as the SLN in the Z1071 Alliance trial in 76% of the cases [5]. The technique of removal of the clipped node is clearly more accurate for documenting histopathologic responses than merely relying on SLNB alone [7].

Alternative strategies for finding the clipped node include: localization using percutaneous wire into the node, radioactive seed, nonradioactive markers such as Mag seed (EndomagneticsInc, Austin, TX) and Savi Scout (Cianna Medical Inc, Aliso Viejo, CA) or tattoo ink of the lymph node at the time of the biopsy. Further research is needed to discern the most economic and accurate method of localizing the clipped node.

This case exemplifies the use of dual tracer sentinel lymph node biopsy to identify the clipped node which was confirmed via intraoperative radiographic imaging. Future studies focusing on the best method of identifying and removing the clipped node will help refine TAD.

## REFERENCES

1. Nathanson SD, Burke M, Slater R, Kapke A. Preoperative identification of the sentinel lymph node in breast cancer. *Ann SurgOncol.* 2007; 14: 3102-3110.
2. Giuliano AE, Hunt KK, BallmanKV, Beitsch PD, Whitworth PW, Blumencranz PW, et al. Axillary Dissection vs No Axillary Dissection in Women With Invasive Breast Cancer and Sentinel Node Metastasis: A Randomized Clinical Trial. *JAMA.* 2011; 305: 569-575.
3. Mougalian SS, Hernandex M, Lei X, Lynch S, Kuerer HM, Symmans WF, et al. Ten-Year Outcomes of Patients With Breast Cancer With Cytologically Confirmed Axillary Lymph Node Metastases and Pathologic Complete Response After Primary Systemic Chemotherapy. *JAMA Oncol.* 2016; 2: 508-516.

4. Kuerer HM, Sahin AA, Hunt KK, Newman LA, Breslin TM, Ames FC, et al. Incidence and impact of documented eradication of breast cancer axillary lymph node metastases before surgery in patients treated with neoadjuvant chemotherapy. *Ann Surg.* 1999; 230: 72-78.
5. Boughey JC, Ballman KV, Le-Petross HT, McCall LM, Mittendorf EA, Ahrendt GM, et al. Identification and Resection of Clipped Node Decreases the False-negative Rate of Sentinel Lymph Node Surgery in Patients Presenting With Node-positive Breast Cancer (T0-T4, N1-N2) Who Receive Neoadjuvant Chemotherapy: Results From ACOSOG Z1071 (Alliance). *Ann Surg.* 2016; 263: 802-807.
6. Caudle AS, Yang WT, Krishnamurthy S, Mittendorf EA, Black DM, Gilcrease M, et al. Improved axillary evaluation following neoadjuvant therapy for patients with node-positive breast cancer using selective evaluation of clipped nodes: implementation of targeted axillary dissection. *J ClinOncol.* 2016; 34: 1072-1078.
7. Kuerer HM, Hunt KK. Limiting Axillary Surgery for Patients with Initial Biopsy-Proven Axillary Metastases After Preoperative Chemotherapy: To Clip or Not to Clip? *Ann Surg Oncol.* 2016; 23: 3432-3434.

**Cite this article**

Park KU, Son DN (2016) Metal Clip Identification of Sentinel Node-Positive Breast Cancer after Neo adjuvant Chemotherapy. *Ann Breast Cancer Res* 1(1): 1006.