

Case Report

“Ribeiro in a Hammock” - Technique for Mastopexy

Alina Abu-Ghazaleh*, Sonia Fertsch, Mazen Hagouan, Maximilian Otte, Philipp Richrath, Beatrix Munder, Peter Stambera, and Christoph Andree

Department of Plastic and Aesthetic Surgery, Sana Kliniken Düsseldorf, Germany

*Corresponding author

Alina Abu-Ghazaleh, Gräulinger Str. 120, 40625
Düsseldorf, Germany, Tel: +49 211 2800 86304, Email:
alina.abu-ghazaleh@sana.de

Submitted: 07 February 2017

Accepted: 16 March 2017

Published: 18 March 2017

Copyright

© 2017 Abu-Ghazaleh et al.

OPEN ACCESS

Keywords

- Mastopexy
- Ribeiro-Flap
- Auto augmentation
- Dermoglandular hammock

Abstract

The article describes a modified technique of Ribeiro's "security flap" described 1973. The existing breast tissue of a mild to moderate ptotic breast is reshaped for restoring upper pole fullness, better projection of the breast mound and improving the nipple-areolar position. Addressing the problem of "bottoming-out" an inferior chest wall based flap is sutured to the pectoralis fascia; after being advanced to the upper pole and subsequently secured ventrally and inferiorly by connecting an inferior medial and lateral flap forming a dermoglandular hammock.

ABBREVIATIONS

NAC: Nipple-Areola-Complex; PDS: Polydioxanon; IMF: Inframammary Fold

INTRODUCTION

The mastopexy procedure forms an inherent part of the daily routine performed by plastic surgeons as women of different ages present with varied forms of breast ptosis. In general breast ptosis is described as a descent of the breast and the nipple areola complex on the chest wall [1,12]. The shape of the female breast is affected by a number of factors.

The missing reduction of the breast envelope caused by decreasing elasticity and increasing laxity of the skin and ligaments as well as the decreasing volume of parenchyma gives rise to mammoptosis [6]. Its causes are multifactorial and include the number of pregnancies, age, weight fluctuations, fluctuations in hormone levels and smoking history [3]. A significant connection to the number and duration of lactation failed to be demonstrated [3] although women with mild to moderate ptosis have reported that ptosis occurred after breast-feeding.

The classification of Regnault [1] can be used to determine the degree of ptosis.

- Grade I ptosis, as its mildest form, shows the nipple-areola-complex (NAC) at the level of the inframammary fold.
- In the case of moderate ptosis, grade II, the NAC is located below the inframammary fold, but above the lower outline of the breast.
- The severe ptosis (grade III) is characterized by the location of the NAC at the most dependent part of the

breast at its inferior contour.

Patients suffering of grade I and II ptosis especially after pregnancies and periods of lactation complain a deficiency of upper pole fullness. They request a long lasting mastopexy result, without the loss of existing breast volume and without using a prosthesis which can be accomplished by the redistribution of the breast tissue giving more volume to the upper part of the breast. Autoaugmentation mastopexy describes the use of the patients-own tissue to give volume to the upper pole instead of using a prosthesis [4-7]. The basic idea of auto augmentation mastopexy is reshaping and redistributing the existing breast tissue in order to achieve a proper nipple position accompanied by a well-contoured breast with good projection. That means adding volume in deficient parts by reducing volume in parts of excess parenchyma. Getting more projection with existing volume can be achieved either by narrowing the width of the breast or by reducing its height.

A great number of different mastopexy techniques or modified well-known procedures have been published during the last decades. Several authors described the use of a dermoglandular flap for providing upper pole fullness or a better projection of the breast mound [5-17]. Differences in the positioning of the incisions and varieties in the redistribution procedure of the gland show, that the procedure is not yet perfected. It is evident that the skin and dermis of the breast do not give enough suspension for a long lasting result [2].

CASE PRESENTATION

The benefit of our mastopexy technique, as a modification of the "security flap" technique described by Ribeiro 1973, is the avoidance of resecting breast tissue other than redundant skin, filling out the upper pole by using the existing parenchyma and

by internal suspension of the lateral and medial pillars relocating the nipple areolar complex in a more pleasing location. The innervation and vascular supply of the breast tissue and of the nipple areolar complex are preserved using our technique.

The procedure is easy to learn and can be used for grade I and II ptosis.

Markings

The preoperative drawings proceed with the patient in standing position. The surgical procedure is done using an inverted-T approach preserving a mediocranial pedicle for the blood supply of the nipple-areola complex (NAC).

First, the important anatomical landmarks are marked. These comprise the sternal notch with the mid sternal line, the inframammary crease line, the mid breast line and the new nipple position. The latter is located on the mid breast line at the level of the inframammary fold on the anterior surface of the breast. The mid breast line is marked from the clavicle to the nipple and then continued from the inframammary crease down the lower thoracic wall. Then, by moving the breast gently with the hand medially and laterally the new position of the nipple is connected by drawing a vertical line to the mid breast line at the level of the inframammary fold marking. The more the breast is moved either laterally or medially, the wider the angle of the inverted V becomes, this is directly correlated with the amount of resected skin.

On both lines of the inverted V drawing two marks are set on each line, the first about 5cm from the new NAC position, and the second one another 6cm away from the first mark. The first marks are connected with each other using a semicircular line that is drawn 1,5cm above the new nipple position on the mid breast line. This point is the new apex of the NAC. The secondary marks are connected horizontally with the inframammary crease line medially and laterally. Within this „keyhole“-marking the mediocranial pedicle is designed starting from the new nac apex, ending in the middle of the medial vertical line of the keyhole. The base of the mediocranial pedicle should not measure less than 8cm. The symmetry of the markings, especially the new nac positions, are checked in front of a mirror.

Surgical Procedure

The operation is performed under general anesthesia. The patient is located in supine position with both arms abducted and supported on gel-covered arm boards. Routinely an intravenous antibiotic is given to the patient before the incision. After applying a mamma-tourniquet to the breast an areolar marker is applied and the skin around the nipple-areolar complex is incised. Then the incision is continued along the marked mediocranial pedicle and along the marked keyhole-shaped lines. The skin within the marking of the mediocranial pedicle, except for the nipple-areola complex itself, is de-epithelialised.

The dermis of the outer edge of the mediocranial pedicle, not its base, is separated using the electrocautery. Then the tourniquet is resolved and the mediocranial pedicle is raised, dissecting the breast parenchyma strictly vertically towards the pectoralis fascia. It is important to not undermine either the nac

carrying pedicle or the lateral pillar of the keyhole drawing to avoid volume deficiency. After that the skin incision is completed in the remaining lines of the lower part of the “keyhole”. The skin is de-epithelialised in the entire lower part of the breast within the skin incisions.

The inferior thoracic wall-based rectangular dermoglandular flap, described earlier by Ribeiro in 1973 is planned within the area that is limited cranial by the mediocranial pedicle, medial and lateral by the vertical incisions of the keyhole and caudal by the inframammary incision. The width of the flap is predefined by the distance between the vertical incisions. The length is given by the distance between the inframammary crease line and the lower border of the mediocranial pedicle. All four sides of the flap are incised to the thoracic wall leaving the dorsal part attached to the pectoralis fascia for the blood supply of the flap and leaving a narrow edge of dermis to the vertical and the inframammary incision.

The remaining dermoglandular triangles medial and lateral of the inferior flap are raised incising the dermis and without dividing the subcutaneous tissue. The mediocranial pedicle is rotated to the new location tailor tacking the apex of the nac to the skin. After that a prepectoral pocket is separated under the mediocranial pedicle. The inferior central wall-based flap is advanced to the prepectoral pocket and its position is secured by suturing its dermal edge to the pectoral major fascia using 3/0 Polydioxanon (PDS, Ethicon)-suture. The medial and lateral chest wall-based dermoglandular triangles are connected to each other ventrally to the “Ribeiro”-Flap and their dermal edges are sutured with several stitches using 3/0 Polydioxanon (PDS, Ethicon). Using this fashion the suture-secured inferior flap has an additional caudal support by a dermoglandular hammock and the volume of the lower pole of the breast is redistributed to the middle. The columns of the breast tissue are approached to the inframammary fold with a deep triangle suture. This secures the deep fascia in the midline of the inframammary fold and the deep fascia of the lower corner of the breast columns building the base of the T-junction. The skin closure is done in two layers, deep dermal buried stitches with 3/0 Poliglecapron (Monocryl, Ethicon) and an intradermal running suture with 3/0 Poliglecapron (Monocryl, Ethicon) The nipple-areola complex is sutured with a dermal purse-string suture using V-lock 3/0 Poliglecapron (Monocryl, Ethicon) and with an intradermal running suture with 4/0 polypropylene (Prolene, Ethicon). Steristrips are placed on the wounds and a hydrocolloid bound is applied vertically on the lateral edge of the reshaped breast to stabilize it laterally. Through meticulous haemostasis drainage can be avoided. Back in the ward a supporting bra is dressed and the patient is informed to wear the supporting garment day and night for 6 weeks. The polypropylene (Prolene, Ethicon) suture is removed 3 weeks after the operation, after the date of operation the patient is allowed to resume sportive activities 8 weeks later.

DISCUSSION

The idea of using the existing parenchyma to give more fullness to the upper pole of the breast and to give more projection to the center of the breast is not new [4-15,17,18]. Nowadays the patients mostly do not accept the usage of breast implants for

restoring the upper pole fullness to avoid the complications that are associated with usage of breast implants.

More than 30 years ago Ribeiro described the possibility of using an inferior thoracic wall-based flap to redistribute parenchyma to the upper part of the breast to give more projection and upper pole fullness. This technique could be used for all degrees of ptosis and with various types of incisions.

The combination of excess skin with moderate to little volume of breast tissue in quite a few mastopexy cases necessitates an incision type that can enable sufficient skin resection. A periareolar or vertical approach in our view, fail in the possibility of resecting enough excessing skin without creating new problems such as dog ears, long vertical scars exceeding the IMF or reduced projection of the breast due to tight periareolar pexy. Detailed and intensive information of the patient shows that the majority is not bothered about an inverted T-shaped scar as long as the result is pleasing.

The dermoglandular inferior flap as described by Ribeiro is secured to the pectoralis fascia with several absorbable (Polydioxanon, PDS) sutures. It is believed that in this way less weight has to be carried by the lower breast skin thus a pseudoptosis can be avoided.

Related Techniques vary mostly in the dimension of the inferior dermoglandular flap and whether the dermal connection to the inframammary fold skin is divided or in the nipple areola complex pedicle [5, 9-11], [13,17,18]. The attachment of the inferior flap is realized in most cases to the pectoralis fascia either with absorbable or with non absorbable sutures [5,9-13,17,18].

A modification described by Graf [11] pass the flap through a loop of pectoral muscle before suturing the dermis of the flap to the pectoralis fascia. This provides a good support to the flap but possible sequelae in case of the development of cancer have to be kept in mind. Besides holding a flap with a tight muscle loop risks the blood supply of the flap with possibility of fat necrosis. Ritz uses a bipediced fascia flap instead of a muscle loop, to stabilize the inferior flap in its new position [19].

In comparison to our technique Sisti et al., Perform a remodeling of the breast shape by dividing the lower portion of the breast into three parts. The central part is turned over to give projection at the NAC level. The medial and lateral flaps are connected in the midline. The vascular supply of the three flaps relies on a superior pedicle. Especially in cases of severe ptosis the length of the superior pedicle can extend and lead to a restricted perfusion (Figure 1).

The dermoglandular flaps described in our technique are raised as perforator flaps in order to shorten the distance of the vascular supply.

By performing a mastopexy to our patients who do not want to sacrifice any of the existing volume of their breast due to mastopexy we discovered that the two triangular dermoglandular flaps, medial and lateral to the "Ribeiro" Flap can be approached and sutured right in front of the base of the already to the chest wall attached Ribeiro flap. This hammock-like connection between the two flaps gives additional support to the central flap avoiding a "bottoming out" of the lower pole. Furthermore the

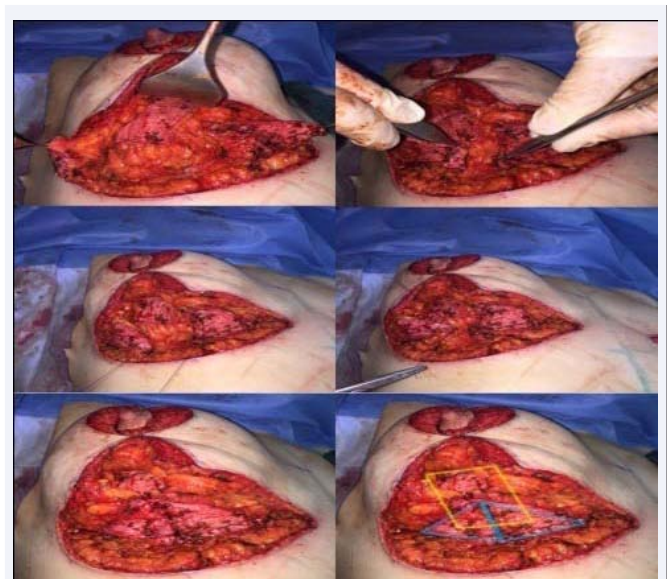


Figure 1 Intraoperative view of patient undergoing autoaugmentation mammoplasty with a "Ribeiro in a hammock" technique. After the ribeiro flap is risen and fixed to the chest wall, the two triangular flaps left medial and lateral in the keyhole excision are medialized after incising the dermis. Before closing the skin the ribeiro flap is supported by the dermoglandular hammock built by the connected triangular flaps.

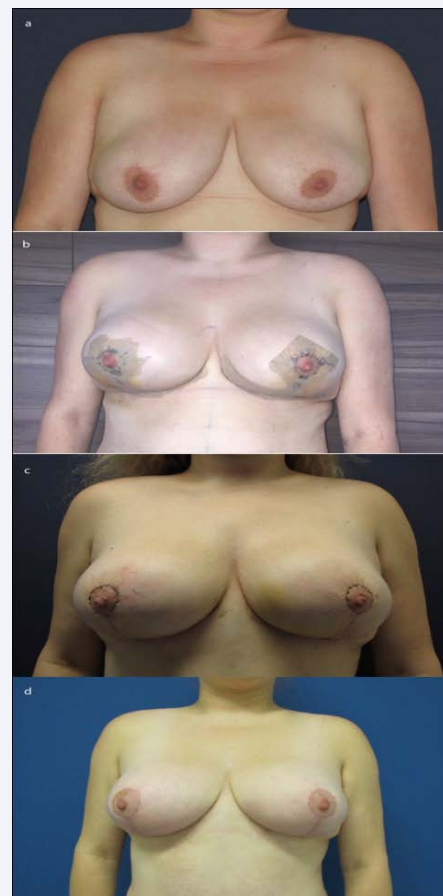


Figure 2 Anterior views of the patient preoperatively (a), 4 days (b), 2 weeks (c) and 6 weeks (d) after surgery.

volume in the lower pole of the breast is redistributed towards the breast median leading to a pleasant shape and giving more projection to the breast. By using an inferior dermoglandular flap that is still connected to the dermis of the IMF (Kelemen 2012) the vertical advancement of the flap is reduced especially in small ptotic breasts. In patients with a normal positioned inframammary fold this maneuver leads to the relocation of the IMF. The projection is consequently reached by reducing the height of the breast. In comparison our technique releases the inferior dermis from the IMF and can be vertically advanced without traction of the IMF. Besides the volume is redistributed to the median and to the upper pole of the breast.

In light of increasing incidences of breast cancer using a muscle loop as described by Graf [11] or a fascial loop as described by Ritz [18] is not an appropriate surgical option for us (Figure 2).

The described technique is easy to learn and applicable for mastopexy of mild to moderate ptotic breasts where a volume reduction is not wanted. Our cases showed good postoperative results with a pleasing shape of the breast, with good projection, a fuller upper pole, consistent sensitivity of the nipple and lack of fat necrosis. Long-lasting result of this technique are yet to be seen. So far the described technique full fills our and our patient's expectations.

REFERENCES

1. Regnault P. Breast ptosis. Definition and treatment. *Clin Plast Surg.* 1976; 3: 193-203.
2. Lockwood TE. Superficial fascial system (SFS) of the trunk and extremities: a new concept. *Plast Reconstr Surg.* 1991; 87: 1009-1018.
3. Rinker B, Veneracion M, Walsh CP. Breast ptosis: causes and cure. *Ann Plast Surg.* 2010; 64: 579-584.
4. Rubin JP, Khachi G. Mastopexy after massive weight loss: dermal suspension and selective auto-augmentation. *Clin Plast Surg.* 2008; 35: 123-129.
5. Hönig JF, Frey HP, Hasse FM, Hasselberg. Autoaugmentation mastopexy with an inferior-Based pedicle. *Aesthetic Plast Surg.* 2009; 33: 302-307.
6. Kim P, Kim KK, Casas LA. Superior pedicle autoaugmentation mastopexy: a review of 34 consecutive patients. *Aesthet Surg J.* 2010; 30: 201-210.
7. Ho LC. The small ptotic breast: reposition autoaugmentation mammoplasty. *Br J Plast Surg.* 1986; 39: 76-80.
8. De la Plaza R, de la Cruz L, Moreno C. Mastopexy utilizing a dermoglandular hammock flap. *Aesthet Surg J.* 2005; 25: 31-36.
9. Fayman MS. Short scar mastopexy with flap transposition. *Aesthetic Plast Surg.* 1998; 22: 135-41.
10. Foustanos A, Zavrides H. A double-flap technique: an alternative mastopexy approach. *Plast Reconstr Surg.* 2007; 120: 55-60.
11. Graf R, Biggs TM, Steely RL. Breast shape: a technique for better upper pole fullness. *Aesthetic Plast Surg.* 2000; 24: 348-352.
12. Gümüş N. A versatile modification of dermoglandular hammock flap for mastopexy: Extended hammock. *J Plast Surg Hand Surg.* 2013; 47: 252-257.
13. Kelemen N, Kannan RY, Offer GJ. A stacked technique of mastopexy: Volume redistribution mastopexy with inferior flap and superomedially based pedicle. *Aesthetic Plast. Surg.* 2013; 37: 349-353.
14. Okada A. Mastopexy after massive weight loss?: dermal suspension, parenchymal reshaping, and augmentation with autologous tissue. *Brazilian J. Plast. Surg.* 2012; 27: 283-289.
15. Ribeiro L, Accorsi A, Buss A, Marcal-Pessoa M. Creation and evolution of 30 years of the inferior pedicle in reduction mammoplasties. *Plastic and reconstructive surgery.* 2002; 110: 960-970.
16. Rubin JP, a Gusenoff J, Coon D. Dermal suspension and parenchymal reshaping mastopexy after massive weight loss: statistical analysis with concomitant procedures from a prospective registry. *Plast. Reconstr. Surg.* 2009; 123: 782-789.
17. Voigt M, C. Andree C. Breast shaping by an isolated tissue flap, in *Mastopexy and Breast Reduction: Principles and Practice*, 2009; 30: 545-553.
18. Ritz M, Silfen R, Southwick G. Fascial suspension mastopexy. *Plast Reconstr Surg.* 2006; 117: 86-94.
19. Sisti A, Tassinari J, Nisi G, Grimaldi L. Superior Pedicle Mastopexy with the Three Fat-Glandular Flap Support. *Plast Reconstr Surg.* 2017; 139: 311-312.

Cite this article

Abu-Ghazaleh A, Fertsch S, Hagouan M, Otte M, Richrath P, et al. (2017) "Ribeiro in a Hammock"-Technique for Mastopexy. *Ann Breast Cancer Res* 2(1): 1010.