

Review Article

Step-by-Step of New Method Development for Treatment of Postburn total (Severe) Shoulder Adduction Contractures: Anatomic Substantiation and Results

Viktor M. Grishkevich*

Department of Reconstructive and Plastic Surgery, A.V. Vishnevsky Institute of Surgery of the Russian Academy of Medical Sciences, Russia

*Corresponding author

Viktor M. Grishkevich, Department of Reconstructive and Plastic Surgery, A.V. Vishnevsky Institute of Surgery of the Russian Academy of Medical Sciences, Moscow, Russia, Tel: 503-698-1195; Email: grishkevichmail@gmail.com

Submitted: 29 October 2018

Accepted: 26 November 2018

Published: 28 November 2018

ISSN: 2475-9406

Copyright

© 2018 Grishkevich

OPEN ACCESS

Abstract

Background: The review of literature and personal observations proved that the anatomy of total shoulder adduction contractures is insufficiently researched, and the efficacy of typically used surgical techniques is low. Skin transplants in axilla shrink and contracture often recurs; local triangular and other form flaps are small for big scar/skin surface deficit compensation and complete contracture elimination. Therefore, the thoracic flaps of different form and size are used despite the traumatic nature of the technique. The harvesting of a large flap deforms the chest wall. Often, thoracic flaps have insufficient dimensions; therefore, the contracture is not released completely. Having rich clinical material, we tested existing techniques without a satisfactory outcome, and undertook further research to find a scientific solution to this complex surgical problem.

Material and Method: Our research was based on clinical exploration and surgical treatment of 58 patients, pediatric and adults, with total adduction contractures, using the following four techniques consecutively: (a) thoracodorsal flaps; (b) subcutaneous pedicle flap from island axillary skin in conjunction with skin transplants; (c) quadrangular subcutaneous pedicle flap from local axillary scars and skin transplants island axillary skin. The patients' age ranged from 5 to 43 years old. TBS was from 6 to 56%; patients underwent surgery after 6 months to 2 years after burns. The research was directed towards transformation of the role of the flap: from covering the wound into suspending the axilla. Skin transplants were to be used for wound coverage.

Results: Presented new surgical method solved the problem of treatment of the most complex total shoulder contracture. The method is easy to plan and perform, less traumatic, easily tolerated by children, leaving the donor site undamaged. In all cases, total shoulder contractures were fully eliminated, and no re-contractures were noticed. New flap location allowed us to use different forms and sizes of flaps, local and regional, which made the technique less traumatic and more effective and accessible for successful treatment of all total shoulder scar contractures.

Conclusion: The new technique is exclusively effective for total shoulder contractures elimination. Method consists in stable axilla suspension with local scar axillary subcutaneous pedicle flap and wounds covering with whole skin transplants. Axilla suspension and wound division on thoracic and shoulder prevents skin transplants shrinkage and contracture recurrence.

INTRODUCTION

Total shoulder adduction contractures have specific anatomic features that were used as basis for further exploration. Shoulder joint has flexion (F) and extension (E) surfaces. Two curvatures, caused by edges of axillary fossa, divide the flexion surface into two flexion lateral (FL) surfaces, spreading from the edges of fossa to the joint rotation axis anteriorly and posteriorly. Joint flexion medial (FM) surface is axilla, surface between the fossa' edges. Total shoulder contracture is formed after vast burns and scars, damaging entire flexion surface, both lateral and one medial. Contracted scars, covering entire joint flexion surface and causing total contracture, do not have a fold (scar surface surplus), but have a severe scar surface deficit which excludes

the use of local-flap techniques. The problem of treatment of total shoulder contractures was aggravated by the shrinkage of skin transplants covering the axillary wound. In such cases, the contracture often recurred. Therefore, the most popular technique becomes reconstruction with thoracic flaps of different form, size, and location by which the wound was covered [1]. Thoracic flaps are used not only for total contracture treatment, when a huge flap is needed, but for more simple edge anterior and posterior contractures treatment [2] and children [3]. This fact indicates that results of thoracic flap use for total shoulder contractures treatment are not anatomic substantiated. Less complex contractures-edge and medial were successfully treated with local adipose-cutaneous trapezoid flaps [4]. Therefore, the

efficacy and expedience of total shoulder contractures treatment with thoracodorsal flaps needs to be re-examined [5]. Our goal was to develop a less traumatic technique, avoid the use of a large thoracic flap, to treat the total shoulder contractures completely and without recurrence, to use the most of local axillary skin, scars, and skin transplants. As a result, the new technique was developed in which negative sides of known methods were excluded, surgery became less traumatic and without re-contracture. Details of method and outcomes were presented in this paper.

MATERIAL AND METHOD

The treatment of total shoulder contractures began with split skin transplantation. The contracture slowly recurred but was less expressed. Then, the thoracodorsal flaps were used, and soon became obvious that after a full contracture release, a large wound arises, the matching size for which a flap was often impossible to elevate without chest wall injury. Therefore, twenty patients were analyzed in whom narrow thoracic flaps were used for covering a central part of the wound and axilla suspended; the wounds, skin surface deficit, beside the flap was skin grafted. Sixteen had total (severe) shoulder scar contractures in which the island skin was preserved in the axillary fossa's apex (cupola). The island skin was converted into the flap and was used as part of the new technique. Total shoulder contractures of 22 patients were treated with axillary scar subcutaneous pedicle flaps in conjunction with skin transplants.

Among 58 patients, 32 were male and 26, female, ranging in age from 5 to 49 years old. All patients sustained deep-partial or full-thickness burns from 8 to 33 % of TBS (total body surface). Reconstruction was performed from 6 months to 6 years after burns.

Before surgery, determined the scars' spreading on the upper extremity and chest wall, the condition of surface tissues of the donor sites, scars of axilla as donor site, the scars' maturity, the range of shoulder abduction, the function of other joints were explored because all contractures were to be eliminated simultaneously. Follow-up results observed from 6 months to 5 years.

RESULTS

Functional zones and surgical anatomy of the shoulder joint (Figure 1 a,b)

The joint surface located above the joint rotation axis ("+" symbol) is the joint extension surface (E). The surface below the joint rotation axis ("+" symbol) is the joint flexion surface (F) (Figure 1a). The flexion surface has two curvatures - anterior and posterior (Cr), which caused by the edges of muscles, forming the edges of the axillary fossa- pectoralis major and latissimus dorsi. Thus, the joint flexion surface (F) covers the joint's space between symbols "+" located anteriorly and posteriorly of joint surface. Two curvatures or axillary fossa edges or folds (Fold-Fd; Figure 1 a,b) divide the joint flexion surface into two: joint flexion lateral (FL) surface (these are lateral sides of the joint's surface) and joint flexion medial (FM) surface or axilla (fossa), located between curvatures or fossa's edges. Thus, the joint flexion lateral surfaces (FL) are a space spreading from the curvatures or edges

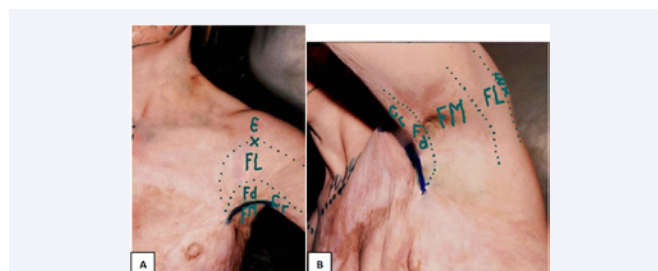

Figure 1 Anatomic features of shoulder edge adduction contractures pertaining to all edge contractures. (A and B) Functional zones: E - extension surface; F - flexion surface; FL - flexion lateral surface; Fd - fold; FM - flexion medial surface; symbol "+" joint rotation axis; Cr - crest of the fold and edge of scars. Anatomic and clinical signs: scars on FL surface; fold located along edge joint fossa (FM surface) and commissural edges; lateral fold's sheets are scars, medial sheet is healthy skin; crest (Cr) of the fold is the edge of scars.

of the axillary fossa to the joint rotation axis ("+" symbol) anteriorly and posteriorly; the joint flexion medial surface is the space between edges of the axillary fossa.

Three anatomic types of shoulder scar flexion contractures (Figures 2-4), [4]

Edge shoulder contracture (Figure 1,2) is caused and characterized by scars covering the joint flexion lateral one or both surface/s (FL). Edge contracture are eliminated with axillary trapezoid adipose-cutaneous flap and trapezoid flaps from scar sheets of the fold (Figure 2a-d).

Medial flexion contracture (Figure 3) is caused with scars covering axilla or space between edges of axilla (axillary fossa). Scars form the fold, both sheets of which are scars and have surface surplus (Figure 3a-c). Contracture elimination is concluded in converting scar sheets into trapezoid flaps and their counter transposition (Figure 3d-f).

Total shoulder adduction contracture (Figure 4) was formed when burns and scars injury all joint flexion surface (F)-- both joint flexion lateral (FL) and joint flexion medial (FM) surfaces (Figure 4 a-d). Vast scars grow distally, displaces axilla downwards, leaving the shoulder free, and scar surface in axilla was relatively flat from which the flap can be formed (Figure 4a). In case more severe injury, shoulder fuses with chest wall because severe scar surface deficit. After scars dissection and contracture release with Y-incision, a huge wound appeared (Figure 4d,e). The wound and scar surface deficit spreads to the joint rotation axis from anteriorly to posteriorly, where wound twice increased after fully shoulder abduction (Figure 4f,g). Thus, the total shoulder contracture was caused with scars covering all joint flexion (F) surface and tightly surrounding a joint without fold and having severe scar surface deficit, was named total shoulder contracture and total contracture type. Total shoulder contractures were always severe, contracted do not have the fold, presenting the scar surface surplus; therefore, the local flap use for treatment is excluded.

Steps of a new surgical technique development

Three steps of exploration took place towards the development of the new method: (a) conjunction of the thoracodorsal

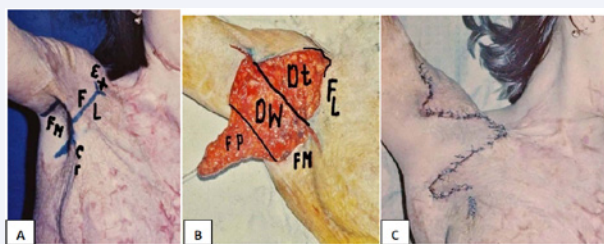


Figure 2 Edge shoulder adduction contracture: anatomy, surgery and result. (A) Anatomy (scars: FL surface and lateral sheet of the fold; planning: trapezoid flap in axilla and Y-line for scars dissection; (B) Operation: Dt- trapezoid scar surface deficit and wound spread to the joint rotation axis, contracture cause, DW-donor wound; FP-flap; (C) Result: trapezoid flap covered wound and compensated scar surface deficit.

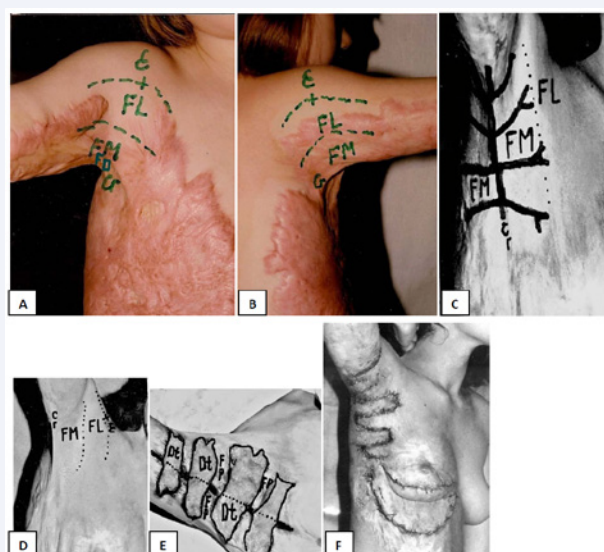


Figure 3 Medial contracture anatomy. (A and B) Joint functional zones as in case of edge contracture. Anatomy and clinical signs: scars are located on joint flexion medial (FM) surface or joint fossa; fold crest passes along the medial line of FM surface; both sheets of the fold are scars. Next case; (C, D) Anatomy of shoulder medial contracture and trapeze-flap plasty planning; (E) Scars dissected with Y-radial incision: trapezoid wound and flaps; (F) Result of trapeze-flap plasty (seven days after operation).

pedicle flaps for axilla suspension and wounds beside the flap covering with whole skin transplants; (b) exploration of the local island axillary skin use in form of subcutaneous pedicle local flap for axilla suspension and wounds beside the flap skin grafting and (c) exploration of the axillary local scar in form of subcutaneous pedicle flap for axilla suspension; wounds beside the flaps were covered with skin transplants.

Total shoulder adduction contracture elimination with thoracodorsal pedicle flaps (Figures 5-7): Sixteen patients, children and adults, having total shoulder adduction contractures, were operated using the thoracodorsal narrow small pedicle flaps. Planning, surgery, technique and results are showing in Figures (5a-d; 6a-e; 7a-c). For a full contracture release, scars were dissected with a Y-incision (Figure 5a) through axilla in anterior-posterior direction to the joint rotation axis ("+" symbol).

As a result, a huge wound appeared (Figures 4d,e; 5c; 6b). The flap's pedicle was planned maximally close to the joint rotation axis ("+", Figures 5b,7a). The flap's size was planned of the size that donor wound could be primarily closed. In our patients, it was impossible to elevate the thoracodorsal flap that could be enough to cover the entire wound and compensate scar surface deficit. The mobilized flap was narrow and covered the central part of the wound (flexion zone) of axilla and joint flexion lateral (FL) surfaces, so that the end of the extended flap reached the

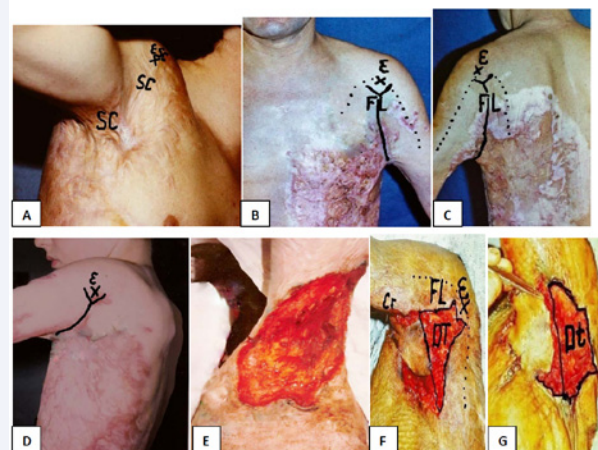


Figure 4 Total shoulder contracture anatomy. (A) Scars cover all joint flexion surface without a fold; shoulder free, scar surface in axilla projection; (B, C, next case) shoulder fused with chest wall: anatomy marked and Y-lines for scars dissection; (D, E, next case) total shoulder contracture, huge wound after contracted scars dissection with Y-incisions; (F, G) Big trapezoid wound of scars on joint FL surface up to the joint rotation axis.

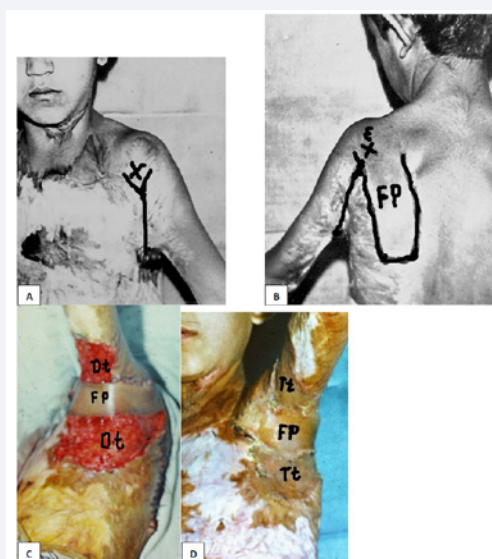


Figure 5 Total left shoulder contracture elimination with new method, using narrow thoracodorsal flap and skin transplants. (A, B) Before surgery, planning: Y-incision; "+"- joint rotation axis, thoracodorsal flap with pedicle at the joint rotation axis level; (C) huge wound or scar surface deficit, flap covered and suspended axilla, big wound beside the flap was covered with whole skin transplants. (D) Result. FP- flap; Tt- skin transplant

joint rotation axis level (Figures 5c,6c). The big wounds beside the flap, on shoulder inner surface and lateral chest wall, were covered with skin transplants (Figures 5d; 6c, d; 7c). The Figure 6 is showing that scars were located on the joint rotation axis and flap's pedicle was displaced to spine and downward and changed form of posterior edge of axilla (Figure 6c-e). After axillary scar flaps development, the thoracic flaps were used as an exception, one of which was ulcers of scars in the axilla (Figure 7).

Axillary island skin in the form of a flap suspending axilla (Figures 8-10): The island of healthy skin was preserved in cupola as a result of shoulder adduction during burns. Healthy island skin had two forms: immured by scars displaced downwards/distally and contracted over saved island skin. As result, the immured skin formed a cavity connecting through small orifice with external space (Figs. 8a; 9a). The open island skin was surrounded by scars (Figure 10a-c).

Planning: the orifice marked and two Y-lines from orifice to the joint rotation axis (+) anteriorly and posteriorly for contracted scars incision (Figures 8a,b; 9a,b). The transformation of immured island skin into a flap was done by separating skin of the orifice from scars. Then, contracted scars were dissected from the orifice in anterior and posterior direction to the joint rotation axis with a Y-incision. Before joint rotation axis, the ends of incisions were split (Y-incision) and continued along the line separating the scars of flexion lateral (FL) surfaces from tissues of the joint extension surface (E). For easy wound edges' divergence and full contracture release, the scars located on the joint FL surface needed to be separated from the tissue of the joint extension surface (E) which was achieved with a Y-incision of contracted scars. After shoulder abduction and easy wound edges' divergence, the wound on the joint flexion lateral surfaces (FL) accepted, as a rule, trapezoid form (Figures 4f,g; 8c; 10b).

The skin was mobilized from the periphery and displaced on the axillary bottom. Then, the skin was dissected from shoulder and thoracic sides, leaving a bridge 4-6 cm in a width; for flap elongation, addition counter incisions were made on different level (Figure 8d, scheme). The anterior end of the flap was transposed with tension on the joint anterior FL surface and connected with the wound's edge at the joint rotation axis level (Figures 8e; 9c). Using tension, posterior end of the flap was transposed on the joint FL posterior surface and was sutured to the wound's edge. Thus, the huge wound was divided into two: shoulder and thoracic which were located beside the flaps and covered with whole skin transplants (Figures 8f, g). No special immobilization was necessary. Excellent outcomes is showing in Figure 8h.

In cases where axillary island skin was opened (Figure 10a-c), the scar surface deficit was less expressed. The island skin in the form of a subcutaneous pedicle flap was extended in anterior-posterior direction; the ends of the flap were sutured to the wound's edge, suspending the axilla. The wounds beside the flap were covered with local tissues of shoulder and chest wall, having surface surplus, or covered with skin transplants.

Suspension of the axilla with axillary local scar subcutaneous pedicle quadrangular flap and wounds skin grafted in total shoulder contracture treatment (Figures

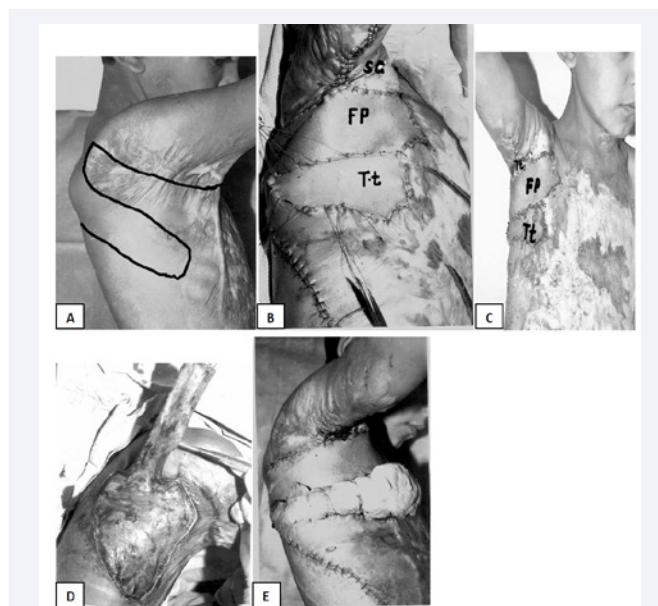


Figure 6 Total shoulder contracture elimination with thoracodorsal flap and skin transplant; pedicle of flap displaced low and posteriorly. (A) Planning of surgery; (B,C,D) operation. (E) Results: normal flap and skin transplant (FP, Tt), contracture fully released without re-contracture; low position of the flap in posterior axilla.

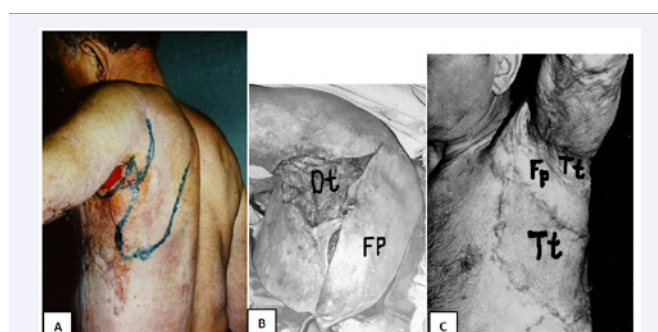


Figure 7 Elimination of the total shoulder contracture complicated by ulcerous scars of axilla, by scars excision with ulcers, axilla suspension with narrow thoracodorsal flap and wound resurfacing with skin transplants. (A) Pre surgery, flap marked, good position of flap's pedicle; (B) surgery; (C) contracture eliminated, no re-contracture, normal quality of skin transplant and flap.

11-13): In half of our patients with total shoulder adduction contractures, the donor sites of thoracodorsal flaps were injured. The island skin in axillary cupola was rarely preserved; axilla fusion with the chest wall also formed rarely.

The flap was planned in the axilla and two Y- lines were marked for scars' dissection from the flap's ends to the joint rotation axis (Figures 11a; 12b; 13a). Contracted scars were dissected with two Y-incisions following the marked lines from the ends of the flap to the joint rotation axis anteriorly and posteriorly, separating contracted scars from tissues of the joint extension surface (Figures 11a,b). After shoulder abduction, the flap was mobilized from periphery, separated from muscles forming the edges of fossa and displaced to the axillary bottom. Pedicle of the flap was cupola of axilla.

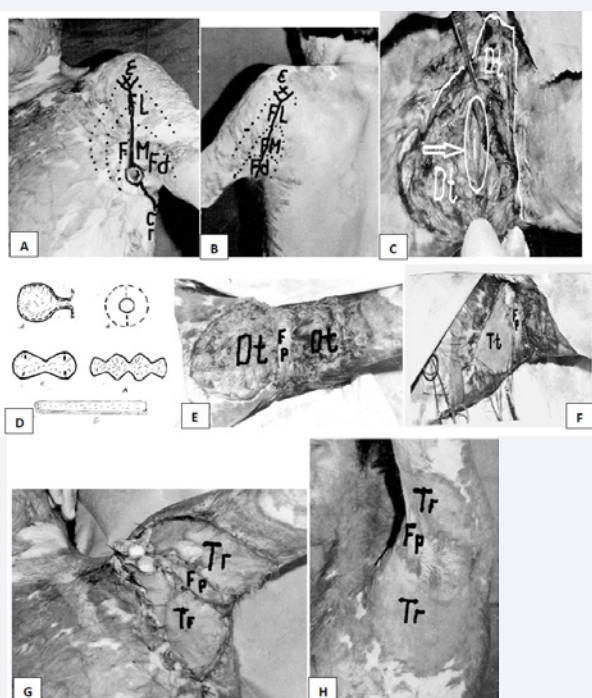


Figure 8 Total shoulder adduction contracture treatment using axilla suspension with immured island axillary healthy skin and wounds skin grafting. (A, B) Before surgery: wide scars, axilla displaced downward; small orifice leading to immured skin; planning: lines around orifice and for contracture release by scars dissection with Y-incisions from orifice to the joint rotation axis, end of lines are split for easy scar edges divergence; (C) scars dissected, huge wound or scar surface deficit; in wound's center- orifice and island skin – "I", at joint FL surfaces wound has trapezoid form (Dt); (D) converting healthy skin in long flap (scheme); (E) immured healthy skin converted into a stripped subcutaneous pedicle flap (FP), its ends connected with wound edges on anterior and posterior at the level joint rotation axis; axilla suspended, large wound divided into two: thoracic and shoulder; (F,G) wounds beside the flap covered with whole skin transplants (Tt); (H) two years after reconstruction: full shoulder abduction, flap (island healthy skin) became two times wider, hair grows, skin transplants look as normal skin; axillary fossa restored.

The Y-ends of the incisions allowed divergence of wound edges and wound at the joint rotation axis accepted a trapezoid form to which the ends of the flap were sutured (Figure 11b). Due to flap extension, the axilla was suspended with some over correction (Figure 11b), the axillary fossa edges approached, and the most surface of the flap displaced on joint FL surfaces and the flap's ends achieved the joint rotation axis level. The flap, suspending the axilla, divided the huge wound into two big wounds: shoulder and thoracic which were resurfaced with whole skin transplants fixated by tie-over dressing (Figures 11c,d; 12c). No special immobilization was needed.

Due to flap tension, the soft tissues in the joint zone were squeezed and the edges of fossa reached each other; the tissues of the joint extension surfaces (E) were extended and displaced on the joint FL surfaces. These factors made the wound and scar surface deficit smaller and allowed for the ends of a relatively short flap reach the wound's edges and stably suspend the axilla).

Total shoulder contracture can be combined with severe breast deformation (Figure 12a). First, the shoulder contracture

was eliminated using the new method (Figure 12b,c); then, the breast was restored using original technique (Figure 12d). Excellent results were achieved (Figure 12e).

If shoulder contracture and scar surface deficit were less expressed (Figure 13a), the quadrangular adipose-scar subcutaneous pedicle flap suspended axilla and covered part of axillary wound. The wounds beside the flap were primarily closed (Figure 13a-c).

RESULTS OF INVESTIGATION

The most important result of researches was finding a solution to the problem of complete total should adduction contractures treatment, one of the challenging in the rehabilitation of patients with big joint's scar contractures. In 56 of 58 patient cases, total shoulder adduction contractures were eliminated fully, re-contracture not noticed and re-operation was not needed. In two cases posterior edge of axilla was incomplete restored (Figure 6). After operation, no complications took place. All flaps and skin transplants were alive. Flaps stable suspended axilla, skin transplants compensated scar surface deficit and restored the skin of axillary region without signs of shrinkage. The flaps had steady blood circulation and transposition with tension was not dangerous. The technique with the axillary scar and skin flaps

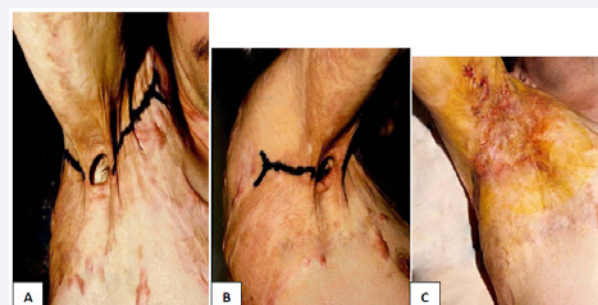


Figure 9 Total shoulder adduction contracture treatment using new technique-immured island healthy skin and local tissue. (A, B) before operation: wide spreading scars, axilla fossa smoothed, displaced downward; in axilla center a small orifice, leading to cavity, formed with immured skin; planning as in previous case; (C) ten days after operation: island of healthy skin converted into long subcutaneous pedicle flap edges of which connected with wound edges; wounds beside the flap primarily closed; flap alive, contracture fully released.

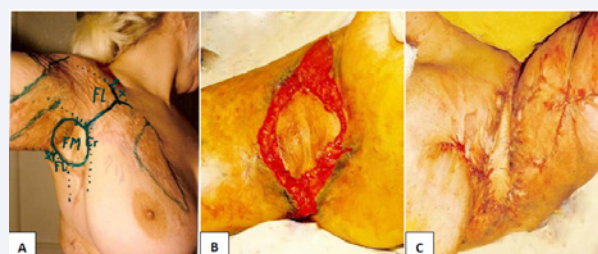


Figure 10 Shoulder adduction contracture treatment by axilla suspension using open preserved healthy skin in axillary cupola. (A) Prior to surgery, planning; (B) contracture released and island healthy skin separated from scars; (C) flap ends sutured with wound edges and suspended axilla; wounds beside the flap primarily closed; seven days after operation: flap alive, contracture fully released.

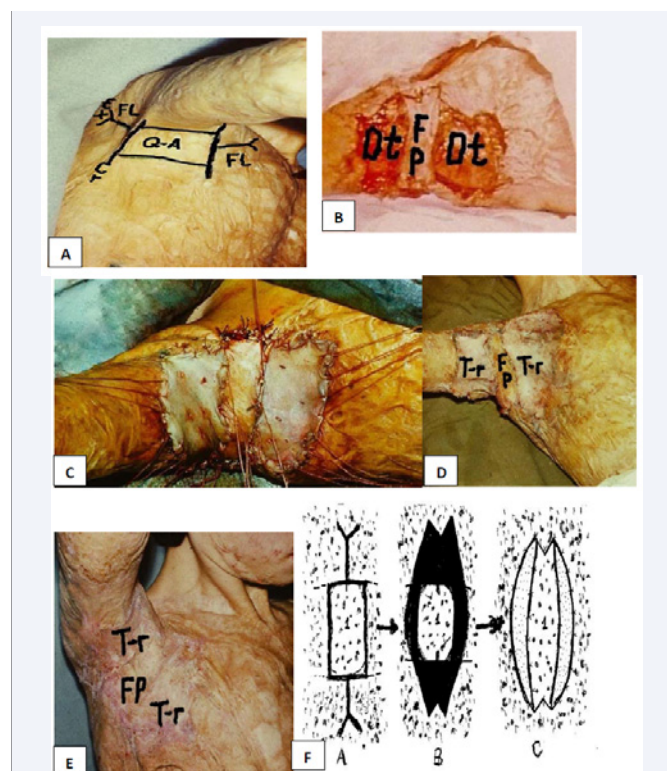


Figure 11 New surgical technique in total shoulder adduction scar contracture elimination with quadrangular local subcutaneous pedicle scar flap and skin transplants. (A) Before surgery, vast scars; planning: quadrangular flap in axilla and two Y-lines from flap's ends to the joint rotation axis. (B) scars dissected, flap in axillary fossa projection displaced to axillary bottom; big wound occupies all axillary area and lateral shoulder joint surfaces up to joint rotation axis; flap mobilized around and displaced to the axillary bottom; flap's edges connected with wound edges on joint rotation level; axilla suspended, big wound divided on two parts. (C) Wounds beside the flap covered with skin transplants; (D) Two weeks after operation: flap and skin transplants alive, no complications; (E) Follow-up result: flap -FP- and skin transplants -Tr- increased in size, no skin transplants shrinkage and signs of re-contracture; (F) scheme of operation.

use was minimally traumatic and children well tolerated surgery. Comparison surgery of 3 groups showed that the use flaps from axilla (scars and skin) makes new method less traumatic, not injury thoracic wall. Therefore, narrow thoracic flap is used when shoulder fused with thoracic wall and an ulcer appears in axilla (Figure 4b, c; 7a-c). According to our data, the axillary skin and scar quadrangular subcutaneous pedicle flaps were more preferable than other methods (Figures 11e; 12e; 13c).

DISCUSSION

The review of literature and our multiple clinical observations showed that there are problems related to total shoulder contractures treatment. The shrinkage of skin transplants in axilla and re-contractures are well known [6]; only some authors reported of the use of skin transplants [7]. Dogra et al. [8], wider and dense scars in axilla release/excised and skin grafted.

Severe shoulder contractures Zhang et al. [9], reversed the Z-plasty and its variations; and Yotsuyanagi et al. [10], used double combined Z-plasty for wide-scar contracture release.

The treatment of shoulder contractures techniques is

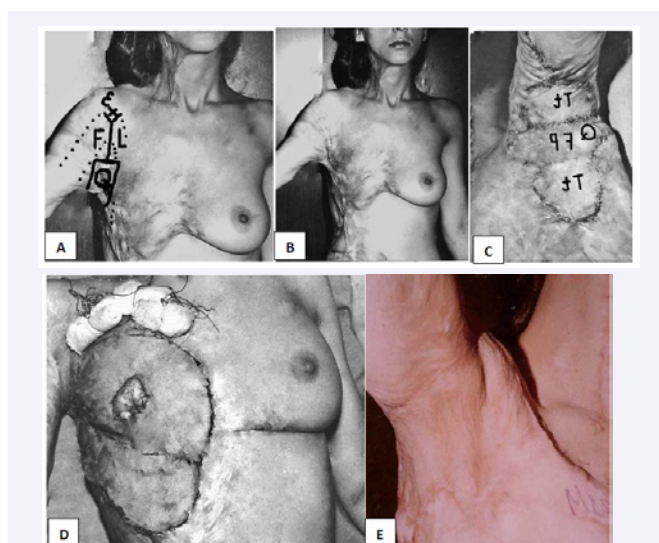


Figure 12 Total right shoulder adduction contracture elimination with quadrangular axillary local scar flap and skin transplants, and severe deformed breast reconstruction using original technique. (A, B) Before surgery: anatomy and planning: flap marked in axilla projection; Y-incision of contracted on FL surface scars up to joint rotation axis anteriorly and posteriorly; (C) Flap (FP) suspended axilla and divided huge wound on two; wounds beside the flap covered with skin transplants (Tt) (10 days after operation); (D) Ten days after breast restoration; mobilized breast tissues formed with forming sutures on 3 levels and covered with skin transplants; (E) excellent follow-up result.

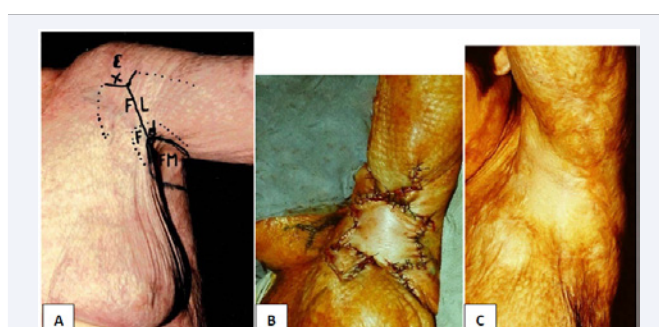

Figure 13 Total shoulder left contracture elimination with quadrangular local scars and primarily wounds closure with whole skin transplants. (A) Pre surgery, was skin transplant burns treated; typical planning flap and contracted scars dissection with Y-incisions up to the joint rotation axis anteriorly and posteriorly; (B) End of operation: flap suspended axilla and covered most parts of fossa; wounds beside the flap primarily closed; (C) contracture eliminated, axilla restored, flap increased and looks as healthy skin; full shoulder abduction.

connected with the anatomy form or type of contracture. There are two known classifications of contractures: numeric -3-type and 4-type [11,12] and literal name reflecting one of external features of scars causing the contracture) using by most authors. Ogawa and Pribaz [13] classified scar contractures into 5 numeric types and 13 subtypes. Karki et al. [7], operated shoulder scar contractures in 44 patients and classified on the anterior axillary fold, posterior fold, both folds and axillary fossa (total contracture, our remark), and both folds plus part of the chest wall and arm (sparing the axillary fossa).

The following are some of the names of these types: single,

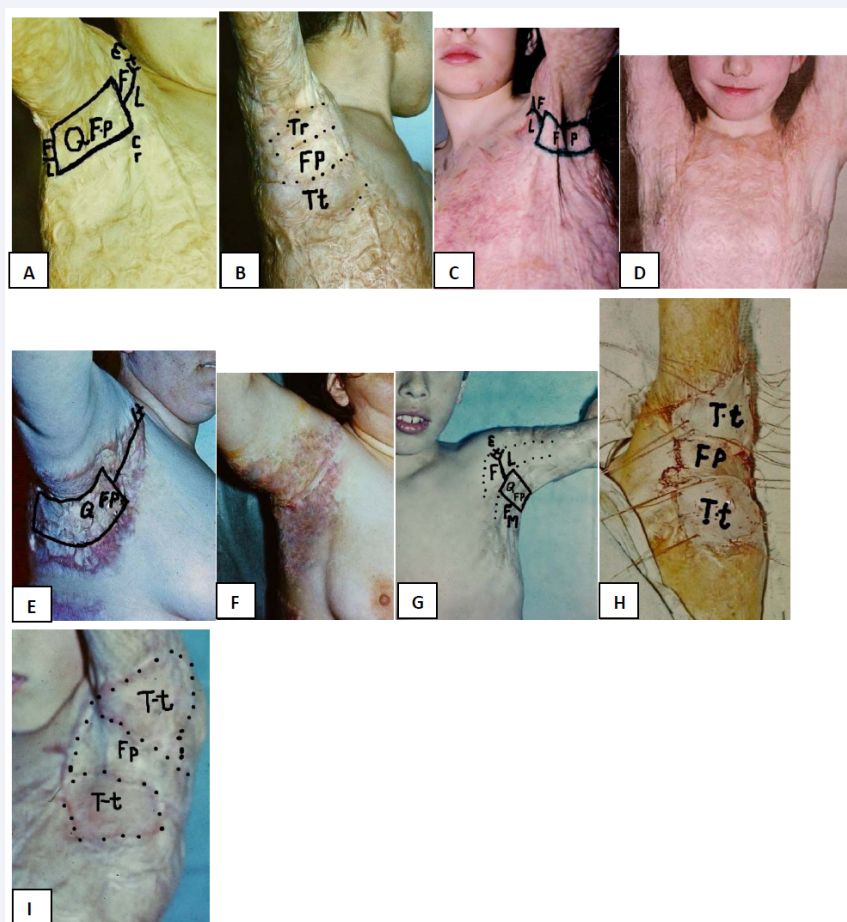

Figure 14 Follow-up results of total shoulder adduction contractures elimination in children and adult with axillary quadrangular scar subcutaneous pedicle flap and skin transplants. A, B (first case. Planning and result). Before and after surgery; contracture removed. C, D (second case, planning and result). Contracture eliminated. E, F (third case; planning and result). Contracture fully released, axilla restored. G-I (fourth case, before surgery, operation end result). Contracture removed in all patients: axilla restored. No complications; flaps stable suspended axilla, skin transplants without shrinkage. No signs of re-contracture.

linear, double linear. If a contracture is found between linear contractures, all contracture should be excised and reconstructed with local or regional flap from the chest wall or dorsal region (Type IIIA); broad bent contracture- scars cover the axillary area and over the axillary area. Presented data showed that the implementation of numeric classifications is difficult as borders/ location of scars causing a concrete type is not determined; all classifications are not complete as the medial type of contracture is not included (author's remark).

In 1991 [4], personally developed anatomic classification was presented that categorized all scar contractures into three types: edge; medial, and total, regardless of their location and severity. This classification became the basis for diagnose of the contracture type, choice of surgical technique, and development of new methods of operations that would elevate the rehabilitation level of burned patients.

Most authors labeled contractures using specific signs of contracted scars. Among them there are names of shoulder adduction contractures treated with thoracodorsal flaps: (a) Severe shoulder scar contractures [2,15,16]; (b) Wide shoulder scar contracture [9,10]; (c) Broad scar contractures

[17]; (d) Broad based contracture [18]; (e) Broader, diffuse contractures [19]; Broadbent [13].

Having reviewed this material, a conclusion was made that if shoulder contractures, named as severe or wide and diffuse or dense and caused with scars located in axilla only and treated with thoracodorsal flaps, these contractures, obviously, belonged to medial type (not total) and were easy treated with local flaps and trapeze-flap plasty [4] (Figure 3). For example, Tanaka et al. [15], evaluated 13 consecutive cases of severe burn scar contracture of the axilla and investigated the factors that influenced functional improvement after surgery. The scar contractures in the axilla were released in all cases and the defects of the axillary region were covered with musculocutaneous flaps or fascia-cutaneous flaps.

Shoulder contractures having a name type are: thoracodorsal perforator flaps [1]; Pre-expanded pedicle thoracodorsal artery perforator flap [2]; Parascapular flap [7]; musculocutaneous, fasciocutaneous flaps [15]; Transverse island scapular flap in adult and pediatric patients [16]; Perforator-based interposition flaps for sustainable scar contracture release [17]; Thoracodorsal perforator island flap [20,24]; Extended lower trapezius island

myocutaneous flap [21]; Extended island lower trapezius myocutaneous flap [22]; Thoracic fascia-cutaneous flap [23]; Thoracodorsal perforator island flap [24]; Quadrangular local scar subcutaneous pedicle flap [26]; Perforator-based interposition flaps [19]; authors reported that good functional and satisfactory cosmetic outcomes received. Contracture, obviously, were released with flaps per se, without skin transplants.

Our experience showed that the use large size of thoracic flaps is not justified for scar surface deficit compensation: after elevation of huge flap a tissue defect appears and deformity of chest wall after donor wound skin grafting. If a flap was smaller than the wound, incomplete contracture release and shoulder abduction could appear. Usually, burns causing total shoulder contractures were restricted of skin injury. If flaps contained all fat layer or included fascia and muscle, the excess of soft tissues in axilla could appear.

Obviously, the medial contractures were included to patients having such name as severe, wide, and broad at al. and treated with thoracodorsal flaps instead local trapezoid flaps. Total shoulder contractures were eliminated with new method--local scar subcutaneous pedicle flap in conjunction with skin transplants, where thoracic flaps were not needed.

Analysis of outcomes showed that the thoracodorsal flaps use not solved problem of total shoulder scar contractures elimination. Stekelenburg et al. [5], explored the efficacy of shoulder scar contractures treatment with different techniques and concluded that, at present, no consensus existed on the technique to be used; no definite conclusions could be reached about the effectiveness of different techniques; therefore, no direct implication for daily practice could be made. Two years later, Stekelenburg et al. [19], evaluated several results of shoulder contracture treatment using the new technique of thoracic flaps elevation and concluded that the use of thoracic perforator-based flaps was promising; however, their true clinical significance for this type of burn reconstructions still needs to be determined.

CONCLUSION

The new method based on next new anatomic-clinical factors allows total shoulder adduction contractures elimination. A simple technique based on the use axillary local subcutaneous pedicle scar or island skin flaps and skin transplants. The method is based on new principles: the flap's main roles are: the axilla suspension, coverage in axilla a zone of shoulder flexion/adduction, division huge wound on two - shoulder and thoracic, prevention skin transplants shrinkage and contracture recurrence. The skin transplant, being excluded as method of total shoulder contracture treatment, became the main remedy in wound covering, scar surface deficit compensation, and skin of axilla restoration. These factors restore all functions of shoulder joint, anatomy of axilla, and allow normal upper extremity development in children as first step of total shoulders car adduction contractures treatment.

REFERENCES

1. Nisanci M, Altıparmak M, Sahin I, Kasap S. A Wise Surgical Approach for Reconstruction of Postburn Axillary Contractures and Versatility of Perforator Flaps. *J Burn Care Res.* 2018; 39: 332-338.
2. Kulahci Y, Sever C, Uygur F, Oksuz S, Sahin C, Duman H. Pre-expanded pedicled thoracodorsal artery perforator flap for postburn axillary contracture reconstruction. *Microsurgery.* 2011; 31: 26-31.
3. Turkaslan T, Turan A, Dayicioglu D, Ozsoy Z. Uses of scapular island flap in pediatric axillary burn contractures. *Burns.* 2006; 32: 885-890.
4. Grishkevich V. The basic types of scar contractures after burns and methods of eliminating them with trapezeplasty flaps. *Plast Reconstr Surg.* 1991; 88: 1044-1054.
5. Stekelenburg CM, Marck RE, Tuinebreijer WE, de Vet HC, Ogawa R, van Zuijlen PP. A systematic review on burn scar contracture treatment: searching for evidence. *J Burn Care Res.* 2015; 36: 153-161.
6. Olaitan P, Onah I, Udezue A, Duru N. Surgical options for axillary contractures. *Internet J Plast Surg.* 2007; 3: 154-158.
7. Karki D, Mehta N, Narayan RP. Post-burn axillary contracture: A therapeutic challenge! *Indian J Plast Surg.* 2014; 47: 375-380.
8. Dogra BB, Kataria M, Kandari A, Ahmed S, Singh A, Virmani R. Management of postburn contractures of upper extremities: A general surgeon's perspective. *Indian J Burns.* 2016; 24: 29-35.
9. Zhang L, Jin R, Shi YM, Sun BS, Pu ZM, Zhang YG. Reversed Z-plasty and its variations to release wide-scar contraction. *Burns.* 2014; 40: 1185-1188.
10. Yotsuyanagi T, Yamashita K, Gonda A, Kato S, Sugai A, Yamada T, et al. Double combined Z-plasty for wide-scar contracture release. *J Plast Reconstr Aesthet Surg.* 2013; 66: 629-633.
11. Kurtzman LC, Stern PJ. Upper extremity burn contractures. *Hand Clin.* 1990; 6: 261-279.
12. Hallock GG. A systematic approach to flap selection for the axillary burn contracture. *J Burn Care Rehabil.* 1993; 14: 343-347.
13. Ogawa R, Pribaz JJ. Diagnosis, assessment, and classification of scar contractures. In: Hyakusoku H, Orgill DP, Teot L. *Color atlas of burn reconstructive surgery.* Berlin Heidelberg: Springer-Verlag. 2010; 44-60.
14. Walash A, Kishk T, Ghareeb FM. Treatment of postburn axillary contracture. *Menoufia Medical J.* 2014; 267: 278-283.
15. Tanaka A, Hatoko M, Tada H, Kuwahara M. An evaluation of functional improvement following surgical corrections of severe burn scar contracture in the axilla. *Burns.* 2003; 29: 153-157.
16. Chen B, Xu M, Chai J, Song H, Gao Q. Surgical treatment of severe or moderate axillary burn scar contracture with transverse island scapular flap and expanded transverse island scapular flap in adult and pediatric patients--A clinical experience of 15 cases. *Burns.* 2015; 4: 872-880.
17. Verhaegen PD, Stekelenburg CM, van Trier AJ, Schade FB, van Zuijlen PP. Perforator-based interposition flaps for sustainable scar contracture release: a versatile, practical, and safe technique. *Plast Reconstr Surg.* 2011; 127: 1524-1532.
18. Cauley RP, Hickey SA, Hultman CS, Mathews K, Goverman J. STAR plasty for Reconstruction of the Burned Axilla. *Ann Plast Surg.* 2017; 78: 269-273.
19. Stekelenburg CM, Jaspers ME, Jongen SJ, Baas DC, Gardien KL, Hiddingh J, et al. Perforator-Based Interposition Flaps Perform Better Than Full-Thickness Grafts for the Release of Burn Scar Contractures: A Multicenter Randomized Controlled Trial. *Plast Reconstr Surg.* 2017; 139: 501-509.
20. ErE, Ucar C. Reconstruction of axillary contractures with thoracodorsal perforator island flap. *Burns.* 2005; 31: 726-730.
21. Tan KCh, Tan BK. Extended lower trapezius island myocutaneous flap

- in the repair of postburn axillary contracture. *Plast Reconstr Surg.* 2004; 113: 2082-2084.
22. Elshaer WM. Extended lower trapezius island myocutaneous flap in the repair of postburn axillary contracture. *Plast Reconstr Surg.* 2004; 113: 2076-2081.
23. Sakr WM, Mageed MA, El Moez W, Ismail M. Options for treatment of postburn axillary contractures. *Egypt J Plast Reconstr Surg.* 2007; 31: 63-71.
24. Duncan SFM, Smith AA. Treatment of the burned axilla. In: Sood R, editor. *Achauer and Soods burn surgery. Reconstruction and rehabilitation.* Philadelphia. PA: W. B. Saunders. 2006; 282-98.

Cite this article

Grishkevich VM (2018) Step-by-Step of New Method Development for Treatment of Postburn total (Severe) Shoulder Adduction Contractures: Anatomic Substantiation and Results, winter or summer. *JSM Burns Trauma* 3(2): 1044.