

Clinical Image

Right Heart Compression Caused by Polycystic Kidney Disease

Sang-Hoon Seol*

Department of Internal Medicine, Inje University College of Medicine, South Korea

A 65-year-old woman with a past history of hypertension who was referred to our hospital for evaluation of dyspnea, fatigue. She was diagnosed polycystic kidney disease for 15 years and started hemodialysis using left forearm at 55 years of age. Physical examination demonstrated heart rate 110 beats/min, blood pressure 100/60 mm Hg, temperature 36.7°C. Electrocardiogram showed sinus tachycardia. Chest X-ray revealed an elevated right diaphragm (Figure 1). Echocardiography showed external compression of the right atrium and ventricle (Figure 2). Chest-abdominal CT showed innumerable sized hepatic cysts with

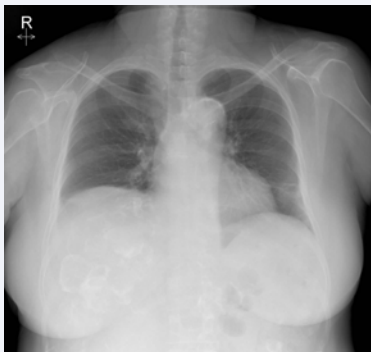


Figure 1 Chest X-ray showed an elevated right diaphragm

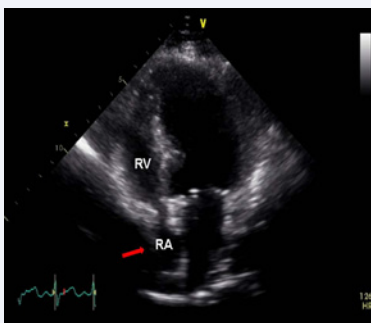


Figure 2 Transthoracic echocardiography showed external compression of the right heart by massive hepatomegaly (arrow). RA: Right Atrium; RV: Right Ventricle.

*Corresponding author

Sang-Hoon Seol, Department of Medicine, Inje University College of Medicine, Haundae Paik Hospital, 1435 Jwa-dong, Haeundae-gu, Busan, 612-030, South Korea, Tel: (82-51)-797-3070; Fax: (82-51)-797-3009; Email: hacemed@hanmail.net

Submitted: 31 December 2016

Accepted: 16 January 2017

Published: 19 January 2017

Copyright

© 2017 Seol

OPEN ACCESS

Keywords

- Right heart
- Compression
- Polycystic kidney disease
- Hepatomegaly

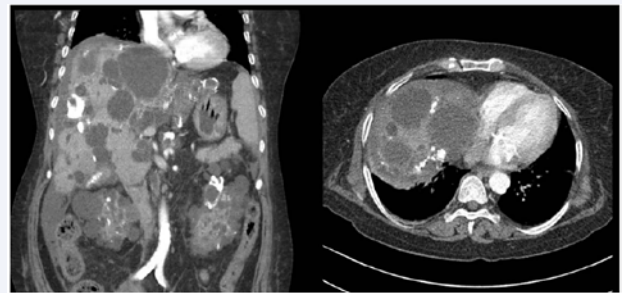


Figure 3 Chest-abdominal CT demonstrated massively enlarged liver compressed the right heart chamber.

some of thick wall calcification in massively enlarged liver and multiple cysts with wall calcification in both kidneys. The right heart chamber was externally compressed by the huge hepatomegaly (Figure 3). We decided to treat medically due to multiple extensive lesions of liver, kidney. The patient was followed closely with regular hemodialysis treatment. Polycystic kidney disease is characterized by progressive cyst development and both enlarged kidneys with various cysts. The cysts are often seen in massive enlargement of the liver [1,2].

REFERENCES

1. Nikolić M, Mathewson P, Malhotra A, Belham M. Unusual cause of right heart compression. *Cardiol J*. 2012; 19: 441-442.
2. Lasic LB, DeVita MV, Spiegel PJ, Marino ND, Mellow E, Michelis MF. Refractory hypotension and edema caused by right atrial compression in a woman with polycystic kidney disease. *Am J Kidney Dis*. 2004; 43: 13-17.

Cite this article

Seol SH (2017) Right Heart Compression Caused by Polycystic Kidney Disease. *J Cardiol Clin Res* 5(1): 1092.