

## Case Report

# Persistent Left Superior Vena Cava with Absent Right Superior Vena Cava: Lead Extraction and New Implant

Hector A. Mazzetti\* and Jorge Gonzalez-Zuelgaray

Instituto de Investigaciones Cardiológicas "Prof. Dr. Alberto C. Taquini", University of Buenos Aires, Argentina

## \*Corresponding author

Hector A. Mazzetti, Instituto de Investigaciones Cardiológicas "Prof. Dr. Alberto C. Taquini", University of Buenos Aires, Address: Santiago del Estero 1620, 1824 Lanus (Prov. Buenos Aires), Argentina, Tel: 54 9 11 4407-9932; Fax: 54 11 4240-1071; Email: hmazzetti@intramed.net

Submitted: 15 February 2017

Accepted: 22 March 2017

Published: 24 March 2017

ISSN: 2378-9565

Copyright

© 2017 Mazzetti et al.

OPEN ACCESS

## ABBREVIATIONS

DDDR: Dual Chamber Rate Responsive; PLSVC: Persistent Left Superior Vena Cava

## INTRODUCTION

Persistent left superior vena cava (PLSVC) is caused by an abnormal embryologic development, with a prevalence in the general population of 0.1-0.3% [1]. The presence of a PLSVC associated with absence of its right-sided counterpart is seen approximately in 10% of all cases of PLSVC, as a consequence of the persistence of the left anterior cardinal vein and the obliteration both of the common cardinal vein and of the proximal portion of the anterior cardinal vein (on the right) [1-3].

## CASE REPORT

A 54-year old man with symptomatic 2:1 AV block had a DDDR pacemaker implanted in May 2012 through a left sided approach, although the atrial lead could not be placed (Figure 1a) due to lack of experience with the implantation through a PLSVC. After a revision of the pocket in September 2013, oral antibiotics were given followed by transient improvement. Both procedures were carried out in another institution.

The patient came to our pacemaker clinic in August 2014 due to pocket infection of the pacemaker. Antibiotics were initiated and he was told about the necessity of extraction of the whole system, but the patient refused this option.

A PLSVC with absence of the right superior vena cava was observed in a venography (Figure 1b). We assume the coronary sinus was markedly dilated as -despite the image of the venography was interrupted at the junction between the coronary sinus and the PLSVC- the diameter of both structures must have been similar because there was no venous hypertension in the absence of right superior vena cava. The laboratory examinations were all normal.

As there was no improvement, the removal of the entire

stimulation system was finally performed in January 2015. The procedure was carried out in the operation room and cardiac surgeons were available. Due to the expected difficulty to progress the sheaths from the atrium to the ventricle, teflon sheaths (more flexible than polypropylene) were available. We used a locking stylet (Liberator®, Cook Medical, Bloomington, IN) and with gentle traction the lead came out easily without using the sheaths.

The patient remained in the Coronary Care Unit with complete AV block and a ventricular escape rhythm with a rate of 35 beats/minute. A negative-coagulase staphylococcus (sensitive to cefazolin and rifampicin) was identified and treatment with both drugs was initiated until the implantation. A Medtronic Versa DDDR pacemaker with two active fixation Medtronic 5076 leads was implanted in a second procedure through a right-sided cephalic venous cutdown. The atrial lead was located with the "J" stylet and a wide curvature was given to the stylet for the ventricular lead (Figure 1c), with adequate pacing and sensing parameters in both locations. The evolution of the patient has been uneventful after 25-months follow-up.

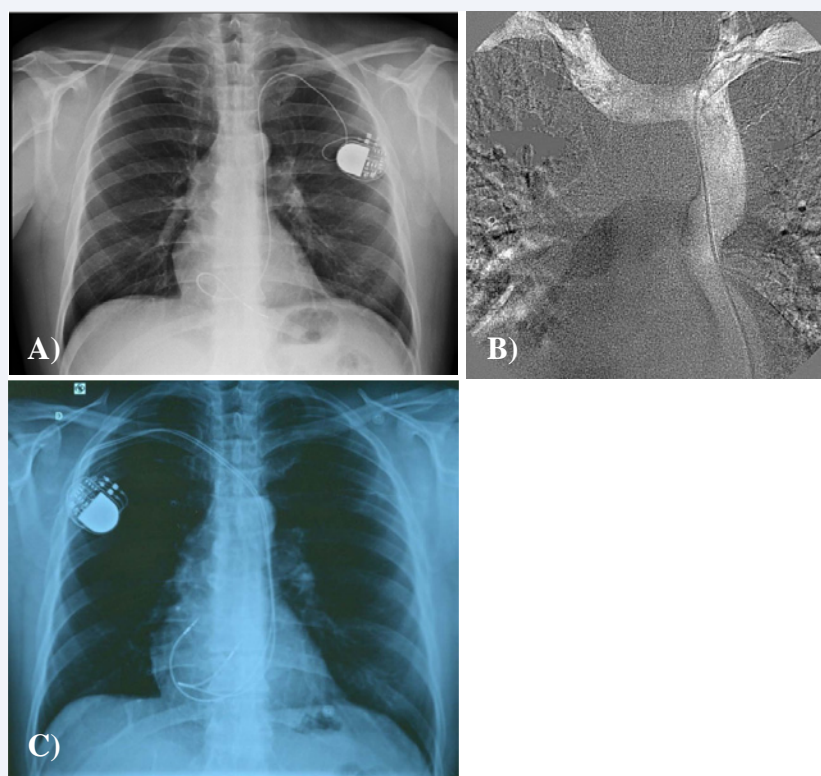
## DISCUSSION

The experience in the extraction of coronary sinus leads has shown few adhesions in wires with short implant duration (32 months in this patient). Anyway, careful preparation is essential in the event of a serious case of perforation at an unfavorable site (e.g., PLSVC nearby the coronary sinus) as this location is challenging to reach for emergency surgery. Another crucial binding site may be located at the free wall of the right atrium when the RV lead is formed as a figure of "α". Extensive and wide adhesion sites may be difficult to overcome.

We consider it is more dangerous to remove the lead if a 180° loop of the sheath must be attempted.

## CONCLUSION

The extraction of a lead through a PLSVC after a left pocket



**Figure 1** a) The absence of a superior vena cava and the PLSVC can be appreciated in the chest X-ray. b) Venography with absent right superior vena cava. c) Chest X-ray, showing the final position of the leads.

infection followed by a new implantation through the same PLSVC and from the right side (in the absence of a right superior vena cava) has not been reported previously.

## REFERENCES

1. Lacuey G, Ureña M, Martínez Basterra J, Basterra N. Vena cava superior izquierda persistente. Implicaciones en la cateterización venosa central. *An Sist Sanit Navar*. 2009; 32: 103-106.
2. Ottone N, Domínguez M, Shinzato S, Blasi E. Vena cava superior izquierda persistente con ausencia de la vena cava superior derecha. *Rev Arg Anat Online*. 2010; 1: 24-27.
3. Uçar O, Paşaoğlu L, Çiçekçioğlu H, Vural M, Kocaoğlu I, Aydoğdu S. Persistent left superior vena cava with absent right superior vena cava: a case report and review of the literature. *Cardiovasc J Afr*. 2010; 21: 164-166.

## Cite this article

Mazzetti HA, Gonzalez-Zuelgaray J (2017) Persistent Left Superior Vena Cava with Absent Right Superior Vena Cava: Lead Extraction and New Implant. *JSM Cardiothorac Surg* 2(1): 1007.