SciMedCentral

Annals of Cardiovascular Diseases

Case Report

The Durability of Handmade Fenestrated Stent Graft: The Assessment from an Extracted Endoprosthesis

Huey-Shiuan Kuo[1], Jer-Shen Chen[1,2]*

[1]*Department of Cardiovascular Surgery, Far Eastern Memorial Hospital, New Taipei City, Taiwan*

[2]*Department of healthcare administration, Asian Eastern University of Science and Technology*

***Corresponding author**

Jer-Shen Chen, Department of Cardiovascular Surgery, Far Eastern Memorial, Hospital, 13F, No. 21, Section 2, Nanya South Rd, Banqiao, New, Taipei City 220, Taiwan

Submitted: 16 October 2022

Accepted: 01 December 2022

Published: 03 December 2022

ISSN: 2641-7731

Abstract

Physician-modified endovascular prosthesis has been developed to treat aortic disease in variable situations. However, the durability and long-term outcomes are criticized. Here we reported some cases, who were enrolled in our case series of handmade fenestrated stent graft in 2019 and 2020 [1,2]. The aortic stent graft was extracted from the patient during a conventional open surgery due to variable reasons, and the architecture of stent graft as well as the modification was intact. The durability of handmade fenestrated stent graft was therefore being investigated and confirmed.

CASE REPORT

Case-1

Five years ago, a 27-year-old female patient experienced a severe refractory back pain and was diagnosed as acute type B dissection by computed tomography angiography(CTA) at that time. Thoracic endovascular aortic repair (TEVAR) with a single-fenestrated aortic stent graft (Zenith TX2, Cook Medical, Inc., Bloomington, IN, USA) for left subclavian artery preservation, landing at zone 2, was done successfully. A Viabahn stent graft (W. L. Gore & Associate, Flagstaff, AZ, USA) was inserted through the fenestration to left subclavian artery as branch. However, during the follow-up, progressively enlarging aortic root and dilated ascending aorta were found by regular CTA follow-up, yet no obvious endoleak from the aortic stent graft was detected (Figure 1A). Marfan syndrome was also impressed by her specific characteristics. Surgical replacement of thoracic aorta was recommended. The diseased aorta was approached via a conventional sternotomy. Intra-operatively, the previous aortic stent graft could be seen outside from the proximal descending aorta, suggesting an erosion of the fragile aortic wall in a Marfan patient (Figure 1B). The proximal part of the aortic stent graft, as 50 well as the left subclavian artery stent graft (Figure 1C), were extracted and total arch replacement was done using a frozen elephant trunk device (Thoraflex™ Hybrid prosthesis, Terumo Aortic, Vascutek Ltd., Inchinnan, UK). The patient recovered from the operation smoothly.

Figure 1a No obvious endoleak from the aortic stent graft was detected by CTA 5 years after the TEVAR, yet the patient's dilated aortic root with aortic regurgitation was surgically indicated.

Case-2

In another case of traumatic aortic dissection, the patient underwent TEVAR emergently with a double-fenestrated stent graft (Valiant Captivia, Medtronic Vascular, Santa Rosa, CA, USA) for preservation of left common carotid artery and left subclavian artery. The endoprosthesis was removed 2 years later due to stent graft infection, and the hand-made fenestration hole as well as the stent grafts in supra61 aortic branches were all intact (Figure 2).

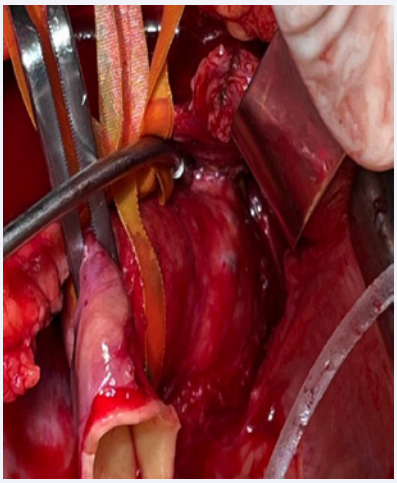

Figure 1b An erosion of the fragile aortic wall resulting from the aortic stent graft was found during the operation.

Figure 1c The proximal part of the aortic stent graft was extracted, showing the intact fenestration hole.

Figure 2 The endoprosthesis was removed 2 years after the procedure due to stent graft infection, and the hand-made double fenestration hole as well as the stent grafts in supra-aortic branches were all intact.

DISCUSSION

The physician-modified endovascular prosthesis had been developed and designed to meet various situations and aortic pathologies. In literature review, the results were satisfactory in both procedure-related complications and graft patency, although this concept lacked a standardization and it was highly dependent on operators' technique [3,4]. The durability was criticized due to its off-label manipulation. In these cases, the extracted endoprostheses were investigated. The fenestration hole, which was reinforced by the micropuncture wire and polyester sutures, was intact even after stuck by the Viabahn stent graft. In the first case, both the extracted endoprosthesis and the pre-operative image indicated the durability of the physician-modified device in a 5-year duration, respectively, despite that the fragile aortic wall were eroded by the endoprosthesis. We ever concluded that the handmade stent graft fenestration was an off-label but innovative way to treat variable aortic disease in different clinical situations with individualized management. The 2 cases provided an experience to assess the handmade fenestrated stent graft outside from the patients again, which was not resulted from any procedure-related complications or concern of graft patency but the patients' underlying condition of progressive aortic lesion. Our design of the fenestration hole, with delicate polyester suture fixation of the micropuncture wire, well tolerated the embedded Viabahn stent graft and the pressurized aortic lumen, and served as an effective treatment strategy for aortic disease.

ACKNOWLEDGEMENTS

The authors would like to thank all patients who participated in the study, colleagues and medical staff who took part in the care of patients indicated above, and reviewers and the editor for their comments.

REFERENCES

1. Kuo HS, Huang 96 JH, Chen JS. Handmade stent graft fenestration to preserve left subclavian artery in thoracic endovascular aortic repair. Eur J Cardiothorac Surg. 2019; 56: 587-594.
2. Kuo HS, Huang JH, Chen JS. Handmade fenestrated stent grafts to preserve all supra-aortic branches in thoracic endovascular aortic repair. J Thorac Cardiovasc Surg. 2020; 160: 629-639.
3. Canonge J, Jayet J, Heim F, Chakfé N, Coggia M, Coscas R, et al. Comprehensive Review of Physician Modified Aortic Stent Grafts: Technical and Clinical Outcomes. Eur J Vasc Endovasc Surg. 2021; 61: 560-569.
4. Canaud L, Morishita K, Gandet T, Sfeir J, Bommart S, Alric P, et al. Homemade fenestrated stent-graft for thoracic endovascular aortic repair of zone 2 aortic lesions. J Thorac Cardiovasc Surg. 2018; 155: 488-493.

Cite this article

Huey-Shiuan K, Jer-Shen C (2022) The Durability of Handmade Fenestrated Stent Graft: The Assessment from an Extracted Endoprosthesis. Ann Cardiovasc Dis 6(1): 1030.