

Case Report

Tubercular Dactylitis: Cytodiagnosis to Rescue- A Report of Two Cases

Shalini Bahadur, Priyanka Anand*, Aastha Narula, and Namrata Nargotra

Department of Pathology, Hindurao Hospital & NDMC Medical College, India

*Corresponding author

Priyanka Anand, Department of Pathology, Hindurao Hospital & NDMC Medical College, New Delhi, India, Tel: 0999-033-1813; Email: priyankaanand19@yahoo.com

Submitted: 08 February 2017

Accepted: 12 May 2017

Published: 15 May 2017

ISSN: 2475-9430

Copyright

© 2017 Anand et al.

Abstract

Introduction: Skeletal tuberculosis of the small tubular bones of hand and feet is less frequently encountered. It accounts for less than 1% of extra pulmonary tuberculosis with spine being the most frequent site of involvement. Small bones of hand area involved with greater frequency than the foot and condition is relatively rarer after the age of 5 years. Fine needle aspiration cytology is an inexpensive relatively non-invasive procedure that aids in early diagnosis of tubercular dactylitis.

Case reports:

Case 1: A 47 year old female presented with swelling of the left great toe for the past three months. There was a history of trauma few weeks prior to onset of swelling. On radiography there was a bony lytic lesion in the proximal phalanx of left great toe. Chest x-ray showed no abnormality. Fine needle aspiration cytology from swelling revealed granulomas. Ziehl Neelsen staining was positive for acid fast bacilli. Patient was given anti tubercular drugs for 9 months following which the swelling subsided.

Case 2: A 19 year old female patient presented with a history of painful swelling of 2 months duration in the right middle finger. Family history was not contributory. Radiographs showed an expansile lesion of right third middle phalanx. Chest X-ray was normal. Tuberculin test was strongly positive. Fine needle aspiration showed epithelioid cell clusters with multinucleated giant cells and acid fast bacilli was positive on Ziehl Neelsen staining. The patient was commenced on anti-tubercular treatment.

Conclusion: To ensure early and good functional outcome, tuberculosis should be considered in patients with soft tissue or bony lesions of small bones of hand and feet. FNAC can serve as an inexpensive and relatively less invasive procedure which helps attain diagnosis. Institution of conservative anti-tubercular treatment is cornerstone in the management of such patients.

OPEN ACCESS**Keywords**

- Tuberculosis
- Hand
- Feet
- Dactylitis
- Paucibacillary

ABBREVIATIONS

TD: Tubercular Dactylitis

INTRODUCTION

Skeletal tuberculosis of the small tubular bones of hand and feet is less frequently encountered. It accounts for less than 1% of extra pulmonary tuberculosis [1] with spine being the most frequent site of involvement. Tubercular dactylitis was first described in 1886 [2]. Hand is involved with greater frequency than the foot and is relatively rarer after the age of 5 years [3].

In hand, tuberculosis usually starts with tenosynovitis with eventual involvement of bones and joints. Diagnosis of this infectious pathology is often delayed due to insidious character of presentation and lack of definitive symptomatology [4].

Fine needle aspiration cytology is an inexpensive relatively non-invasive procedure that aids in early diagnosis of tubercular dactylitis when aided with simple ancillary stains like Ziehl

Neelsen stain and thus helps permit timely initiation of specific therapy. We hereby report two cases of tubercular dactylitis reported on fine needle aspiration cytology.

CASE PRESENTATION**Case 1**

A 47 year old female presented with swelling of the left great toe for the past three months. There was vague history of trauma few weeks prior to onset of swelling. No history of fever, cough, and night sweats, loss of appetite or weight, contact with a case of tuberculosis or family history suggestive of tuberculosis was found. On examination swelling was tender, hard with raised local temperature and appeared to arise from underlying bone. Systemic examination was unremarkable. Complete blood count revealed lymphocytosis and erythrocyte sedimentation rate was raised (48 mm in 1st hour). Serial S. Uric acid was performed twice at 15 days interval (Figure 1). It was raised initially (5.9 gm %) and later on level was borderline (5.47 gm %). Montoux test

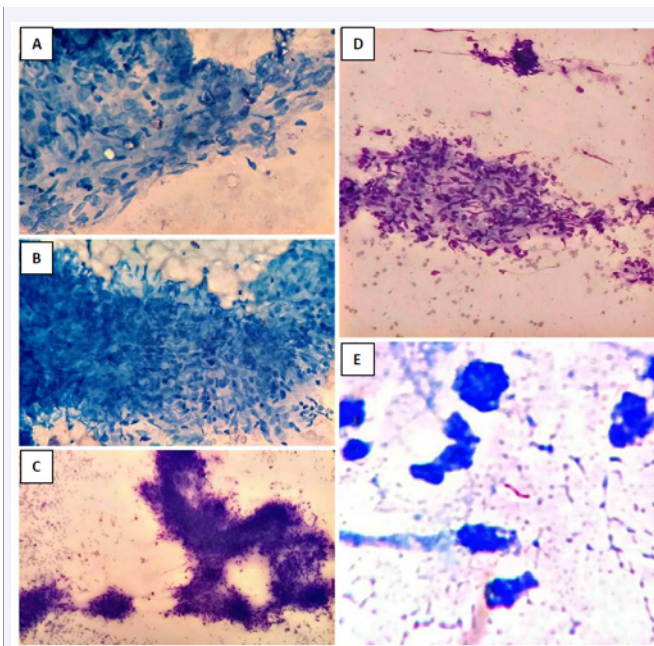


Figure 1 A) and B) - (AFB; 10X) Showing granuloma consisting of epithelioid cells and chronic inflammatory infiltrate. (MGG; 4X) Microphotograph shows well formed granulomas. (MGG; 10X) Microphotograph shows a granuloma comprising of epithelioid cells and lymphocytes. E) (AFB; 40X) Showing an acid fast bacilli which confirms a tubercular lesion.

was positive (indurations of 26mm). On radiography there was a bony lytic lesion with presence of cortical erosions in the proximal phalanx of left great toe. Chest x-ray showed no abnormality. Fine needle aspiration cytology was done from swelling left toe which revealed granulomas comprising of epithelioid cells, lymphocytes, histiocytes along with multinucleate giant cells. Ziehl Neelsen staining was positive for acid fast bacilli. Based on these findings a diagnosis of granulomatous inflammation, of tubercular nature (tubercular dactylitis) was made.

Patient was given four anti tubercular drugs (isoniazid, rifampicin, ethambutol, pyrazinamide) for 9 months following which the swelling has subsided.

Case 2

A 19 year old female patient presented with a history of painful swelling of 2 months duration in the right middle finger. Swelling was small to begin with but gradually increased in size. Signs and symptoms suggestive of tuberculosis presently or in the past were not present. Family history was not contributory. Similar bony swelling in any other part of her body was not found. Physical examination revealed a fusiform swelling of bony consistency involving the proximal part of right middle finger with mild tenderness on palpation. There was restricted mobility at all the joints of the involved finger. Radiographs showed an expansile lesion of right third middle phalanx with cortical destruction but there was neither any periosteal reaction nor any irregular growth (Figure 2). Chest X-ray was normal. Tuberculin test was strongly positive (indurations of 20mm). Fine needle

aspiration of phalanx of right middle finger showed epithelioid cell clusters, multinucleated giant cells, granulomatous inflammation with necrosis and acid fast bacilli was subsequently positive on Ziehl Neelsen staining. The patient was commenced on anti-tubercular treatment.

DISCUSSION

Tuberculosis is one of the leading causes of death among infectious diseases and has gained global notoriety. Musculoskeletal tuberculosis is secondary to hematogenous spread from a primary source shortly after primary infection or later due to disease reactivation [5].

Tubercular involvement of phalanges, metacarpals and metatarsals is a rare presentation of extra-pulmonary tuberculosis [6].

In a review of literature, 83% of cases were reportedly 30yrs or younger with a second peak at a later age [7]. Tubercular dactylitis is supposedly three times more frequent in males than females [8]. In present instance, both reported cases were women aged 47 and 19 yrs. Disseminated skeletal tuberculosis without primary foci is rare [9] as was seen in both the cases. Bones of hand are involved more frequently than of the foot affecting phalanges of middle and index finger commonly in hand and metatarsals in feet [7]. In the young girl middle phalanx of middle

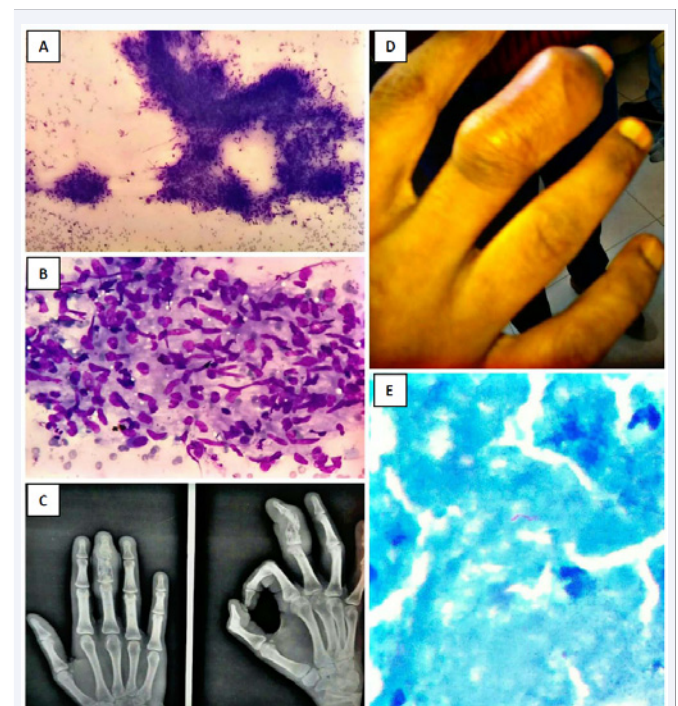


Figure 2

- A) (MGG; 4X) Showing well formed granulomas.
 B) (MGG; 10X) showing epithelioid cell clusters with granulomatous inflammation.
 C) Radiograph showing an expansile lesion of right middle phalanx.
 D) Shows a fusiform swelling of bony consistency involving the proximal part of right middle finger.
 E) (AFB; 40X) Shows an acid fast bacilli in a background of necrosis.

finger was involved. However in the older woman, proximal phalanx of great toe rather than metatarsals was affected. In both the cases ESR was elevated over baseline level and Mantoux test were positive as documented by other authors [7,9].

Timely and prompt diagnosis without delay is essential for retaining optimal function and therefore challenging in Tubercular Dactylitis. Depending on age of presentation a variety of differentials can be considered. In younger age leukemia, langerhan's histiocytosis, hemoglobinopathies, enchondromas, osteoblastomas other than pyogenic infections and osteomyelitis of bacterial or fungal etiology can be considered while in the elderly metabolic disorders (gout) and tumors may additionally be ruled out.

Radiological manifestations are supportive and include soft tissue swelling, osteopenia, narrowing of joint space, cysts /erosions, bony sclerosis and periostitis and calcification in decreasing order of frequency [2].

Based on clinical and radiological examination presumptive diagnosis is usually confirmed by cytology or histopathology of the involved tissue. Granulomas in biopsy and cytology smears are present in a majority of patients [2]. This requires exclusion of other relatively rarer granulomatous disorders viz sarcoidosis, syphilis, leprosy.

On finding granulomas on FNAC, Ziehl Neelsen (ZN) staining for acid fast bacilli (AFB) or culture should be procured; the latter being the gold standard for diagnosis. Tubercular dactylitis (TD) lesions are classically paucibacillary and at least 10^4 acid fast bacilli per millilitre of specimen are required for ZN staining to pickup AFB [10]. In both cases AFB put up with previous known positive controls was positive and hence a diagnosis of granulomatous inflammation of tubercular nature (TD) was rendered possible. Where resources permit DNA detection of mycobacteria by PCR can be done to allow differentiation of tubercular and non- tubercular mycobacteria.

Treatment of Tubercular Dactylitis is non- operative. Current recommendations include a 2 month initial phase of isoniazid, rifampicin, pyrazinamide and ethambutol followed by a 6-12 month regimen of isoniazid and rifampicin [11]. As reported in literature, patients with tubercular dactylitis recovered fully following treatment with anti-tubercular drugs; none of these cases showed recurrence or required surgical intervention [12,13]. Both reported cases responded well to medical treatment and are currently in follow up.

CONCLUSION

Tubercular dactylitis is a rare presentation of extra-pulmonary tuberculosis constituting less than 1% of cases of skeletal tuberculosis. It is uncommon beyond first decade of life.

Though lesions are considered paucibacillary every concerted effort should be made to identify acid fast bacilli on Ziehl Neelsen stained fine-needle aspiration smears particularly in cases with high index of suspicion for this disease as it is not only cost-effective but also minimally invasive and a diagnostic procedure when resources are limited.

REFERENCES

- Subasi M, Bukte Y, Kapukaya A, Gurkan F. Tuberculosis of the metacarpals and phalanges of the hand. *Ann Plast Surg.* 2004; 53: 469-472.
- Gabriel Aisenberg. Tuberculous Dactylitis: An Unusual Finding Demanding Invasive Diagnosis. *J Clin Case Rep.* 2014; 4: 7.
- Ranadeb Bandyopadhyay, Arindam Mukherjee, Rajib Kumar Mondal. "Spina Ventosa" Tuberculous Dactylitis in a 2 Year Old Boy - A Very Rare Disease. *Open Ortho J.* 2012; 6: 118-120.
- Sbai MA, Benzarti S, Sahli H, Sbei F, Maalla R. Osteoarticular tuberculosis dactylitis: Four cases. *Int J Mycobacteriol.* 2015; 4: 250-254.
- Bhaskar, Tashi Khonglah, Jerryson Bareh. Tuberculous dactylitis (spina ventosa) with concomitant ipsilateral axillary scrofuloderma in an immunocompetent child: A rare presentation of skeletal tuberculosis. *Adv Biomed Res.* 2013; 2: 29.
- Feroz Alam, Noora Saeed, Aaliya Ehsan, Asim Israr Khan. Tubercular Dactylitis in a 9 Year Old Male Child: A Rare Case Report. *Br J Med Health Res.* 2016; 3.
- Nadeem Ali, Abedullah Bhat, Akeela Fatima, Khalid Muzzafar, et al. Tuberculous Dactylitis: A Case Series and Review of Literature. *JPMS.* 2014; 4: 184-190.
- Jones BE, Young SM, Antoniskis D, Davidson PT, Kramer F, Barnes PF. Relationship of the manifestations of tuberculosis to CD4 cell counts in patients with human immunodeficiency virus infection. *Am Rev Respir Dis.* 1993; 148: 1292-1297.
- Kothari PR, Shankar G, Gupta A, Jiwane A, Kulkarni B. Disseminated spina ventosa. *Indian J Chest Dis Allied Sci.* 2004; 46: 295-296.
- Shradha Agarwal, Daniel Caplivski, Edward J Bottone. Disseminated tuberculosis presenting with finger swelling in a patient with tuberculous osteomyelitis: A case report. *Annals of clini microbiol and antimicrobials.* 2005; 4: 18.
- American Thoracic Society; CDC; Infectious Diseases Society of America. Treatment of tuberculosis. *MMWR Recomm Rep.* 2003; 52: 1-77.
- Kotwal PP, Khan SA. Tuberculosis of the hand: clinical presentation and functional outcome in 32 patients. *J Bone Joint Surg Br.* 2009; 91: 1054-1057.
- Benchakroun M, El Bardouni A, Zaddoug O, Kharmaz M, El Yaacoubi M, Ouadghiri M, et al. Tuberculosis of the wrist: symptoms and outcome in eleven cases. *Rev Chir Orthop Reparatrice Appar Mot.* 2004; 90: 337-345.

Cite this article

Bahadur S, Anand P, Narula A, Nargotra N (2017) Tubercular Dactylitis: Cytodiagnosis to Rescue- A Report of Two Cases. *Ann Clin Cytol Pathol* 3(3): 1061.