

Case Report

Costochondral Exostoses Mimicking as a Posterior Mediastinal Mass: A Case Report

Manouchehr Aghajanzadeh, Siamak Rimaz*, Rasool Hassanzadeh, Omid Mostafaie, and Shima Ildari

Inflammatory Lung diseases Research Center of Guilan University of Medical Sciences, Razi Hospital, Iran

***Corresponding author**

Siamak Rimaz, Inflammatory Lung diseases Research Center of Guilan University of Medical Sciences, Rasht, Razi Hospital, Iran, Tel: 98-13-3354246; Email: rrc@gums.ac.ir

Submitted: 23 June 2017

Accepted: 17 July 2017

Published: 19 July 2017

ISSN: 2475-9430

Copyright

© 2017 Rimaz et al.

OPEN ACCESS

Keywords

- Osteochondroma
- Rib
- Mediastinal mass
- Costal exostosis

Abstract

Exostosis (Osteochondroma) is a rare tumor in the rib, but in the mediastinum it is extremely rare. Herein, we report a case of 32-year old male patient with a symptomatic solitary costal exostosis in the left hemi thorax mimicking a mediastinal mass. The chest X-ray and magnetic resonance imaging (MRI) of the chest revealed a bone density structure that had originated from the costochondral junction of the left 10th and 11th ribs and protruded into the thoracic cavity. Exploratory thoracotomy showed that the exostosis had scratched the adjacent aorta, diaphragm and spinal column in the paravertebral sulcus. An 8 × 6 cm mass with long rib segment including the exostosis was excised. Surgical resection is indicated for definitive diagnosis and prevention of complications and malignancy. Surgical excision and histopathology confirmed the diagnosis of exostosis (osteochondroma).

INTRODUCTION

Osteochondroma, also known as exostosis, is the most common cartilaginous tumor and constitutes 20-25% of benign bone tumors. Rib exostosis is exceedingly rare and occurs in the area of costovertebral junctions or in the level of rib vertebrae [1,2]. These lesions may be solitary or multiple [1,2]. They are usually asymptomatic, but also intrathoracic complications have been reported. They may present as a swelling in the chest wall or as an incidental finding on chest X-ray [1,3,4]. Exostoses of the inner aspect of the ribs may destruct the adjacent structure; so, it is recommended to be resected because Surgical resection indicated for definitive diagnosis and prevention of complications and malignancy [2,5,6]. The patient in this report is a 32-year man with a symptomatic solitary costal exostosis in the left hemi thorax mimicking a mediastinal mass.

CASE PRESENTATION

A 32-year old Iranian male patient referred to our department with left side chest pain without the history of trauma or pulmonary disease. The patient was farmer and living in guilan province in north of Iran. He had B.M.I= 28(Kg/m²). Family history was negative for chest disease. The patient had no remarkable respiratory symptoms, such as, cough or dyspnea, the lung function tests and blood laboratory findings were strictly normal. Chest X-ray showed an 8×6 cm mass in the left lower-chest area over the heart shadow, with no evidence of pneumothorax or pleural effusion (Figure 1). To evaluate further the mass lesion, and Magnetic resonance imaging (MRI)

was performed. The MRI of the chest showed a well defined, encapsulated, multiseptated, hetro-signal mass (mainly low on T1, indeterminate on T2W&STIR) measuring about 81 × 68mm within the left paravertebral and para-aortic space at the level of T10. Contrast administration didn't show significant enhancement or invasion to bone structure, spinal canal and adjacent muscle. This lesion had originated from the inner aspect of the left anterior part of 10th and 11th ribs, with a projection towards the posterior mediastinum, aorta and lung (Figure 2). Radiological findings did not indicate rib destruction. However, the mass lesion was excised for preventing lethal visceral injury and to confirm the

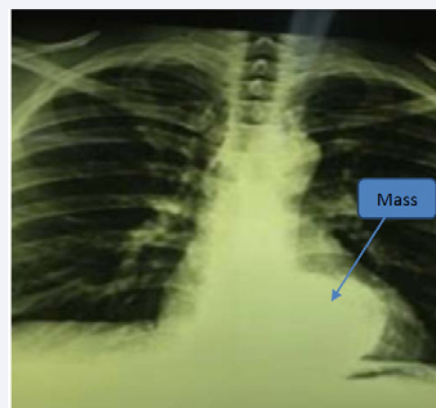


Figure 1 Chest X-Ray (PA) shows an about 8×6 cm mass in the left lower-chest area over the heart shadow.

diagnosis. We performed an exploratory thoracotomy in the left lateral decubitus position via the seventh intercostal space under general anesthesia with unilateral ventilation. Exploration revealed a cartilaginous and bony mass scratched the adjacent aorta, diaphragm and spinal column in the paravertebral sulcus and left lung when the lung was fully inflated. A 5.5 cm segment of the left 10th and 11th rib including the mass was resected. An embloc resection was not possible because the mass was very fragile (Figure 3). The chest wall defect was repaired with contiguous structure. The postoperative course was uneventful and the patient was discharged on the sixth postoperative day. Histopathological examination of the resected specimen confirmed the diagnosis of osteochondroma. He remains well at one year follow-up.

DISCUSSION

Exostoses are benign abnormalities in which a portion of the epiphyseal growth plate cartilage becomes separated from the main epiphysis. Costal exostoses's involvements occur in the region of costochondral junction or the end of the ribs [1,3,4]. In our patient, exostosis had originated from the endpoint of the 10th and 11th ribs in costochondral junction area. These lesions are also known as osteochondromas. They can be solitary or multiple [1]. Solitary exostoses may occur in infants and occasionally in adults [1,6]. Our patient presented with a solitary mass. Differential diagnosis of rib lesions include enchondroma,

osteoblastoma, osteoid osteoma, chondroblastoma, hemangioma and chondrosarcoma. Rib exostosis is completely asymptomatic in most cases: however they may present as a swelling in the chest wall or give rise to pain [2] (as observed in our case). Hemothorax presented in few cases of the costal exostosis due to the pleura, diaphragm, heart and lung damage [7]. Rib exostosis may be difficult to recognize on standard chest X-ray. The chest CT scan and MRI are usually useful methods for the diagnosis [2,6,7]. We used MRI in our patients for diagnosis. Surgical intervention has two benefits [2,7]: (1) prevention of lethal visceral injury and (2), prevention of recurrence and reduce the risk of malignancy. Malignant transformation rate in a costal exostosis is 1-2% [8].

In case of asymptomatic patients treatment is not usually proposed, but surgical removal of the exostosis should be recommended in selected patients such as our patient [2]. We performed wide resection of exostosis with a segment of 10th and 11th ribs.

CONCLUSION

Surgical resection indicated for definitive diagnosis and prevention of complications and malignancy or when the tip of exostosis was sharp and protruded into the thoracic cavity. Thoracoscopy in selected cases is recommended by some authors [7].

REFERENCES

1. Bae S-K, Kang W-S, Yoo S-H, Cho J-H, Park K-W, Lee B-H, et al. Osteochondroma of the Rib Mimicking a Mediastinal Mass: Unexpected Manifestation in Hereditary Multiple Exostoses. *Yeungnam Univ J Med.* 2012; 29: 45-47.
2. Nakano T, Endo S, Tsubochi H, Tetsuka K. Thoracoscopic findings of an asymptomatic solitary costal exostosis: is surgical intervention required? *Interact Cardiovasc Thorac Surg.* 2012; 15: 933-934.
3. Kikuchi R, Mino N, Matsukura T, Hirai T. Resected osteochondroma of the rib in an elderly patient. *Gen Thorac Cardiovasc Surg.* 2010; 58: 588-591.
4. Lee CY, Ham SY, Oh YW, Lee SH, Kim KT. Osteochondroma arising from a rib mimicking a calcifying anterior mediastinal mass. *J Korean Radiol Soc.* 2007; 57: 533-535.
5. Buchan KG, Zamvar V, Mandana KM, Nihal E, Kulatilake P. Juxtacardiac costal osteochondroma presenting as recurrent haemothorax. *European journal of cardio-thoracic surgery: official journal of the European Association for Cardio-thoracic Surgery.* 2001; 20: 208-210.
6. Reynolds JR, Morgan E. Haemothorax caused by a solitary costal exostosis. *Thorax.* 1990; 45: 68-69.
7. Alifano M, Morcos M, Molina T, Regnard JF. An unusual cause of hiccup: costal exostosis. Treatment by video-assisted thoracic surgery. *European journal of cardio-thoracic surgery: official journal of the European Association for Cardio-thoracic Surgery.* 2003; 23: 1056-1058.
8. Garrison RC, Unni KK, McLeod RA, Pritchard DJ, Dahlin DC. Chondrosarcoma arising in osteochondroma. *Cancer.* 1982; 49: 1890-1897.

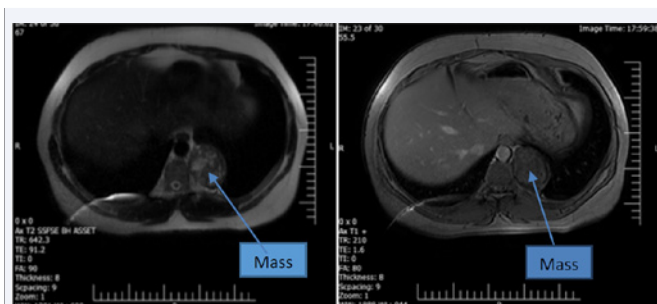


Figure 2 The MRI of the chest showed a well defined, encapsulated, multiseptated, heterosignal mass measuring about 81 x 68mm within the left paravertebral and paraaortic space and Extending beneath the T10, Pushing the Pleura and the Lung Inwards.

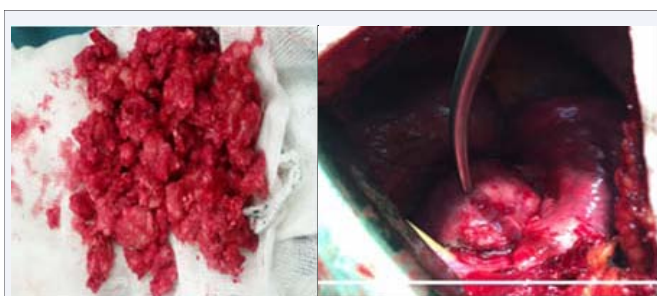


Figure 3 Post resection mass.

Cite this article

Aghajanzadeh M, Rimaz S, Hassanzadeh R, Mostafaie O, Ildari S (2017) Costochondral Exostoses Mimicking as a Posterior Mediastinal Mass: a Case Report. *Ann Clin Cytol Pathol* 3(5): 1069.