

Case Report

Sectional Impression Technique and Magnet Retained Two-Piece Obturator for Maxillectomy Patient with Trismus

Pravinkumar G. Patil^{1*}, Smita P. Patil² and Rahul S. Kulkarni³

¹School of Dentistry, International Medical University, Malaysia

²Department of Orthodontics and Dentofacial Orthopedics, SDKS Dental College and Hospital, India

³Department of Prosthodontics, Nair Hospital Dental College Mumbai, India

***Corresponding author**

Pravinkumar G. Patil, School of Dentistry, International Medical University, Jalan Jalil Perkasa 19, Bukit Jalil, Kuala Lumpur, 57000, Malaysia, Tel: +60-1135022042; Email: pravinandsmita@yahoo.co.in

Submitted: 05 August 2014

Accepted: 15 October 2014

Published: 17 October 2014

ISSN: 2333-7133

Copyright

© 2014 Patil et al.

OPEN ACCESS**Keywords**

- Maxillectomy
- Obturators
- Oral cancer
- Sectional impression
- Trismus

Abstract

This article describes technique to make the sectional impression of the maxillectomy defect of a patient with the reduced mouth opening. The cast generated after pouring the impression is duplicated twice to fabricate the defect component and the palatal base-plate component separately. Both the components were then oriented and attached with the help of a pair of the magnets. This magnet retained obturator facilitates the insertion and removal of the prosthesis in two separate pieces in restricted mouth opening situation.

INTRODUCTION

Malignant tumors involving the maxillary sinus often present histologically as a squamous cell carcinoma or adenocarcinoma, and are best treated with a combination of surgery and radiotherapy. An obturator prosthesis is generally recommended after maxillectomy to prevent nasal regurgitation of fluids, maintenance of speech and for psychological reasons [1-3]. Fabrication of interim and definitive obturator requires well extended impression of the maxillary arch including the defect portion [4]. Removal of an impression that records maxillary arch and the defect portion requires adequate mouth opening. A patient undergone maxillectomy and radiotherapy may present with restricted mouth opening due to factors like post surgical contracture of tissues and fibrosis due to radiation therapy [5]. This article describes sectional impression technique for a patient with restricted mouth opening resulting from post radiation trismus. The article also highlights the fabrication steps of a two-piece magnet retained obturator.

CASE PRESENTATION

Carefully examine the patient reported after surgery and radiotherapy and presented with the reduced mouth opening (Figure 1). Make the primary impression of maxillary arch using perforated plastic stock tray (trimmed to cover only non-resected portion) with the thick mixed irreversible hydrocolloid (Dentalgin; Prime Dental Products, Mumbai, India) to record only the normal non-resected portion of the maxillary arch. Note that the internal portion of the defect need not be recorded at

this stage, hence may be obturated with petrolatum coated gauze temporarily during making the impression if required.

Obtain a primary cast with gypsum material type III (Kalsone; Kalabhai Carson, Mumbai, India), develop the resected portion on the cast arbitrarily to be used for fabrication of the sectional tray.

Fabricate first section of the tray on the defect (resected) side of the primary cast in conventional manner (Figure 2A). Construct interlocking indices on this section to provide attachment to the tray portion on normal/ healthy side.

With previously mentioned section of the tray still in place, fabricate the tray section on normal side of primary cast. Exercise particular attention to cover the defect section tray interlockings, to allow orientation of the two sections during and after impression making. Make perforations in sectional impression trays for retention of impression material (Figure 2B).

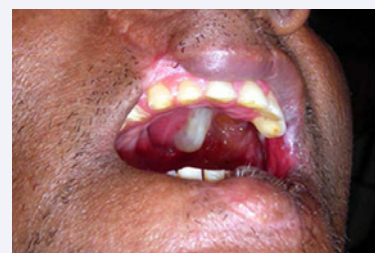

Figure 1 Acquired palatal defect and restricted mouth opening.

Try the intraoral trays by keeping the defect section tray first over the defect and place another non-defect portion try intraorally to judge the positioning during impression making.

Apply a tray adhesive and load the sectional tray on defect side with the irreversible hydrocolloid and place the tray intraorally to record the internal portion and periphery of the defect (Figure 3). Allow impression to set completely, but do not remove the tray at this stage. Remove the unsupported set hydrocolloid from the mouth and apply the Vaseline petroleum jelly with the help of cotton to the indices, set hydrocolloid and remaining portion of the tray onto which the future impression material may cover.

Prepare a fresh mix of the material, load another section of the tray of normal side of arch and place intraorally using the interlocking indices of the previously placed section. Hold the tray in position till the impression sets.

Remove the section of sectional impression on the normal side first. Next, remove the sectional impression from the defect area. Re-assemble the two sectional impressions outside the mouth by matching the interlocking and indices of each as shown in Figure 4A to prepare the impression that comprises entire dental arch and internal portion of defect.

Fix the two assembled sections of the impression by resting the backside of the two on the lab Putty (Lab Putty Hard, Coltene Whaldent, Feldwiesenstrasse, Switzerland) from to generate the full arch impression.

Pour the impression using the type III dental stone to obtain a final cast (Figure 4B).

Make two duplicate casts from the final casts for processing of the Obturator in heat polymerizing acrylic resin (DPI Heat-cure; Dental Products of India, Mumbai, India). Note that usually the prosthesis in such cases is a two-piece-obturator.

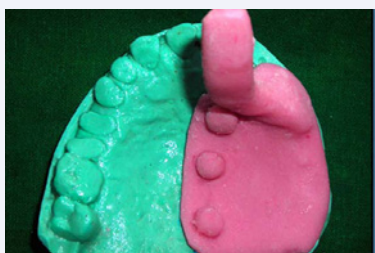

Figure 2a Fabrication of first section of the tray with interlocking indices.

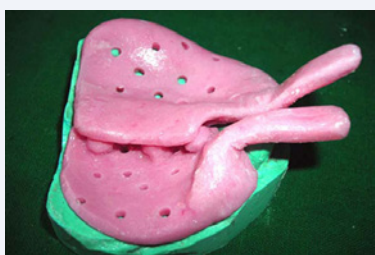

Figure 2b Sectional trays.

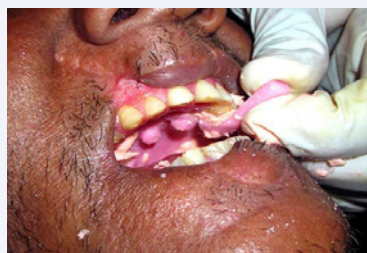

Figure 3 Impression of defect area.

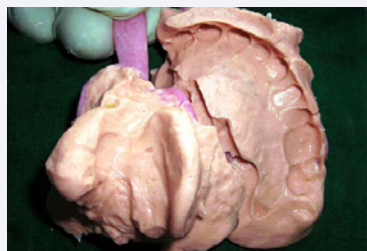


Figure 4a Two sections of the impression oriented using interlocking indices.

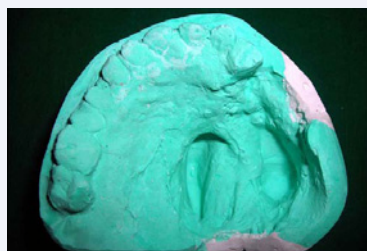


Figure 4b Final cast.

Use one duplicated cast to fabricate defect (or bulb component) and another duplicated cast for fabrication of normal palatal base-plate component. Note that the defect of the cast to be used for palatal base-plate should be filled with Gypsum material type II before processing.

Process, finish, and polish both the components of obturator using heat polymerized acrylic resin with standard laboratory techniques. Try both components on the final cast as shown in Figure 5A and B.

Perform try in of each part individually and then simultaneously to verify their adaptation to oral tissues.

Select a pair of suitable magnets for joining two components of the obturator. Create space to accommodate one piece of magnet in each component.

Mix auto polymerizing resin and fill it in the space created for magnet in bulb and plate component simultaneously, with particular care to avoid spilling excess resin mix.

Place one magnet in bulb component then place wet cellophane sheet and then another magnet wet onto it as shown in Figure 6A.

Before setting of the resin, place the plate component on to it and ensure stable position till the resin sets.

Remove palatal plate component, cellophane sheet, and bulb component of the obturator (in the same order), and check for excess resin, if any (Figure 6B).

Try it in patient's mouth with bulb component placed inside first followed by the palatal plate component of the Obturator (Figure 7). Check for any sore spots using pressure indicator paste, and deliver the obturator.

Instruct the patient regarding use and maintenance of the Obturator. Schedule the recall appointments for prosthesis

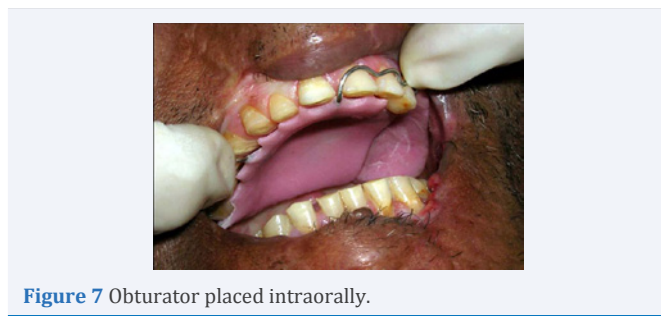

Figure 7 Obturator placed intraorally.

maintenance and tissue examination after 24 hrs, 1 month, 2 months and then after every 6 months.

DISCUSSION

Obturers have been classified according to the time of their insertion, like surgical obturator (to be placed immediately after surgery), interim obturator (1-2 weeks postsurgically), and definitive obturator (after completion of clinical healing and radiotherapy) [6]. A patient undergone maxillectomy and radiotherapy may present with restricted mouth opening [5]. In such patients impression making is a difficult task. Failure to record peripheral tissues around the defect and its interior portion may lead to inadequate retention of prosthesis and nasal regurgitation of fluids [7]. Many authors suggested the sectional impression trays with hinge and plunger attachment, press button attachment or interlocking attachment between parts of the tray to obtain well extended impression [8]. This article describes modified technique to fabricate sectional trays to re-assemble them after sectional impression with the help of indices (interlocking) formed within the trays with the help of acrylic resin. In presence of restricted mouth opening, sectional prostheses have often been recommended, particularly in maxillofacial prosthetics, due to large size of the prosthesis [9]. Magnets are commonly used adjuncts in retention of sectional maxillofacial prostheses [10].

REFERENCES

1. Beumer J, Curtis D, Firtell D. Restoration of acquired hard palate defects: etiology, disability and rehabilitation. In: Maxillofacial rehabilitation: prosthodontic and surgical considerations, Beumer J III, Curtis TA, Marunick MT, editors. St. Louis: Medico Dental Media Intl. 1996; 225-284.
2. Jacob FJ. Clinical management of the edentulous maxillectomy patient. In: Clinical maxillofacial prosthetics, Taylor TD, editor. Chicago: Quintessence. 2000; 85-87.
3. Patil PG. New technique to fabricate an immediate surgical obturator restoring the defect in original anatomical form. J Prosthodont. 2011; 20: 494-498.
4. Patil PG, Patil SP. Fabrication of a hollow obturator as a single unit for management of bilateral subtotal maxillectomy. J Prosthodont. 2012; 21: 194-199.
5. Kramer DC. The radiation therapy patient: treatment planning and post treatment care. In: Clinical maxillofacial prosthetics, Taylor TD, editor. Chicago: Quintessence. 2000; 37-52.
6. Patil PG, Patil SP. Nutrition and cancer. J Am Dent Assoc. 2012; 143: 106-107.

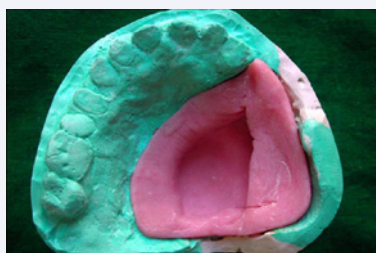

Figure 5a Defect component of obturator on final cast.

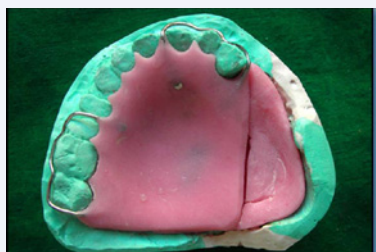

Figure 5b Defect and palatal base-plate components of obturator on final cast.

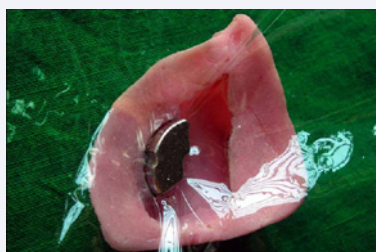

Figure 6a Attachment of the magnets.

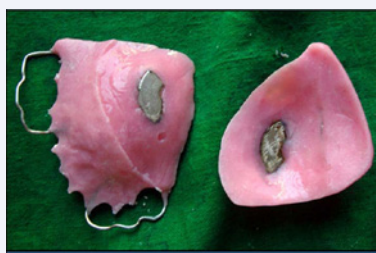

Figure 6b Two piece magnet retained interim obturator.

7. Watson RM, Gray BJ. Assessing effective obturation. *J Prosthet Dent.* 1985; 54: 88-93.
8. Givan DA, AuClair WA, Seidenfaden JC, Paiva J. Sectional impressions and simplified folding complete denture for severe microstomia. *J Prosthodont.* 2010; 19: 299-302.
9. Padmanabhan TV, Kumar VA, Mohamed KK, Unnikrishnan N. Prosthetic rehabilitation of a maxillectomy with a two-piece hollow bulb obturator. A clinical report. *J Prosthodont.* 2011; 20: 397-401.
10. Takahashi T, Fukuda M, Funaki K, Tanaka K. Magnet-retained facial prosthesis combined with an implant-supported edentulous maxillary obturator: a case report. *Int J Oral Maxillofac Implants.* 2006; 21: 805-807.

Cite this article

Patil PG, Patil SP, Kulkarni RS (2014) Sectional Impression Technique and Magnet Retained Two-Piece Obturator for Maxillectomy Patient with Trismus. *JSM Dent* 2(5): 1046.