

Case Report

Treatment of Class II, 2 Malocclusion Using a New Herbst-Type Appliance (The Biobitecorrector®): A Case Report

Mavreas D, Pasin E and Vande Vannet B*

Department of Orthodontics, Vrije Universiteit Brussel (VUB), Belgium

*Corresponding author

Bart Vande Vannet, DDS, MScOrth, PhD, Professor, ORHE, Vrije Universiteit Brussel (VUB), Department of Orthodontics, Laarbeeklaan 103, 1090 Brussels, Belgium Tel: 32 2 477 4908; Email: bart.vande.vannet@vub.ac.be

Submitted: 02 November 2015

Accepted: 11 January 2016

Published: 13 January 2016

ISSN: 2333-7133

Copyright

© 2015 Vande Vannet et al.

OPEN ACCESS

Keywords

- Herbst appliance
- Maxillomandibular growth
- Mandibular molars

Abstract

An Angle Class II case with a relative mandibular retrognathism, treated with a new fixed functional appliance with rigid arms (the Biobitecorrector®), which may be used alternatively to the Herbst appliance, and simultaneously with full fixed mechanisms is presented. The results indicate that the corrections achieved resemble those produced by similar types of functional appliances. The benefits as well as the possible problems which may arise from using this device are also discussed. However, further investigation based on a larger number of cases is required before more solid conclusions are drawn on the effectiveness of this appliance.

INTRODUCTION

The use of the Herbst appliance recaptured the interest of the orthodontic community following Pancherz's 1979 seminal publication [1]. The mandibular advancement induced and sustained by the appliance contributes to the successful Class II molar relationship and overjet correction, which can be attributed to about equal skeletal and dental changes. These changes could be summarized to an increase in mandibular length, distal movement of maxillary molars, and mesial movement of mandibular molars [2]. In a recent 32-year follow up study based on casts from 14 adolescents with Class II, division 1 malocclusions followed to middle life, the long-term effects of Herbst treatment on tooth position and occlusion were analyzed. The results of this type of therapy on the molar relationship were found to be stable in about 2/3 of the studied group with most of the post-treatment changes occurring during the first 6 years after treatment [3]. The Class II molar and overjet relapses could be explained by an unfavorable post-treatment maxillomandibular growth pattern, combined with unstable teeth interdigitation [4]. Findings regarding the long-term effects of the Herbst appliance on TMJ disorders are not different than those corresponding to the general population [5].

However, and despite the successful treatment outcomes the appliance has not gained widespread acceptance and use due to its complex manufacturing and bonding process. Various modifications and alternatives have been proposed over the years to simplify the use and minimize the number of undesirable incidents and side-effects [6-11]. A major advantage of these appliances is that they do not require the patient's compliance and can be utilized in conjunction with orthodontic brackets.

The aim of this paper is to describe the use of a new fixed functional appliance with rigid arms which may be used alternatively to the Herbst, and simultaneously with full fixed mechanisms to effectively treat different types of Class II malocclusions.

CASE PRESENTATION

The patient was a 13-year old female with a chief complaint of "protruding and irregular upper teeth". The clinical examination revealed a convex profile with a retrusive mandible, and a Class II, division 2, malocclusion. The overjet was 4 mm and the overbite 5 mm, with marked crowding in the maxillary arch (Figure 1-8).

The cephalogram and the analysis of it confirmed the clinical findings indicating a well-positioned maxilla, a retrognathic mandible, and a tendency for a skeletal deep bite (Figure 9, Table 1). The panoramic radiograph showed the presence of third molars (Figure 10).

The overall treatment goal was to improve the convex profile and obtain a Class I occlusion with ideal overjet and overbite without extracting teeth. A fixed functional appliance (in this case the biobitecorrector®) (BBC) would be used to aid in skeletal correction.

Treatment was initiated with full fixed, self-ligating appliances (0.022 slot) to promote leveling, alignment, and change in maxillary incisor inclination that would allow the seamless application of the biobitecorrector at a later stage. The sequence of archwires used was .014 Ni-Ti, .018 Ni-Ti, .017x.025 Ni-Ti, and .019x.025 stainless steel, and each one of them was left in the mouth for a period of one month.



Figure 1 Pretreatment extraoral and intraoral photographs of the patient.




Figure 2 Pretreatment extraoral and intraoral photographs of the patient.




Figure 3 Pretreatment extraoral and intraoral photographs of the patient.

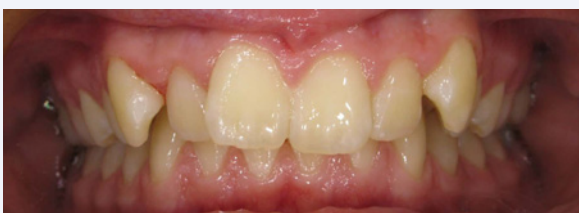

Figure 4 Pretreatment extraoral and intraoral photographs of the patient.

Consequently, after 4 months, it was possible to place the BBC on a .019x.025 stainless steel straightwire (the presence of a minimum .017 x .025 stainless steel wire is required before inserting the BBC). The rigid multitelescopic telescopic arms of the appliance were adjusted using the appropriate 'spacers' as to produce and maintain a Class I molar and canine interarch relationship (Figure 11,12).

The BBC was employed for a period of seven months, and following its removal, upper and lower .016 x .022 Ni-Ti wires

were inserted in combination with Class II elastics (5/16, 4 oz.), to support the sagittal correction achieved. Treatment with the self-ligating fixed appliances continued for another five months and the patient was finally debonded. The total treatment time was 15 months (Figure 13-18).

The occlusal correction was retained using two removable wrap-around appliances.

DISCUSSION

Mandibular retrusion is the most prevailing characteristic feature of Class II malocclusion [12]. Redirecting and modifying mandibular growth would then be the natural main goals in a Class II treatment protocol as facial aesthetics can be improved by such an approach. Removable (RA) and fixed functional (FFA) appliances have been utilized for this purpose with the FFA group potentially subdivided into three subgroups: the semi-elastic (e.g. Jumper Jumper, Twin Force, Eureka Spring), the rigid (Herbst, MARA, etc.), and the hybrid -with both rigid and flexible parts-

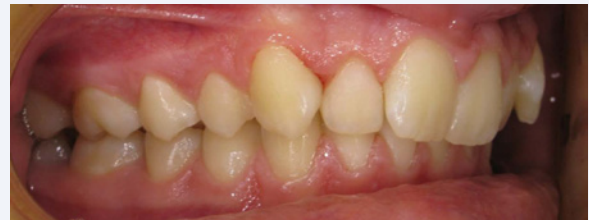

Figure 5 Pretreatment extraoral and intraoral photographs of the patient.

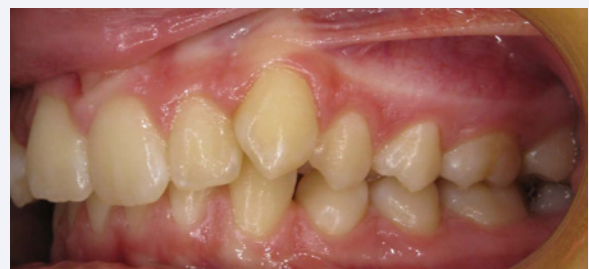

Figure 6 Pretreatment extraoral and intraoral photographs of the patient.

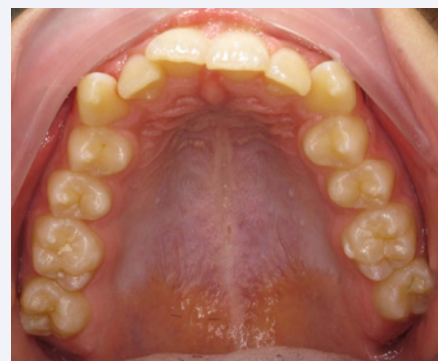

Figure 7 Pretreatment extraoral and intraoral photographs of the patient.

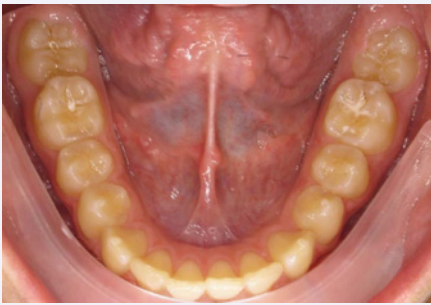


Figure 8 Pretreatment extraoral and intraoral photographs of the patient.

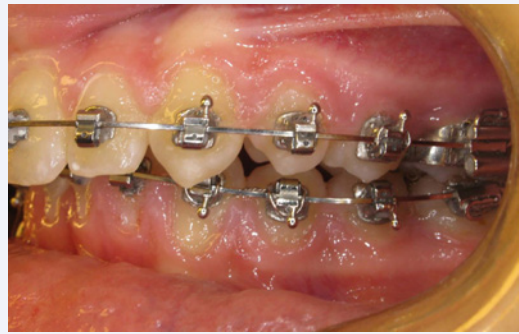


Figure 11 Post-treatment extraoral and intraoral photographs.

Table 1: Selected variables of the cephalometric analysis before treatment.

Variable	Value
SNA	90°
SNB	82°
ANB	8°
GoGnSN	20°
Maxillary Incisor/SN	110°
Mandibular Incisor/ML	96.5°
FH/Tangent to the facial of U1	75°

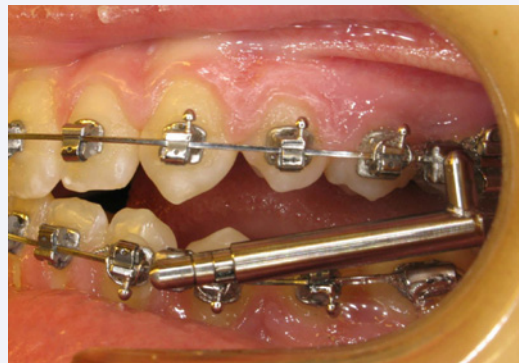

Figure 12 Post-treatment extraoral and intraoral photographs.

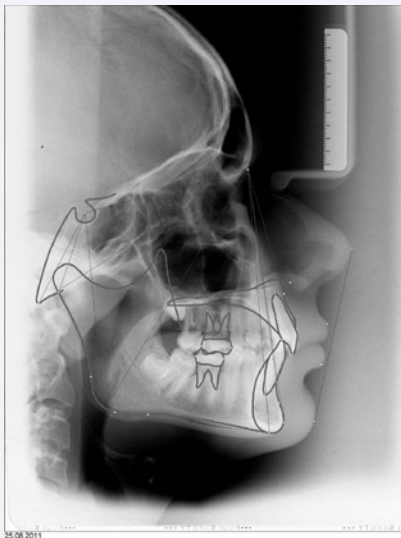


Figure 9 Post-treatment extraoral and intraoral photographs.

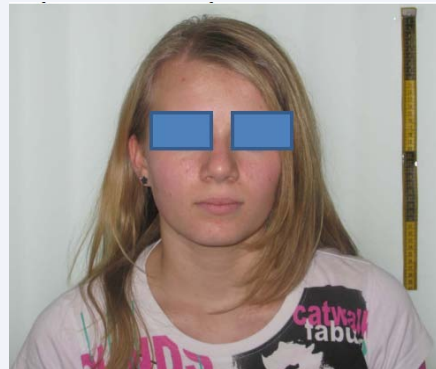

Figure 13 Post-treatment extraoral and intraoral photographs.

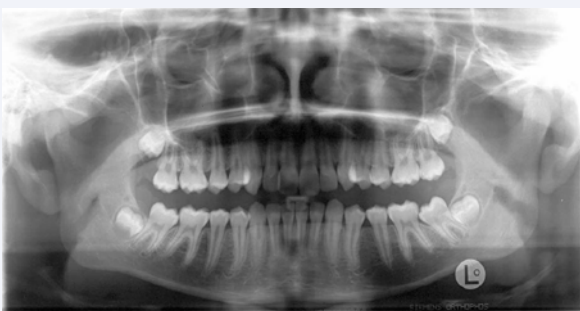

Figure 10 Post-treatment extraoral and intraoral photographs.



Figure 14 Post-treatment extraoral and intraoral photographs.

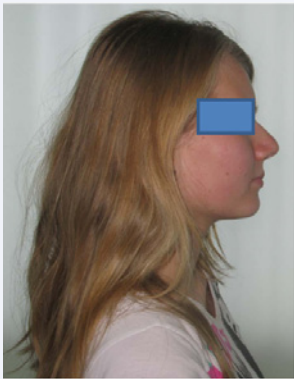

Figure 15 Post-treatment extraoral and intraoral photographs.

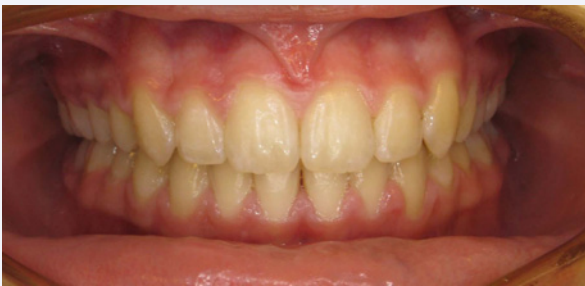

Figure 16 Post-treatment extraoral and intraoral photographs.

(e.g. Forsus Spring, Powerscope) Class II correctors. All these three types of appliances have demonstrated similar effectiveness in correcting the Class II dentoskeletal discrepancies [13–17].

It has been shown that a clinically significant supplementary elongation in total mandibular length of more than 2.0 mm is the result of the overall active treatment with functional appliances. This is accompanied by a reduction in forward growth of the maxilla, and the Herbst, and Twin-block appliances seem to have had the highest coefficient of efficiency [17]. The semi-elastic appliances when used in adolescent patients with Class II malocclusion seem to produce mainly dentoalveolar effects [18].

The Biobitecorrector® presented in this report belongs to the rigid bite-jumping devices and is introduced as an alternative to the Herbst appliance. It has been well documented that Herbst treatment benefits the aesthetics of the profile [19]. As it can be seen from the analysis of the cephalometric radiograph taken following the completion of treatment (Figure 19, Table 2) some mild maxillary growth restriction (SNA was reduced from 90° to 88°), favorable changes to the SNB (pre-treatment: 82°, post-treatment: 84°), and ANB (which was also reduced from 8° to 4°) angles with a favorable effect on the profile were induced (Figure 15). The final maxillary incisor inclination (88°) as it defined by the angle between the FH and the tangent to the facial surface of the incisor predisposes to an aesthetically pleasing profile smiling view [20].

The results in this case are not the sole product of the BBC since the final measurements reflect the outcome of the combination of the rigid corrector with full fixed self-ligating brackets. These seem to be in accordance with results previously reported,

where fixed functional appliance treatment in combination with multibracket appliances has been shown to be effective in treating Class II malocclusions with skeletal effects when performed during the pubertal growth phase or even in early and late adulthood [21,22]. Slight mandibular incisor proclination, and maxillary incisor retrusion together with very mild clockwise tipping of the mandibular plane (GoGn/ML initial: 20°, final: 24°) as noted in this patient, are usual findings when similar treatment approaches are adopted [14,23,24]. The amount of bite jumping has been associated with the amount of protrusion, intrusion, and proclination of the mandibular incisors. However, during the multibracket treatment period, relapsing incisor movements occur [24], as probably happened in this case

The design of all FFA is compliance-free, but the many difficulties which are encountered in the manufacturing and bonding process [25], and the increased likelihood of complications during treatment [26–28], has deferred many clinicians from using them. The incidence of complications during treatment with different versions of the Herbst appliance

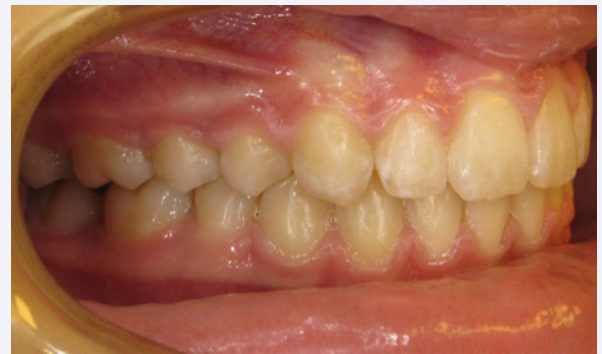

Figure 17 Post-treatment extraoral and intraoral photographs.

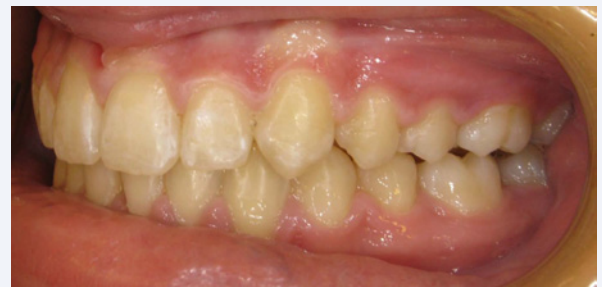

Figure 18 Post-treatment extraoral and intraoral photographs.

Table 2: Selected variables of the cephalometric analysis after treatment.

Variable	Value
SNA	88°
SNB	84°
ANB	4°
GoGnSN	24°
Maxillary Incisor/SN	107°
Mandibular Incisor/ML	99°
FH/Tangent to the facial of U1	88°

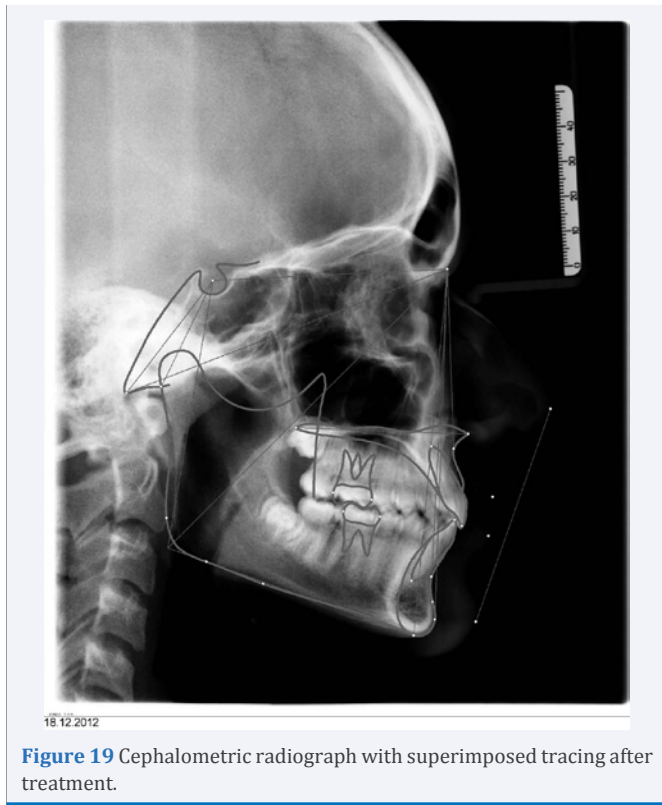


Figure 19 Cephalometric radiograph with superimposed tracing after treatment.

has been reported as high as eight-eight percent [28]. The BBC is manufactured from titanium, and designed to be totally operator depended as it is delivered completely pre-assembled. The design with the ball joints at the end of the telescopes which allow the patient to make sufficient lateral movements in combination with the hardness of the material might have made the present treatment complication-free. Naturally, the possibility for observing complications associated with the BBC when a greater number of patients is followed can not be excluded. Appliance acceptance by the patient which may diminish cooperation if not high [29] was excellent, and it may have contributed to the results observed.

The mean duration of comprehensive treatment with FFA has been calculated to be approximately 2.4 years [14,30] but this was not the case with the present treatment which lasted only fifteen months. It is not possible to attribute the time difference to the application of this novel device as it would obviously require a proper study design to prove it.

A recent systematic review on the true effect of Class II elastics in the treatment of Class II malocclusion, concluded that in the long term the results from using Class II elastics are similar to those from FFA due to natural growth which can mask the effect of the appliances and wipe out the effects of treatment. Therefore, we cannot claim that this case would have been treated inferiorly had Class II elastics been employed from the beginning instead of approximately one-third of the treatment time. When long-term changes between different types of RA and FFA were considered it seems that there were not significant dentoskeletal differences among the various treatment groups [31], and this case is probably not an exception. The reaction of adult Class II retrognathic patients to this type of treatment is not

yet known but it would be interesting to follow such individuals and compare their treatment results with those achieved with other types of FFA [32].

CONCLUSION

A Class II division 2 growing patient was treated effectively and efficiently with a novel fixed functional appliance –the Biobitecorrector®- which operates in accordance with the Herbst principles, and possibly less complications and better patient acceptance. The skeletal and dentoalveolar changes achieved were beneficial to the both occlusal correction and the aesthetics of the case, and they were similar to those produced by rigid fixed functional appliances. Further collection of sufficient data clarifying the exact mode of action of the BBC are required.

REFERENCES

1. Panzer H. Treatment of class II malocclusions by jumping the bite with the Herbst appliance. A cephalometric investigation. *Am J Orthod.* 1979; 76: 423-442.
2. Panzer H. The mechanism of Class II correction in Herbst appliance treatment. A cephalometric investigation. *Am J Orthod.* 1982; 82: 104-113.
3. Panzer H, Bjerkin K, Lindskog-Stokland B, Hansen K. Thirty-two-year follow-up study of Herbst therapy: a biometric dental cast analysis. *Am J Orthod Dentofacial Orthop.* 2014; 145: 15-27.
4. Panzer H, Bjerkin K, Hashemi K. Late adult skeletofacial growth after adolescent Herbst therapy: a 32-year longitudinal follow-up study. *Am J Orthod Dentofacial Orthop.* 2015; 147: 19-28.
5. Panzer H, Salé H, Bjerkin K. Signs and symptoms of TMJ disorders in adults after adolescent Herbst therapy: a 6-year and 32-year radiographic and clinical follow-up study. *Angle Orthod.* 2015; 85: 735-742.
6. McNamara JAJ, Howe RP. Clinical management of the acrylic splint Herbst appliance. *Am J Orthod Dentofacial Orthop.* 1988; 94: 142-149.
7. Jasper JJ, McNamara JA Jr. The correction of interarch malocclusions using a fixed force module. *Am J Orthod Dentofacial Orthop.* 1995; 108: 641-650.
8. von Bremen J, Panzer H, Ruf S. Reduced mandibular cast splints an alternative in Herbst therapy? A prospective multicentre study. *Eur J Orthod.* 2007; 29: 609-613.
9. Sari Z, Goyenc Y, Doruk C, Usumez S. Comparative evaluation of a new removable Jasper Jumper functional appliance vs an activator-headgear combination. *Angle Orthod.* 2003; 73: 286-293.
10. Vogt W. The Forsus Fatigue Resistant Device. *J Clin Orthod.* 2006; 40: 368-377.
11. Flores-Mir C, Barnett G, Higgins DW, Heo G, Major PW. Short-term skeletal and dental effects of the Xbow appliance as measured on lateral cephalograms. *Am J Orthod Dentofacial Orthop.* 2009; 136: 822-832.
12. McNamara JA Jr. Components of class II malocclusion in children 8-10 years of age. *Angle Orthod.* 1981; 51: 177-202.
13. Kucukkeles N, Ilhan I, Orgun I A. Treatment efficiency in skeletal Class II patients treated with the jasper jumper. *Angle Orthod.* 2007; 77: 449-456.
14. Franchi L, Alvetto L, Giuntini V, Masucci C, Defraia E, Baccetti T. Effectiveness of comprehensive fixed appliance treatment used with the Forsus Fatigue Resistant Device in Class II patients. *Angle Orthod.* 2011; 81: 678-683.

15. Nalbantgil D, Arun T, Sayinsu K, Fulya I. Skeletal, dental and soft-tissue changes induced by the Jasper Jumper appliance in late adolescence. *Angle Orthod.* 2005; 75: 426-436.
16. Pangrazio MNK, Pangrazio-Kulbersh V, Berger JL, Bayirli B, Movahhedian A. Treatment effects of the mandibular anterior repositioning appliance in patients with Class II skeletal malocclusions. *Angle Orthod.* 2012; 82: 971-977.
17. Cozza P, Baccetti T, Franchi L, De Toffol L, McNamara JA Jr. Mandibular changes produced by functional appliances in Class II malocclusion: a systematic review. *Am J Orthod Dentofacial Orthop.* 2006; 129: 599.
18. Oztoprak MO, Nalbantgil D, Uyanlar A, Arun T. A cephalometric comparative study of class II correction with Sabbagh Universal Spring (SUS(2)) and Forsus FRD appliances. *Eur J Dent.* 2012; 6: 302-310.
19. Sloss EA, Southard KA, Qian F, Stock SE, Mann KR, Meyer DL, et al. Comparison of soft-tissue profiles after treatment with headgear or Herbst appliance. *Am. J. Orthod. Dentofacial Orthop.* 2008; 133: 509-514.
20. Ghaleb N, Bouserhal J, Bassil-Nassif N. Aesthetic evaluation of profile incisor inclination. *Eur J Orthod.* 2011; 33: 228-235.
21. Ruf S, Pancherz H. Herbst/multibracket appliance treatment of Class II division 1 malocclusions in early and late adulthood. A prospective cephalometric study of consecutively treated subjects. *Eur J Orthod.* 2006; 28: 352-360.
22. Perinetti G, Primožic J, Furlani G, Franchi L, Contardo L. Treatment effects of fixed functional appliances alone or in combination with multibracket appliances: A systematic review and meta-analysis. *Angle Orthod.* 2015; 85: 480-492.
23. El-Fateh T, Ruf S. Herbst treatment with mandibular cast splints--revisited. *Angle Orthod.* 2011; 81: 820-827.
24. Martin J, Pancherz H. Mandibular incisor position changes in relation to amount of bite jumping during Herbst/multibracket appliance treatment: a radiographic-cephalometric study. *Am J Orthod Dentofacial Orthop.* 2009; 136: 44-51.
25. Schiavoni R. The Herbst appliance updated. *Prog Orthod.* 2011; 12: 149-160.
26. Manni A, Cozzani M, Mazzotta L, Fiore VP, Mutinelli S. Acrylic splint Herbst and Hanks telescoping Herbst: A retrospective study of emergencies, retreatments, treatment times and failures. *Int Orthod.* 2014; 12 : 100-110.
27. Moro A, Janson G, Moresca R. Comparative study of complications during Herbst treatment with Cantilever Bite Jumper and removable mandibular acrylic splint. *Dent. Press j Orthod Orthod* 2011;16 : 29-31.
28. Silva JF, Gerszewski C, Moresca RC, Correr GM, Flores-Mir C, Moro A. Retrospective study of clinical complications during orthodontic treatment with either a removable mandibular acrylic splint Herbst or with a cantilever Herbst. *Angle Orthod.* 2015; 85: 64-71.
29. Sergl HG, Klages U, Zentner A. Functional and social discomfort during orthodontic treatment--effects on compliance and prediction of patients' adaptation by personality variables. *Eur. J. Orthod.* 2000; 22: 307-315.
30. Cacciatore G, Ghislanzoni LT, Alvetro L, Giuntini V, Franchi L. Treatment and posttreatment effects induced by the Forsus appliance: A controlled clinical study. *Angle Orthod.* 2014; 84: 1010-1017.
31. Siara-Olds NJ, Pangrazio-Kulbersh V, Berger J, Bayirli B. Long-term dentoskeletal changes with the Bionator, Herbst, Twin Block, and MARA functional appliances. *Angle Orthod.* 2010; 80: 18-29.
32. Bock NC, von Bremen J, Ruf S. Occlusal stability of adult Class II Division 1 treatment with the Herbst appliance. *Am J Orthod Dentofacial Orthop.* 2010; 138: 146-151.

Cite this article

Mavreas D, Pasin E, Vande Vannet B (2016) Treatment of Class II, 2 Malocclusion Using a New Herbst-Type Appliance (The Biobitecorrector®): A Case Report. *JSM Dent* 4(1): 1055.