

## Short Note

# 'Single Visit' Fixed Space Maintainer

Pavankumar J. Vibhute\*

Department of Orthodontics, Maharashtra University of Health sciences, India

## INTRODUCTION

Premature loss of deciduous tooth results in drifting of adjacent teeth in to edentulous space along with arch length reduction, leading to malocclusion. The preservation of arch length in all stages of dentition is important for the normal development of occlusion. Meticulous attention of various factors are required in decision of planning space maintainer, which help in restoring normal function and eruption of succeeding permanent teeth [1]. Conventional appliances required to be modified according to the needs of patient. No design of fixed space maintainer is common and versatile for its use at different intraoral locations [2]. Most of the space maintainers require indirect fabrication, soldering, welding, cementation or multiple visits. This paper describes a new design of fixed space maintainer in cases of loss of any deciduous tooth where two adjacent teeth have erupted partially or completely [3-6]. Fabrication and clinical application of 'single step fixed space maintainer' is described here.

## MATERIALS FOR APPLIANCE FABRICATION

- 0.020" stainless steel wire
- Stainless steel closed coil spring
- 0.010" ligature wire
- Light cure composite cement

## DESCRIPTION OF APPLIANCE AND FABRICATION

Mesio-distal edentulous span is measured with caliper and space maintainer framework fabricated accordingly to fit mesial and distal contours (Figure 1A).

Molar (distal) contour prepared in 0.020" stainless steel wire<sup>φ</sup> and further bent towards edentulous span to form buccal and lingual guide wires (Figure 1B).

Desired length of stainless steel closed coil springs<sup>ψ</sup> inserted over both guide wires (Figure 1C).

Guide wires bent towards each other and mesial contour given to them. Extra wire is cut to forms the frame of space maintainer (Figure. 1D, Figure 1E).

0.010" ligature wire woven through the closed coil spring in the direction as shown by arrow (Figure 1F).

Frame fitted into edentulous span and closed loop of ligature encircled around molar crown, free ends pulled tightly and

### \*Corresponding author

Pavankumar J. Vibhute, Department of Orthodontics, Yogita Dental College and Hospital, University of Health sciences, Khed, Ratnagiri, Maharashtra, India, Tel: 91 9823916279; Email: drpavanvibhute@gmail.com

Submitted: 04 August 2017

Accepted: 30 August 2017

Published: 02 September 2017

ISSN: 2333-7133

Copyright

© 2017 Vibhute

OPEN ACCESS

one (lingual) ligature wire passed through gingival embrasure around adjacent tooth. Both free ligature ends pulled at mesio-buccal line angle of premolar (Figure 2A, Figure 2B).

Twisting of ligature wires tighten the grip of space maintainer on both teeth and stabilizes it.

Ligature wire encircled around teeth is bonded with light cure composite cement. Bonding ligature wire on palatal and buccal surface of both teeth prevents slippage of ligature wire in occluso-cervical direction on tooth surface (Figure 2C).

## CASE DISCUSSION

11 year old male child patient reported with premature loss of mandibular second deciduous molar unilaterally. Radiograph shown the presence of succeeding second premolar, but has completed 1/3<sup>rd</sup> root completion. Case was indication for fixed space maintainer and fabricated chair side as per above description. Appliance is placed, ligature wire encircled around


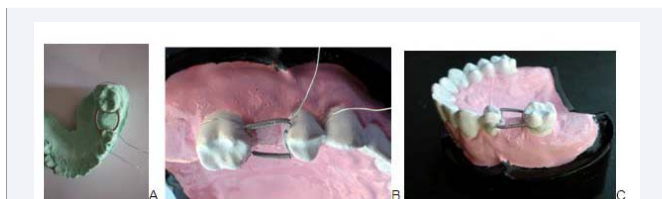
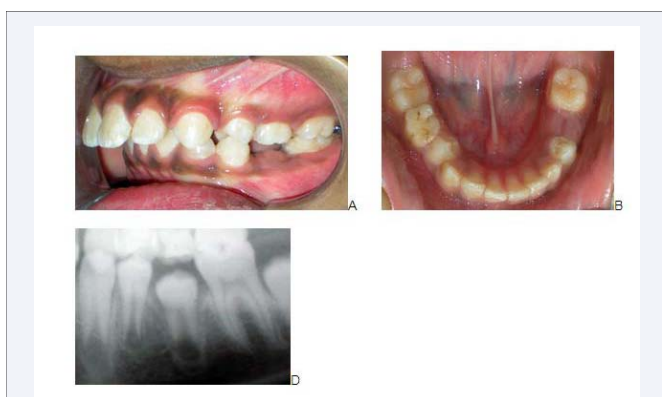


Figure 1 Fabrication of space maintainer.

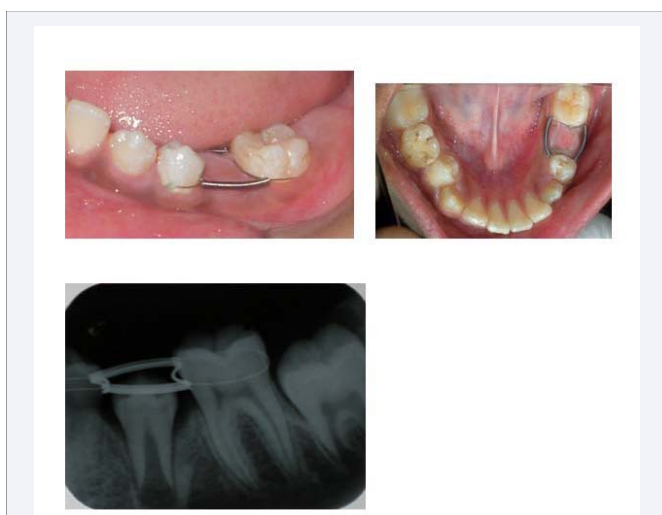
adjacent teeth and twisted and tucked. Ligature wire also bonded with light cure composite cement on buccal aspects of adjacent teeth. Appliance was very comfortable for patient, none of complaint reported with this appliance (Figure 3A-3C, Figure 4). Additionally, flexibility offered by ligature wire provides individual tooth movement and eruptive occlusal adjustment secondary to alveolar growth.



**Figure 2** Method of stabilization of space maintainer.



**Figure 3** Pretreatment patient record showing early-exfoliation of 2nd primary molar.



**Figure 4** Photographic and radiographic record after space maintainer in place.

## ADVANTAGES

It offers the advantages such as,

1. Functional appliance therapy can carried out simultaneously along with this space maintainer.
2. Quick chair-side fabrication and easier placement same day is possible.
3. Concept and design of this space maintainer is universal and can be applied at anterior or posterior locations.
4. It is hygienic and less traumatic to patient.
5. It has good durability.
6. It is more economic.

## CONCLUSION

This fixed space maintainer is easy to fabricate, quick to deliver and comfortable for patient.

## REFERENCES

1. Brothwell DJ. Guidelines on the use of space maintainers following premature loss of primary teeth. *J Can Dent Assoc.* 1997; 63: 764-766.
2. Fathian M, Kennedy DB, Nouri MR. Laboratory-made space maintainers: a 7-year retrospective study from private pediatric dental practice. *Pediatr Dent.* 2007; 29: 500-506.
3. Arikan F, Eronat N, Candan U, Boyacioğlu H. Periodontal conditions associated with space maintainers following two different dental health education techniques. *J Clin Pediatr Dent.* 2007; 31: 229-234.
4. Moore TR, Kennedy DB. Bilateral space maintainers: a 7-year retrospective study from private practice. *Pediatr Dent.* 2006; 28: 499-505.
5. Barbería E, Lucavechi T, Cárdenas D, Maroto M. Free-end space maintainers: design, utilization and advantages. *J Clin Pediatr Dent.* 2006; 31: 5-8.
6. Qudeimat MA, Fayle SA. The longevity of space maintainers: a retrospective study. *Pediatr Dent.* 1998; 20: 267-272.

### Cite this article

Vibhute PJ (2017) 'Single Visit' Fixed Space Maintainer. *JSM Dent* 5(2): 1086.