

## Case Report

# Case with Radiopaque Findings in Gingival Area at the time of Abutment Placement

Yuji Sato, Akio Isobe\*, and Noboru Kitagawa

Department of Geriatric Dentistry, School of Dentistry Showa University, Japan

**\*Corresponding author**

Akio Isobe, Department of Geriatric Dentistry, School of Dentistry Showa University, 2-1-1 Kitasenzoku, Ota Ward, Tokyo 145-8515, Japan, Tel: 81-3-3787-3971; Email: isobeaki@dent.showa-u.ac.jp

Submitted: 23 October 2018

Accepted: 16 November 2018

Published: 19 November 2018

ISSN: 2333-7133

**Copyright**

© 2018 Isobe et al.

**OPEN ACCESS****Abstract**

X-ray examination is important in implant treatment, particularly at the time of abutment mounting in order to assess the condition of the peri-implant bone. On the other hand, there are various pigmented oral mucosal lesions, with metal tattoo being one of the most common. Here, we describe a case with radiopaque findings in the gingival area at the time of abutment placement, and after review of the pre- and post-surgical oral photographs and X-ray images, it confirmed that metal tattoo was the cause of radiopaque findings. Therefore, it is necessary to distinguish such radiopaque findings from those indicating separation of the bone or remaining dentin. When a metal tattoo is present in the oral mucosa, it may lead to radiopaque findings similar to separation of the bone or remaining dentin.

**Keywords**

- Metal tattoo
- X-ray
- Radiopaque findings
- Implant

**INTRODUCTION**

X-ray examination is important in implant treatment, particularly at the time of abutment mounting in order to assess the condition of the peri-implant bone, as well as to confirm the fit between the abutment and dental implant. On the other hand, there are various pigmented oral mucosal lesions, with metal tattoo being one of the most common. But there are few reports about the X-ray view which forms by a metal barrel tattoo.

Here, we describe a case with radiopaque findings in the gingival area at the time of abutment placement, and after review of the pre- and post-surgical oral photographs and X-ray images, it confirmed that metal tattoo was the cause of radiopaque findings [1].

**CASE PRESENTATION****Patient**

73-year-old woman.

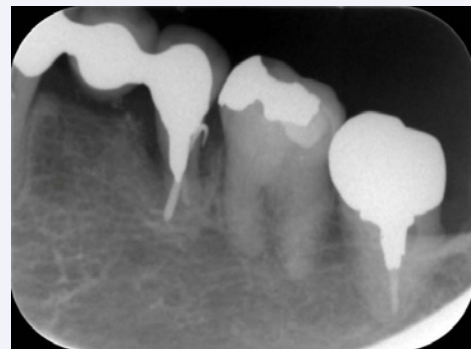
**Medical history**

Patient had hypertension, hyperlipidemia and hypertrophic cardiomyopathy, and was taking Olmesartan (Olmetec ©), Amlodipine (Norvasc ©) and Pitavastatin (Livalo ©).

**Dental history**

The patient visited the Department of Geriatric Dentistry, Showa University Dental Hospital on October 9, 2013, with a chief complaint of difficulty chewing due to poor fit of the upper denture. The upper right second molar (tooth 17) was extracted because of severe dental caries, and the upper denture was

repaired and adjusted. Subsequently, on September 17, 2014, she returned to our hospital complaining of discomfort in the lower left molar region during mastication. The results of exploration and diagnosis of the oral cavity confirmed that the root of the lower left second premolar (tooth 35) was fractured and required extraction (Figure 1). After extraction of tooth 35, as tooth 34 was already missing, an immediate denture was inserted at teeth 34 and 35. Subsequently, the denture was adjusted and repaired. However, the patient wanted further mastication ability, and two fixtures (Branemark System MkIII) of 3.75 mm (length, 10 and 8.5 mm) were placed using the submerged technique at teeth 34 and 35 on May 27, 2015. Second-stage surgery was performed and healing abutments (5 mm diameter × 3 mm height; Nobel Biocare, Zurich, Switzerland) were attached to the fixture. Before impression, abutments (Multi-unit Abutment 1 mm; Nobel Biocare) were attached to the fixture and X-ray images were



**Figure 1** X-ray image before extraction of tooth 35.

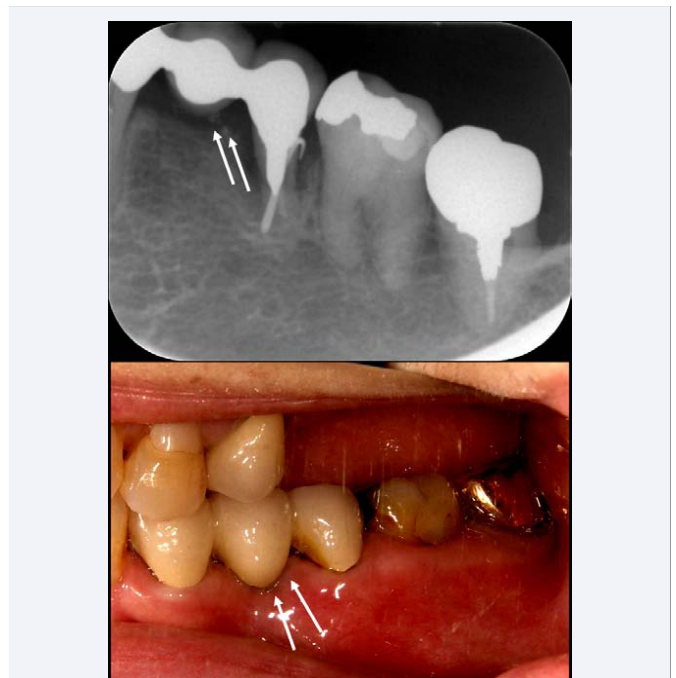obtained in order to confirm the fit between the abutment and fixture. Radiopaque findings were noted in the gingival area (Figure 2) on January 6, 2016. The abutments were then removed in order to assess the mucosa around the fixture, and foreign substances such as cement or bone fragments were not observed. However, a metal tattoo was noted (Figure 3). It considered that might not have been sufficiently confirmed, we re-assessed dental X-ray images and oral photographs obtained before tooth 35 extraction, it had recognized radiopaque findings and the metal tattoo gums that may have penetrated at the time of extraction or preparation of 34 (Figure 4). In addition, oral photographs, dental X-ray images obtained before fixture placement or second-stage surgery, and noted clear point-like the high density structures in the gingival area (Figures 5,6). Incidentally, it was confirmed Computed Tomography (CT) images obtained before fixture placement, also showed a similar opaque image on the mucosa (Figure 7). The degree of radiopacity in the gingival region in X-ray images differed between Figures 2,6.

**Diagnosis**

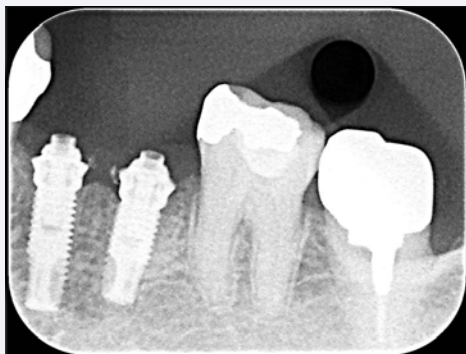Radiopaque findings in the gingival area were caused by metal tattoo.

**Subsequent treatments**

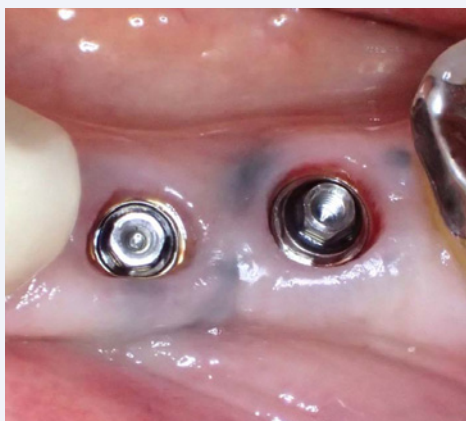Because the site was in the molar region, the patient was not



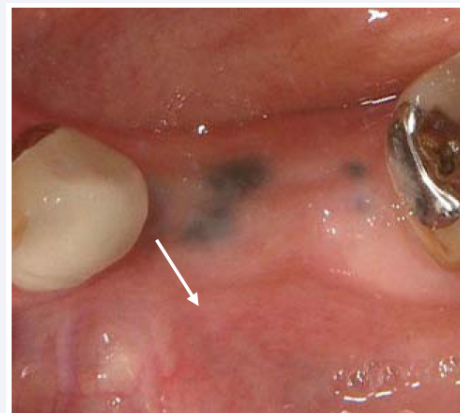**Figure 4** X-ray image and intraoral photo before extraction of tooth 35. Arrows indicate metal tattoo (A) - X-ray image. (B) - Intraoral photo



**Figure 2** X-ray image at the time of abutment placement. Arrows indicate radiopaque findings.



**Figure 3** Intraoral photo at the time of abutment placement. Arrows indicate radiopaque findings and metal tattoo.

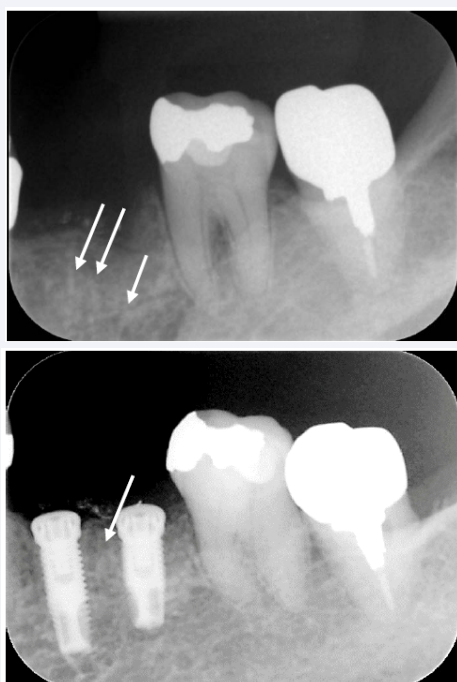

**Figure 5** Intraoral photo before implants placement. Arrows indicate radiopaque findings

concerned about the pigmented gingival lesions, and we intend to fabricate an implant-supported prosthesis and observe the pigmented gingival lesions during routine checkups.

**DISCUSSION**

If metal tattoos are present in the oral mucosa, it is necessary to recognize that they may cause radiopaque findings on X-ray images. Depending on when the X-ray images are taken, radiopaque findings can vary from clear point-metal-like opaque image boundaries to opaque image with unclear bone-like boundaries. Therefore, it is necessary to distinguish such radiopaque findings from those indicating separation of the bone

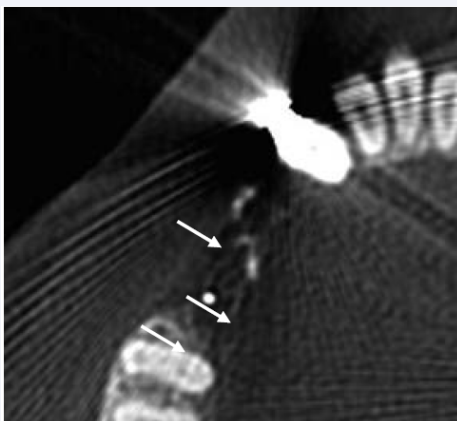


**Figure 6** Comparison of X-ray image before and after implants placement

Arrows indicate radiopaque findings

(A) - X-ray image before implants placement

(B) - X-ray image after implants placement



**Figure 7** Computed Tomography (CT) image before implants placement.

Arrows indicate the high density structures

or remaining dentin. In addition, if the prosthetic device is fixed with dental cement, if the prosthetic device is fixed with dental cement, its opaque image may need to be distinguished from dental cement.

As metal tattoos cause aesthetic problems such as anterior region, surgical removal may be necessary if the patient is determined. Though this case are not related to aesthetics, metal tattoos may cause metal allergy which may affect the surrounding healing and chronic inflammation of the implant. Therefore, we will check up the metal tattoos of this patient carefully. Moreover, removing metal restorations for re-treatment is necessary, and dentists should pay close attention to avoid causing metal tattoos [2-5].

## CONCLUSIONS

When a metal tattoo is present in the oral mucosa, it may lead to radiopaque findings similar to separation of the bone or remaining dentin.

## CONFLICT OF INTEREST

The author(s) declare(s) that there are no conflicts of interest regarding the publication of this paper.

## REFERENCES

1. Brägger U, Bürgin W, Lang NP, Buser D. Digital subtraction radiography for the assessment of changes in peri-implant bone density. *Int J Oral Maxillofac Implants.* 1991; 6: 160-166.
2. McGinnis JP Jr, Greer JL, Daniels DS. Amalgam tattoo: report of an unusual clinical presentation and the use of energy dispersive X-ray analysis as an aid to diagnosis. *J Am Dent Assoc.* 1985; 110: 52-54.
3. Hassona Y, Sawair F, Al-Karadshah O, Scully C. Prevalence and clinical features of pigmented oral lesions. *Int J Dermatol.* 2016; 55: 1005-1013.
4. Gojkov-Vukelic M, Hadzic S, Pasic E. Laser treatment of oral mucosa tattoo. *Acta Inform Med.* 2011; 19: 244-246.
5. Buchner A. Amalgam tattoo (amalgam pigmentation) of the oral mucosa: clinical manifestations, diagnosis and treatment. *Refuat Hapeh Vehashinayim.* 2004; 21: 25-28.

### Cite this article

Sato Y, Isobe A, Kitagawa N (2018) Case with Radiopaque Findings in Gingival Area at the time of Abutment Placement. *JSM Dent* 6(3): 1113.