

## Research Article

# Serotonin Effectors Expressed during Palatogenesis: An Immunohistochemical Study

Hirata A<sup>1\*</sup>, Imura H<sup>2</sup>, Sugahara T<sup>2</sup>, Natsume N<sup>2</sup>, Nakamura H<sup>3</sup>, and Kondo Y<sup>1</sup>

<sup>1</sup>Department of Anatomy and Cell Biology, Osaka Medical College, Japan

<sup>2</sup>Division of Research and Treatment for Oral and Maxillofacial Congenital Anomalies, Aichi-Gakuin University, Japan

<sup>3</sup>Department of Oral Histology, Matsumoto Dental University, Japan

**\*Corresponding author**

Azumi Hirata, Department of Anatomy and Cell Biology, Osaka Medical College, 2-7 Daigaku-machi, Takatsuki, Osaka 569-8686, Japan, Tel: 81-72-684-7197; E-mail: 1026@osaka-med.ac.jp

**Submitted:** 25 September 2018

**Accepted:** 29 November 2018

**Published:** 03 December 2018

**ISSN:** 2333-7133

**Copyright**

© 2018 Hirata et al.

**OPEN ACCESS****Keywords**

- Serotonergic regulation
- Monoamine oxidase (MAO)
- Tryptophan hydroxylase (TPH)
- Palate formation
- Selective serotonin reuptake inhibitor (SSRI)

**Abstract**

Serotonin transporter (SERT) is one of the most critical regulators of the orchestration of serotonin (5-hydroxytryptamine; 5-HT) signaling through removal of extracellular 5-HT. Early studies have shown that 5-HT regulates craniofacial morphogenesis through interaction with 5-HT receptors or SERT. To determine the characteristics of 5-HT and SERT in palate development, we examined their localization immunohistochemically during secondary palate formation in mice. We also examined the immunolocalization of monoamine oxidase (MAO), a major metabolic enzyme of 5-HT, and tryptophan hydroxylase (TPH), a synthetic enzyme of 5-HT, to clarify their relationship with 5-HT in palatogenesis. Immunohistochemically, in the palatal shelves in the vertical position, diffuse localization of 5-HT was observed in the palatal mesenchyme, whereas SERT, MAO, and TPH immune reactivities were weak. When the palatal shelves were oriented horizontally, similar immune reactivities of 5-HT, SERT, MAO, and TPH were observed in the cells of the outer epithelial layer of the palatal shelf. In addition, 5-HT, SERT, MAO, and TPH immunoreactivities were detected in the medial epithelial seam (MES) of fused palatal shelves, and with the progression of palate formation, these immunoreactivities were subsequently observed in the basal and middle layers of the palatal epithelium. These findings suggest that serotonergic regulation via SERT is involved in palatogenesis, particularly in the development of the palatal epithelium. Our findings imply that altered 5-HT metabolism increases the risk of congenital craniofacial anomalies, such as clefting, in the children of women who are exposed to selective serotonin reuptake inhibitors (SSRIs) during pregnancy

**INTRODUCTION**

Secondary palate morphogenesis is regulated in multiple steps by several transcription factors and extracellular matrix [1-5]. These signals mediate communication between epithelial and mesenchymal cells. Thus, inappropriate epithelial-mesenchymal interaction can cause cleft palate and/or lip [6].

Serotonin (5-hydroxytryptamine; 5-HT) is a neurotransmitter in the central and peripheral nervous systems. The functions of 5-HT in the central nervous system (CNS) are multifaceted with its controlling appetite, sleep, memory and learning, temperature regulation, mood, sexual and hallucinogenic behavior, and endocrine regulation [7]. Peripherally, 5-HT is stored in platelets and in the intestinal wall, and appears to play a certain role in blood pressure regulation, cardiovascular function, motility of the gastrointestinal tract, and carcinoid tumor pathology. Interestingly, 5-HT and its receptors in early embryogenesis have been suspected to regulate cranial neural crest cell proliferation [8], migration [9,10] and the formation of craniofacial neural

crest-derived tissues [11-16]. Additionally, previous studies have demonstrated the presence of 5-HT in the palatal shelves just prior to shelf elevation [17], and some serotonin receptor (5-HTR) antagonists inhibited rotation of the palatal shelves in embryo culture studies [18]. These reports suggest that 5-HT is synthesized in the palatal shelves during mid-gestational craniofacial morphogenesis and that rotation of the palatal shelves is regulated through 5-HT-5-HTR signaling.

The serotonin transporter (SERT) is one of the most critical regulators of 5-HT signaling, as it removes extracellular 5-HT, taking it back into SERT-expressing cells. It is well established that SERT is localized in presynaptic membranes of 5-HT neurons in the CNS [19]. It has also been reported that SERT is expressed in osteoclasts [20], heart valves of the developing mouse heart [21], and developing pulmonary artery smooth muscle cells (PASMC) [22-24], suggesting that 5-HT and its regulation by SERT play active roles in the development of some organs. Intriguingly, transient expression of SERT during the period of craniofacial

morphogenesis has been reported [25]. On the other hand, metabolism of 5-HT is carried out by the enzyme monoamine oxidase (MAO), which occurs as two molecular subtypes called MAO-A and MAO-B. Both subtypes have widespread occurrence in the brain and peripheral tissues, although they show some differences, including species-related variations, with respect to the extent of their presence in certain tissues and cell types [26]. Moreover, the biochemical pathway for 5-HT synthesis is performed through multistep enzyme reactions. Tryptophan hydroxylase-1 (TPH-1) and TPH-2 facilitate the first and rate-limiting step in the biosynthesis of 5-HT, the conversion of L-tryptophan to 5-hydroxy-L-tryptophan [27].

In the present study, using immunohistochemistry (IHC), we determined SERT and 5-HT localization in the developing murine palate during late-gestation. We also performed IHC for MAO and TPH during palatogenesis and demonstrated their relationship with palate development.

## MATERIALS AND METHODS

The Institutional Animal Care and Use Committee of Osaka Medical College approved all the following research protocols (approval ID: 28037), including the histological procedures.

### Tissue preparation for histology

Pregnant female C57BL/6By mice (n=6) that were purchased from Japan SLC, Inc. (Shizuoka, Japan) were euthanized with CO<sub>2</sub> and embryos were then harvested at embryonic day (E) 13.5, E14.5, and E15.5. The heads of 24 embryos and four newborn mice (P0) were dissected and immersed in 4% paraformaldehyde and 0.1% glutaraldehyde in 0.05M phosphate buffer (pH 7.4) for 20h at 4°C, and were subsequently decalcified in 5% ethylenediaminetetraacetic acid (EDTA) (pH 7.4) for 2 days at 4°C.

For light microscopy, specimens were dehydrated in a graded ethanol series and embedded in paraffin. Sections (4 μm) were prepared, dewaxed with xylene and then stained with hematoxylin and eosin.

### Immunohistochemistry

Specimens were dewaxed with xylene and a graded ethanol series, and serial sections were prepared. For immunohistochemical study, the sections were transferred to 5 mM periodic acid for 10 min at room temperature (RT) to block endogenous peroxidase, and were then immersed in PBS containing 10% BSA for 30 min. After washing in PBS, the sections were incubated with anti-5-HT (Nichirei Biosciences, Inc., Tokyo, Japan), anti-SERT (Sigma-Aldrich, Inc., St. Louis, MO, USA; diluted 1:500), anti-MAO-A+B (Bioss, Inc., Woburn, MA, USA; diluted 1:400) or anti-TPH-1+2 polyclonal antibodies (Bioss; diluted 1:200) for 12h at 4°C. Sections were then incubated with a secondary antibody: ChemMate EnVision (Dako Cytomation, Glostrup, Denmark) for 1h at RT. Immunoreactivity was visualized by incubation with 3,3'-diaminobenzidine (DAB) (Nichirei Biosciences) for 10min at RT. Sections were then counterstained with methyl green, dehydrated, and observed under a light/fluorescence microscope (BZ-X700; Keyence, Osaka, Japan) with BZ Analyzer Software (BZ-X700; Keyence).

For the immunofluorescence study, sections were incubated with each primary antibody for 12h at 4°C. Sections were then incubated with Alexa Fluor 488 goat anti-rabbit IgG (Molecular Probes) diluted 1:200 for 1h at RT. Sections were then examined using a BZ-X700 with BZ Analyzer Software.

Control sections were incubated with rabbit preimmune serum or without primary antibody. These immunohistochemical staining procedures were performed in a total of 100 serial sections from each animal. Positive staining was not observed in any of this control sections.

## RESULTS

### Palate formation

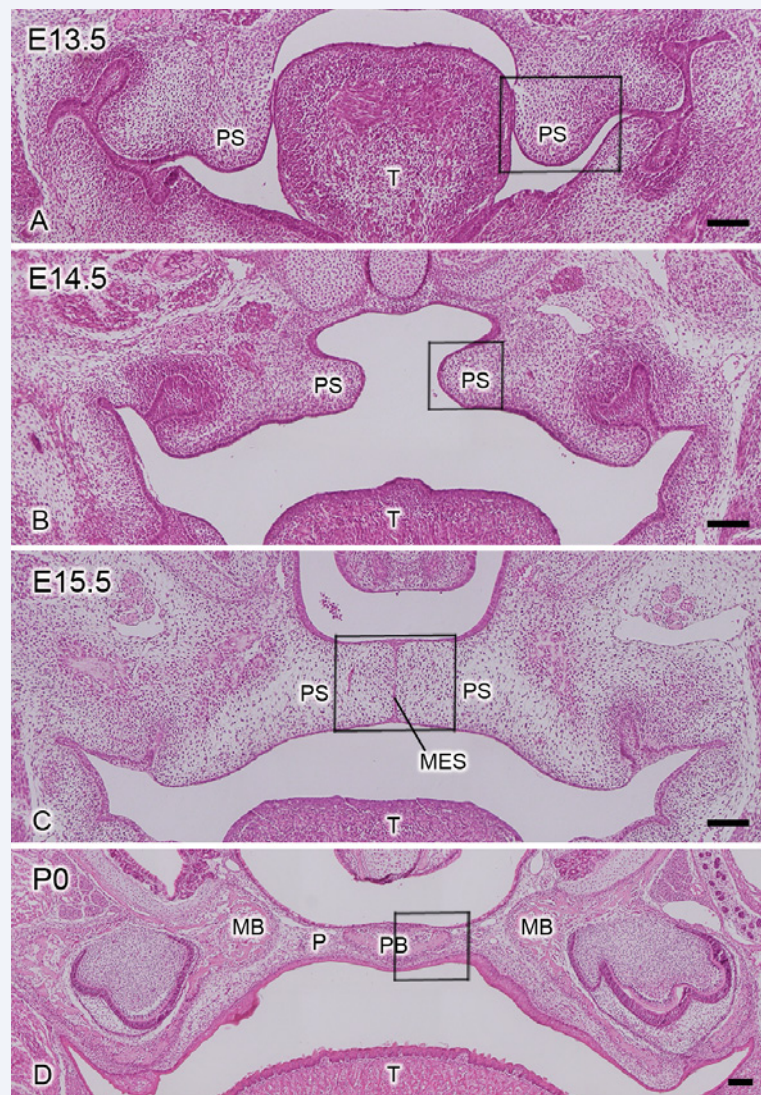
The palatal shelves were located vertically along the sides of the tongue at E13.5 (Figure 1A). At E14.5, the shelves were oriented horizontally (Figure 1B). By E15.5, the bilateral palatal shelves had fused with each other and the medial epithelial seam (MES) was observed at the midline (Figure 1C). At P0, palatogenesis had progressed: the oral and nasal surfaces of the palate were covered with mucosa, and the palatal and maxillary bones were observed in the palate (Figure 1D).

### Localization of 5-HT, SERT, MAO, and TPH during Palatogenesis

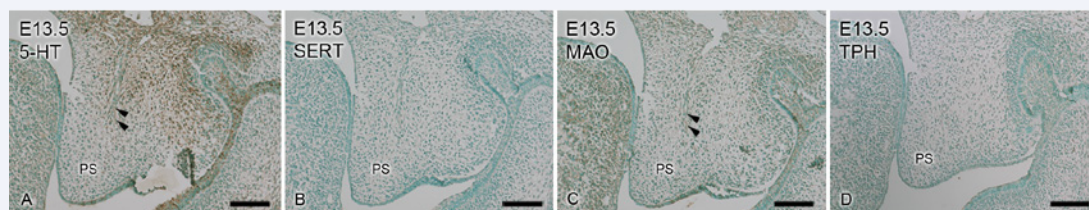
At E13.5, immunohistochemical analysis detected intense 5-HT immunoreactivity in the palatal mesenchyme located at the bottom of the palatal shelf (Figure 2A), whereas only weak SERT labeling was observed in the palatal shelf (Figure 2B). Moderate MAO immunoreactivity localized diffusely in the palatal shelf, while that of TPH was weak (Figures 2C,2D). At E14.5, both 5-HT and SERT labeling were detected in the epithelial cells at the tip of the palatal shelf (Figures 3A,3B). Moreover, the epithelial cells at the edge of the palatal shelf were labeled with both MAO and TPH (Figures 3C,3D). At E15.5, the cells of the MES and the epithelial triangle were labeled with both 5-HT and SERT (Figures 4A,4B). Positive immunoreactivities of MAO and TPH were observed in the cells of the MES and the epithelial triangle (Figures 4C,4D). In the oral epithelium of the palate at P0, strong immunoreactivity for both 5-HT and SERT was detected in the cells of the palatal epithelium (Figures 5A,5B). In addition, both MAO and TPH were detected in the cells of the oral epithelium and in osteoblasts on the palatal bone surface (Figures 5C, 5D). In the higher magnification of the oral epithelium, intense immunofluorescent reactivity of 5-HT, SERT, MAO, and TPH were clearly detected in the cells of the middle and basal layer of the oral epithelium (Figures 5E-5H).

## DISCUSSION

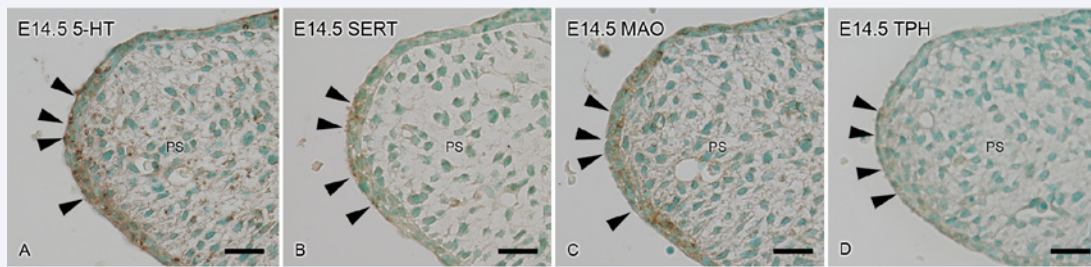
In this study, we demonstrated the immunohistochemical localization of 5-HT, SERT, MAO, and TPH during palate formation in mice. At the initial stage of palate formation, 5-HT was diffusely localized in the palatal mesenchyme. 5-HT has been shown to stimulate palatal shelf rotation in embryo culture [18] and to facilitate palatal mesenchymal cell movement in cell culture [28]. Our results are consistent with the report by Zimmerman et al. [17], indicating that 5-HT was present in the palatal shelf and the highest level of 5-HT was observed just



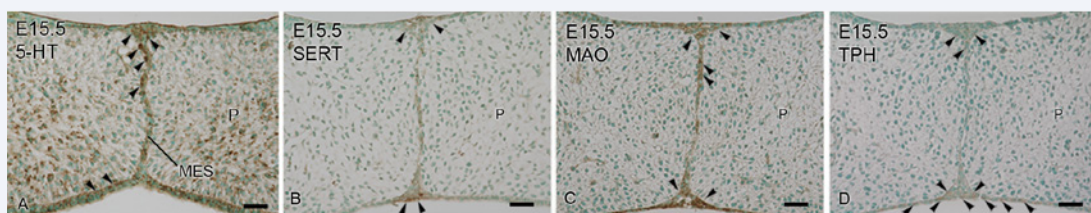
**Figure 1** Light micrographs of the murine palate at the palate forming stage stained with hematoxylin and eosin. (A) The bilateral palatal shelves are positioned vertically at the sides of the tongue at E13.5 (B) The shelves are oriented horizontally at E14.5 (C) The medial epithelial seam (MES) is observed at the middle of the fused palatal shelves at E15.5 (D) The oral and nasal mucosa are seen on the surface of the palate and the palatal and maxillary bones are observed in the palate at P0. PS, palatal shelf; T, tongue; MES, medial epithelial seam; P, palate; MB, maxillary bone; PB, palatal bone. Insets in A, B, C, and D are as shown in Figures 2, 3, 4, and 5, respectively. Bars = 100µm.



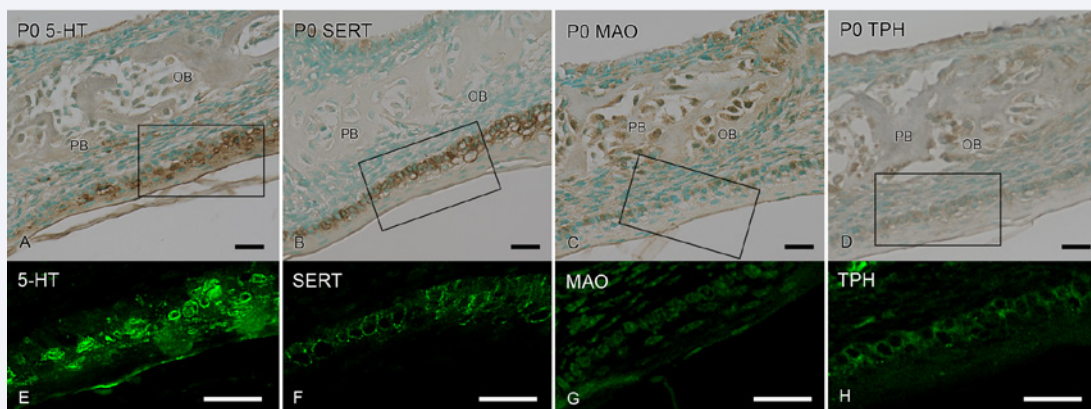
**Figure 2** Immunohistochemical localization of 5-HT, SERT, MAO and TPH in the murine palate at E13.5 (A) Intense 5-HT immunoreactivity is observed in the palatal mesenchyme located at the bottom of the palatal shelf. 5-HT immunoreactivity is also seen in the palatal nerve (arrowheads) (B) Weak SERT labeling is seen in the palatal shelf (C) Diffuse MAO immunoreactivity is also observed in the palatal shelf. MAO immunoreactivity is seen in the palatal nerve (arrowheads) (D) Weak TPH labeling is seen in the palatal shelf. PS, palatal shelf. Bars = 100µm.



**Figure 3** Light micrographs showing the immunohistochemical localization of 5-HT, SERT, MAO, and TPH in the murine palate at E14.5 (A) 5-HT-positive cells are observed at the tip of the palatal epithelium (arrowheads) (B) SERT-positive cells are observed at the tip of the palatal epithelium (arrowheads) (C) MAO-positive cells are observed at the tip of the palatal epithelium (arrowheads) (D) TPH-positive cells are observed at the tip of the palatal epithelium (arrowheads). PS, palatal shelf. Bars=25 μm.



**Figure 4** Immunohistochemical localization of 5-HT, SERT, MAO, and TPH in the murine palate at E15.5 (A) The cells of the MES and the epithelium of the fused palate show 5-HT immunoreactivity (arrowheads) (B) The cells of the MES and the epithelial triangle (arrowheads) show SERT reactivity (C) The cells of the MES and the epithelial triangle show MAO reactivity (arrowheads) (D) The cells of the MES and the epithelium of the fused palate show TPH reactivity (arrowheads). P, palate; MES medial epithelial seam. Bars =25 μm.



**Figure 5** Light (A-D) and fluorescent (E-H) micrographs showing the immunohistochemical localization of 5-HT (A, E), SERT (B, F), MAO(C, G), and TPH (D, H)in the murine palate at P0. Each immunolocalization is observed in the palatal epithelium. Osteoblasts (OB) also show MAO (C) and TPH (D) immunoreactivity. (E-H) Higher magnifications of the rectangles in A-D respectively. (E) 5-HT immunoreactivity is observed in the middle and basal layer of the palatal epithelium. (F)SERT is observed around the cells of the middle and basal layers of the palatal epithelium.(G)MAO is observed in the middle and basal layers of the palatal epithelium. (H)TPH immunolocalization is observed in the middle and basal layers of the palatal epithelium. PB, palatal bone; OB, osteoblasts. Bars=25 μm.

prior to palate elevation. Our data also suggested that, at this same stage, MAO was diffusely localized in palatal mesenchymal cells, although only faint SERT and TPH immunoreactivities were detected in the palatal shelf. These findings suggest that 5-HT plays an important role in palatogenesis, particularly in palate rotation, and that serotonergic metabolism by MAO

maybe involved in the proliferation of the mesenchymal cells of the palatal shelves. Recent studies have demonstrated that MAO-B is strongly expressed in neural crest derivatives, such as cranial mesenchyme, dental mesenchyme, and several soft palate derivatives [29], moreover, maternal TPH-1-dependent 5-HT is involved in the control of morphogenesis during developmental

stage and 5-HT is critical for normal murine development [30].

Just prior to fusion of the palatal shelves, the epithelium covering the medial edge of the palatal shelves is known to comprise two layers [31]. It has been proposed that these two epithelial layers have different fates during palatal fusion [32,33]. After the shelves have elevated, some cells of the outer layer appear to gradually peel off from the epithelial surface. Some of the remaining cells appear to be trapped between the opposing shelves, and subsequently, they either die by apoptosis [32,34], migrate to the oral and nasal side of the palate [34,35], or become a part of the medial epithelial seam (MES) with the cells of the basal layer during the process of palatal fusion. In the present study, as the palatal shelves progressed to elevation at E14.5, 5-HT, SERT, MAO, and TPH immunoreactivities were observed in the epithelial cells located at the tip of the palatal shelf. At E15.5, after the bilateral palatal shelves were connected, the cells of the MES and epithelial triangle showed immunoreactivities for 5-HT, SERT, MAO, and TPH. In contrast, mesenchymal cells in the palatal shelves diffusely expressed 5-HT, SERT, MAO and TPH at E14.5 and E15.5, although their expression was weak at these time points, whereas 5-HT expression was strong at E15.5. Thus, these results suggested that 5-HT, SERT, MAO, and TPH are concerned with the processes of palatal shelves growth: elevation, contact, fusion, elongation, and mesenchymal proliferation and differentiation. Moreover, 5-HT may participate in apoptosis, migration, and/or epithelial-mesenchymal transformation, which are the mechanisms by which the MES disappears [1].

We found that, at P0, 5-HT, SERT, and MAO were localized mostly in the basal and middle layer of the oral epithelium, and their labeling patterns resembled one another. This is supported by a previous study showing that the oral cavity displays a very intense SERT expression that lines the endothelium of the tongue and palate [36]. Recent studies have demonstrated that 5-HT regulates epithelial cell turnover through three specific events; i.e., cell shedding, tight junction breakdown, and intra-epithelial apoptosis [37]. Based on our study, it is highly probable that 5-HT regulates turnover, differentiation, proliferation, and the fate of palatal epithelial cells during palate formation. We also demonstrated that, as palate formation progressed, intense immunoreactivities of MAO and TPH were observed in osteoblasts around palatal bone at P0, suggesting that osteoblasts express a functional serotonergic regulation by direct and/or indirect mechanisms [38-40].

In conclusion, we provided evidence that 5-HT, SERT, MAO, and TPH are expressed in the epithelial cells of palatal shelves, MES cells, and in the oral epithelial cells of the palate with the progression of palate formation. We also demonstrated that 5-HT, SERT, MAO, and TPH immunoreactivities were observed in the palatal shelves during palate formation. These results suggest that serotonergic regulation contributes to palate development. Moreover, our results suggest that the children of another who had taken selective serotonergic reuptake inhibitors (SSRIs) during pregnancy would be at a higher risk for craniofacial malformations [41]. SSRIs administered during pregnancy are likely to influence the 5-HT-mediated events during palate development. Further research on the precise function of 5-HT and SERT in conjunction with the synthesis and metabolism of

5-HT during palate formation is required.

## ACKNOWLEDGEMENTS

We would like to express special thanks to Emeritus Professor Norikazu Ohno, School of Dentistry, Aichi-Gakuin University, for his valuable advice and kind support. This work was supported in part by Grants-in-Aid for Scientific Research (Nos. 24592996, 16K11772, and 16K11773) from the Japan Society for the Promotion of Science. The authors declare no potential conflicts of interest with respect to the authorship and/or publication of this article.

## REFERENCES

1. Bush JO, Jiang R. Palatogenesis: morphogenetic and molecular mechanisms of secondary palate development. *Development*. 2012; 139: 231-243.
2. Smith TM, Lozanoff S, Iyyanar PP, Nasarali AJ. Molecular signaling along the anterior-posterior axis of early palate development. *Front Physiol*. 2012; 3: 488.
3. Hirata A, Katayama K, Tsuji T, Natsume N, Sugahara T, Koga Y, et al. Heparanase localization during palatogenesis in mice. *Bio Med Res Int*. 2013; 2013: 760236.
4. Hirata A, Katayama K, Tsuji T, Imura H, Natsume N, Sugahara T, et al. Homeobox family Hoxc localization during murine palate formation. *Congenit Anom (Kyoto)*. 2016; 56: 172-179.
5. Lambert HW, Lauder JM. Serotonin receptor agonists that increase cyclic AMP positively regulate IGF-I in mouse mandibular mesenchymal cells. *Dev Neurosci*. 1999; 21: 105-112.
6. Gritli-Linde A. Molecular control of secondary palate development. *Dev Biol*. 2007; 301: 309-326.
7. Torres GE, Gainetdinov RR, Caron MG. Plasma membrane monoamine transporters: structure, regulation and function. *Nat Rev Neuroscience*. 2003; 4: 13-25.
8. Bhasin N, LaMantia AS, Lauder JM. Opposing regulation of cell proliferation by retinoic acid and the serotonin 2B receptor in the mouse frontonasal mass. *Anat Embryol (Berl)*. 2004; 208: 135-143.
9. Moiseiwitsch JRD. The role of serotonin and neurotransmitters during craniofacial development. *Crit Rev Oral Biol Med*. 2000; 11: 230-239.
10. Choi DS, Ward SJ, Messaddeq N, Launay JM, Maroteaux L. 5-HT<sub>2B</sub> receptor-mediated serotonin morphogenetic functions in mouse cranial neural crest and myocardial cells. *Development*. 1997; 124: 1745-1755.
11. Hansson SR, Mezey E, Hoffman BJ. Serotonin transporter messenger RNA expression in neural crest-derived structures and sensory pathways of the developing rat embryo. *Neuroscience*. 1999; 89: 243-265.
12. Lauder JM, Tamir H, Sadler TW. Serotonin and morphogenesis. I. Sites of serotonin uptake and -binding protein immunoreactivity in the mid gestation mouse embryo. *Development*. 1988; 102: 709-720.
13. Moiseiwitsch JR, Lauder JM. Stimulation of murine tooth development in organotypic culture by the neurotransmitter serotonin. *Arch Oral Biol*. 1996; 41: 161-165.
14. Moiseiwitsch JR, Raymond JR, Tamir H, Lauder JM. Regulation by serotonin of tooth-germ morphogenesis and gene expression in mouse mandibular explant cultures. *Arch Oral Biol*. 1998; 43: 789-800.
15. Ori M, Lucchini SD, Marras G, Nardi I. Unraveling new roles for

- serotonin receptor 2B in development: key findings from *Xenopus*. *Int J Dev Biol*. 2013; 57: 707-714.
16. Bashammakh S, Wurtele M, Kotnik K, Seyfried SA, Bader M. Serotonin is required for pharyngeal arch morphogenesis in zebrafish. *Sci Open Res*. 2014; 1-9.
  17. Zimmerman EF, Wee EL, Phillips N, Roberts N. Presence of serotonin in the palate just prior to shelf elevation. *J Embryol exp Morph*. 1981; 64: 233-250.
  18. Wee EL, Babiartz BS, Zimmerman S, Zimmerman EF. Palate Morphogenesis IV. Effect of serotonin and its antagonists on rotation in embryo culture. *J Embryol exp Morph*. 1979; 53: 75-90.
  19. Zhou FC, Sari Y, Zhang JK. Expression of serotonin transporter protein in developing rat brain. *Brain Res Dev Brain Res*. 2000; 119: 33-45.
  20. Battaglino R, Fu J, Späte U, Ersoy U, Joe M, Sedaghat L, et al. Serotonin regulates osteoclast differentiation through its transporter. *J Bone Miner Res*. 2004; 19: 1420-1431.
  21. Pavone LM, Spina A, Muto RL, Santoro D, Mastellone V, Avallone L. Heart valve cardiomyocytes of mouse embryos express the serotonin transporter SERT. *Biochem Biophys Res Commun*. 2008; 377: 419-422.
  22. Lee SL, Wang WW, Moore BJ, Fanburg BL. Dual effect of serotonin on growth of bovine pulmonary artery smooth muscle cells in culture. *Circ Res*. 1991; 68: 1362-1368.
  23. Eddahibi S, Fabre V, Boni C, Martres MP, Raffestin B, Hamon M, et al. Induction of serotonin transporter by hypoxia in pulmonary vascular smooth muscle cells. Relationship with the mitogenic action of serotonin. *Circ Res*. 1999; 84: 329-336.
  24. Marcos E, Fadel E, Sanchez O, Humbert M, Dartevelle P, Simonneau G, et al. Serotonin-induced smooth muscle hyperplasia in various forms of human pulmonary hypertension. *Circ Res*. 2004; 94: 1263-1270.
  25. Lauder JM, Zimmerman EF. Sites of serotonin uptake in epithelia of the developing mouse palate, oral cavity, and face: possible role in morphogenesis. *J Craniofac Genet Dev Biol*. 1988; 8: 265-276.
  26. Berry MD, Juorio AV, Paterson IA. The functional role of monoamine oxidases A and B in the mammalian central nervous system. *Prog Neurobiol*. 1994; 42: 375-391.
  27. Walther DJ, Bader M. A unique central tryptophan hydroxylase isoform. *Biochem Pharmacol*. 2003; 66: 1673-1680.
  28. Zimmerman EF. Palate morphogenesis: role of contractile proteins and neurotransmitters. In: Persaud TVN, editor. *Advances in the study of birth defects. Abnormal Embryogenesis: Cellular and Molecular Aspects*. Chapter 9. UK: MTP Press. P. 1979; 3: 143-159.
  29. Vitalis T, Alvarez C, Chen K, Shin JC, Gaspar P, Cases O. Developmental expression pattern of monoamine oxidases in sensory organs and neural crest derivatives. *J Comp Neurol*. 2003; 464: 392-403.
  30. Cote F, Fligny C, Bayard E, Launay JM, Gershon MD, Mallet J, et al. Maternal serotonin is crucial for murine embryonic development. *Proc Natl Acad Sci USA*. 2007; 104: 329-334.
  31. Holtgrave EA, Stoltenberg-Didinger G. Apoptotic epithelial cell death: a prerequisite for palatal fusion. An in vivo study in rabbits. *J Cranio-Maxillofac Surg*. 2002; 30: 329-336.
  32. Fitchett JE, Hay ED. Medial edge epithelium transforms to mesenchyme after embryonic palatal shelves fuse. *Dev Biol*. 1989; 131: 455-474.
  33. Taya Y, O'Kane S, Ferguson MW. Pathogenesis of cleft palate in TGF-beta3 knockout mice. *Development*. 1999; 126: 3869-3879.
  34. Cuervo R, Covarrubias L. Death is the major fate of medial edge epithelial cells and the cause of basal lamina degradation during palatogenesis. *Development*. 2004; 131: 15-24.
  35. Jin JZ, Ding J. Analysis of cell migration, transdifferentiation and apoptosis during mouse secondary palate fusion. *Development*. 2006; 133: 3341-3347.
  36. Narboux-Neme N, Pavone LM, Avallone L, Zhuang X, Gaspar P. Serotonin transporter transgenic (SERT<sup>cre</sup>) mouse line reveals developmental targets of serotonin specific reuptake inhibitors (SSRIs). *Neuropharmacology*. 2008; 55: 994-1005.
  37. Pai VP, Horseman ND. Multiple cellular responses to Serotonin contribute to epithelial homeostasis. *PLoS One*. 2011; 6: e17028.
  38. Warden SJ, Robling AG, Haney EM, Turner CH, Blizotes MM. The emerging role of serotonin (5-hydroxytryptamine) in the skeleton and its mediation of the skeletal effects of low-density lipoprotein receptor-related protein 5 (LRP5). *Bone*. 2010; 46: 4-12.
  39. Battaglino R, Fu J, Spate U, Ersoy U, Joe M, Sedaghat L, et al. Serotonin Regulates Osteoclast Differentiation Through Its Transporter. *J Bone Miner Res*. 2004; 19: 1420-1431.
  40. Hodge JM, Wang Y, Berk M, Collier FM, Fernandes TJ, Constable MJ, et al. Selective serotonin reuptake inhibitors inhibit human osteoclast and osteoblast formation and function. *Biol Psychiatry*. 2013; 74: 32-39.
  41. Shuey DL, Sadler TW, Lauder JM. Serotonin as a regulator of craniofacial morphogenesis: site specific malformations following exposure to serotonin uptake inhibitor. *Teratology*. 1992; 46: 367-378.

#### Cite this article

Hirata A, Imura H, Sugahara T, Natsume N, Nakamura H, et al. (2018) Serotonin Effectors Expressed during Palatogenesis: An Immunohistochemical Study. *JSM Dent* 6(3): 1115.