

Review Article

The Influence of Gene Mutations on Bone and Teeth Mineralization: Osteogenesis and Dentinogenesis Imperfecta

Michel GOLDBERG*

Department of Oral Biology, Paris Cité University, France

*Corresponding author

Michel GOLDBERG, Department of Oral Biology, Faculty of Fundamental and Biomedical Sciences, INSERM UMR-S1124, Paris Cité University, 45 rue des Saints Pères 75006, Paris, France ; Tel : 33 6 62 67 67 09 ; Email : mgoldod@gmail.com

Submitted: 02 July 2020

Accepted: 14 July 2020

Published: 16 July 2020

ISSN: 2333-7133

Copyright

© 2020 GOLDBERG M

OPEN ACCESS

Keywords

- Osteogenesis imperfecta
- Dentinogenesis imperfecta
- Dentin dysplasia
- Collagen type I
- Non-collagenous extracellular matrix proteins
- Gene coding protein mutations

Abstract

Osteogenesis imperfecta (OI) is an inherited disorder generating skeletal fragility. It is usually caused by mutations in one of the two genes encoding type I collagen (COL1A1, COL1A2). The mutations result in a decreased synthesis or the formation of abnormal extracellular proteins. OI has been divided into four subtypes: Classic non-deforming OI with blue sclerae (type I), perinatally lethal OI (Type II), progressively deforming OI (Type III), common variable OI with normal sclerae (type IV). Type I OI is the mildest form. The fracture rate is increased, but without significant deformity or height deficit. Type II is lethal during the neonatal period. The most severe form in patients surviving the neonatal period is type III OI, Type IV comprises patients with phenotype intermediate to types I and III. Recently, other types of OI (V–XV) have been identified. Although they phenotypically resemble to types I–IV, they are not associated with type I collagen mutations. Dentinogenesis imperfecta (DI), associated or not with OI, was classified in five types: Dentin Dysplasia types I and II (DD1 & DD2) and dentinogenesis imperfecta (DGI-types I–III). The critical loci of the mutation is located on chromosome 4q21, coding namely for DSPP. Cleavage of DSPP gives rise to three molecules susceptible to mutations, respectively DSP (dentin sialoprotein), DGP (dentin glycoprotein) and DPP (dentin phosphoprotein). Gray or brown teeth may appear translucent and characterize DI. Pharmacological treatments contribute to reduce the pain and adverse effects of OI, whereas cells and genes therapies need improvements.

INTRODUCTION

Classification of the disease: mutations of the genes coding for extracellular proteins

Osteogenesis imperfect: Bone fragility is the hallmark clinical feature of osteogenesis imperfecta (OI). The most prominent effect of the disease is fragile bone that leads to recurrent fractures (even in consequence of very mild traumas) and skeletal deformities. All tissues rich in type 1 collagen can be affected.

Patients may have blue sclera, hearing loss, dentinogenesis imperfecta (DI), growth deficiency, joint laxity, or any combination of these characteristics. Sillence et al. [1], proposed the first classification of Osteogenesis Imperfecta (OI) (Types I–IV). It was expanded later, with types V–VIII, due to distinct clinical feature and causative genes [1–3], and nowadays, gene mutations cause abnormal structures up to type XV [4,5]. These publications described osteogenesis imperfecta type XV, an autosomal recessive form of the disorder characterized by early-onset recurrent fractures, bone deformity, significant reduction of bone density, short stature, and, in some patients, blue sclera. Tooth development and hearing are normal. Classification of OI were revisited and expanded by some authors [6,7].

At present, a total of many genetic mutations due to OI have been reported. Type II was then subdivided in II-A, II-B, II-C. Type V and VI remain part of the revised classification [8], implying the addition of OI types (V–XV). Three recessive OI types arise from defects of the collagen prolyl 3-hydroxylation complex (CRTAP, P3H1, CyPB), which modifies the collagen $\alpha 1(I)$ Pro986 residue. Complex dysfunction leads to delay folding of the procollagen triple helix and increase helical modification. Defects in collagen chaperones, HSP47 and FKBP65, lead to improve procollagen folding and to deficient collagen cross-linking in matrix, respectively. OI diseases result from mutations of the genes that encode the chains of type I collagen (COL1A1 or COL1A2) [9].

Dentinogenesis imperfecta : The most usual classification system for dentinogenesis imperfecta (DI) was formulated by Shields et al. in 1973, recognizing three types of DI (types I, II, and III). DI is a hereditary disorder in dentin formation that comprises a group of autosomal dominant genetic conditions, characterized by abnormal dentine structure affecting either the primary or both the primary and secondary dentitions. Radiographically, teeth show short roots, bulbous crown with marked cervical constriction, and pulpal obliterations. The primary teeth are more severely affected than the permanent. DI type 1 is associated with OI. The teeth of both dentitions are typically amber and translucent and show significant attrition.

In addition to mutations of the coding genes for type I collagen, the genes coding for dentin sialophosphoprotein (DSPP) may also produce dentin alterations. Three fragments of the initial DSPP molecule constitute the DSP (dentin sialoprotein), DGP (dentin glycoprotein) and DPP (dentin phosphoprotein) matrix proteins. They result from the cleavage by astracin and metalloproteases (MMP-2, MMP-9). Each of the three molecules may be mutated. DGP and DPP are encoded by the end of exon 5 of the DSPP coding gene. DPP initiates hydroxyapatite formation at low concentration and inhibits growth at higher concentration.

Clinical features of OI

Homozygous oim mice are born with fractures or develop them at an early age. The generalized radiolucency, cortical thinning, bowing of the long bones, fractures, and calluses, as evidence of healed fractures, are radiological hallmarks of human OI.

Type I: It is an autosomal dominant inheritance with blue sclera. Normal stature, with little or no deformity, early deafness and hearing loss in 50%; dentinogenesis imperfecta is rare and may distinguish a subset. Mild, non-deforming. I-A normal teeth, I-B and I-C, are the most frequent type of OI. Type IB is characterized by the absence/presence of dentinogenesis imperfecta. There is sometime a slight protrusion of the eyes.

Type II: Is lethal in the perinatal period, associated with minimal calvarial mineralization, beaded ribs, compressed femurs, marked long bone deformity, and platyspondyly. In II-A, wide (thin) ribs with fractures are frequent. Lethal perinatally, Type II OI is later divided into three subtypes (A, B, and C OI type II). OI type IIA is caused by mutations of the *COL1A1* and *COL1A2* genes (17q21.31-q22 and 7q22.1 respectively).

Type III: It is a severe type of OI and cause progressively deforming bones, usually with moderate deformity at birth. Sclerae have variable colors, often lighten with age. Dentinogenesis imperfecta is common, with hearing loss. The stature is short. Progressively deforming, there is an increased bone fragility, leading to bone fracture. Incidence : OI Type III affects about 1 in 15000 newborns.

Type IV: Displays normal sclerae, mild to moderate bone deformity and variable short stature. Dentinogenesis imperfecta is common (opalescent teeth), and hearing loss occurs in some cases. Type IV has moderately deforming bones [9,10]. Type IV-A displays normal teeth ; in contrast with type IV-B that engender a pathologic type I dentinogenesis Imperfecta. The mutations give rise to severe bone fragility in humans.

SPARC-null mice developed a progressive osteoporosis. Recessive mutations in SPARC are a cause of severe OI [11]. *COL1A1*, *COL1A2*, *CRTAP* and *LEPRE1* are the genes implicated in these forms of OI. Based on the common classification, OI patients can be categorized into mild (type I), perinatal lethal (type II), progressively deforming (type III), and moderately severe (type IV). Additional types have been added with distinct features. They are listed below (Table 1).

The various types occur in approximately 1/15,000– 20,000 births. Most OI cases have autosomal dominant inheritance. Over 1500 dominant mutations were found : either with *COL1A1* or

COL1A2 genes, encoding the α -chains [α 1(I) and α 2(I)] of type I collagen, or they have been identified closely associated with other genes mutations [12-14].

Types VII-IX affect collagen folding and chaperone functions. They result from mutations in *SERPINH1* and *FKBP10*. Collagen-associated proteins are implicated in collagen modification in OI : either mineralization, or folding, crosslinking, and chaperoning (Figure 1).

DENTINOGENESIS IMPERFECTA

Molecular genetics studies allow to discriminate only two major pathologies: dentinogenesis imperfecta (formerly DGI Shield type II, III and DD Shield type II) and dentin dysplasia (formerly DD Shield type I) corresponding to a radicular anomaly. DI is characterized by discoloration of the dentition, severe attrition of the teeth, bulbous crowns and early obliteration of the pulp in both deciduous and permanent dentitions. Pulp obliteration occurs soon after eruption or prior to tooth eruption. Primary dentition is more severely affected than the permanent dentition.

DI type 3 is characteristic of a tri-racial population from Maryland and Washington, DC, known as the Brandywine isolate. The clinical features are variable and resemble those seen in DI types 1 and 2, but the primary teeth show multiple pulp exposures and, radiographically, they often manifest as a 'shell' teeth, i.e., teeth that appear hollowed due to hypotrophy of the dentine [15].

Histologically, the dentin is similarly affected in the three types of DI. A layer of normal mantle dentin with an irregular texture of dentinal matrix and an abnormal number and structure of dentine tubules has been reported. Consistently, there are atubular areas of dentine.

The strong association between OI and DI had induced different authors to propose another classification by making diagnosis of OI, depending on the presence of DI. DI has been classified into two major groups : dentin dysplasia (DD) type I and II, and dentinogenesis imperfecta (DGI) type I-III). It is obvious that mutations of DSPP produce DGI types II and DD-II [16].

The dental features of DI type 2 are similar to those of DI type 1 but without association of OI. The diseases (dentin dysplasia types I and II and dentinogenesis imperfecta DGI-types I to III) have been classified into two major groups with subtypes:

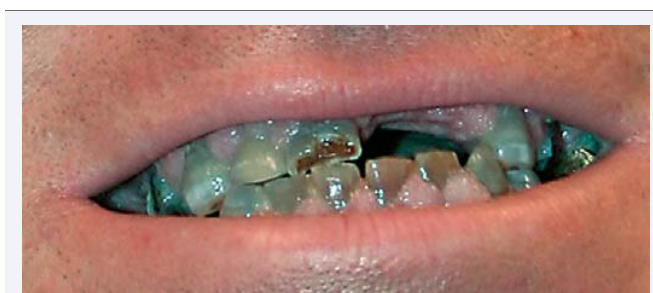

Figure 1 Dentinogenesis imperfecta (DI) in a patient with OI Type III [11].

Table 1 : Other genes mutations generating clinical manifestations [10].
BRIL and PED defects generate Types V and VI via defective bone mineralization, Moderate to severe OI and normal sclera. Mutation of the IFITM5 gene.
Type VI is an autosomal recessive form of the disease caused by a mutation in the gene SERPINF in chromosome 17p13.3.
Type VII seems to result from a mutation in CRTAP gene located in chromosome 3p22.
Type VIII display a white sclera, growth impairment, poor skeletal mineralization. This form is the result of a mutation in the PPIB gene in chromosome 1p34.2.
Type X and XI results from HSP 47 and FKBP65 defects, via aberrant collagen crosslinking, folding and chaperoning.
Type XI is caused by a mutation in the FKBP10 gene in the chromosome 17q21.
Type XII is caused by mutation in the SP7, WNT1, TRIC-B and OASIS gene in chromosome 12q13.13. Clinically it is characterized by recurrent fractures, mild bone difformities, generalized osteoporosis, delayed eruption of teeth, absence of dentinogenesis imperfecta, normal hearing and white sclera. Absence of type I collagen C-propeptidase BMP1 cause type XII OI [14].
Type XIII implicate a mutation of the gene of the bone morphogenetic protein 1 (BMP1) located in chromosome 8p21.
Type XIV with prenatal fracture or occurring at 6 years of age is due to mutations in the gene TMEM 388 in chromosome 9q31.
Type XV seems to be caused by a mutation in WNT1 [7].
Type XVI : OI is caused by mutation in the CREB3L 1 gene. It cause recurrent fractures of the rib and long bones, a decreased ossification of the skull, and blue sclera.
Type XVII : Mutation of the SPARC gene on chromosome 5q33.

- 1- dentin dysplasia (DD) types I and II,
- 2- dentinogenesis imperfecta (DGI) types I–III (MacDougall 2006).

Genetic linkage studies have identified the critical loci for DD-II, DGI-II, and DGI-III to human chromosome 4q21. Located within the common disease loci for these diseases there is a cluster of dentin/bone genes that includes a series of Small Integrin-binding Ligand N-linked Glycoproteins (SIBLINGS), a family of genes coding osteopontin (OPN), bone sialoprotein (BSP), matrix extracellular phosphoglycoprotein (MEPE), dentin matrix protein 1 (DMP1), and dentin sialophosphoprotein (DSPP). It is obvious that only mutations of DSPP are associated with the pathogenesis of dentin diseases [16] (Table 2 and Figure 2).

Dentinogenesis imperfecta (DI Type I) is found more commonly in OI type III. DI type I is associated with mutations of the genes encoding type I collagen [19].

Dentin dysplasia with coronary defects

All the three mutated molecules produced by DSPP cleavage are members of the SIBLINGS family, and implicated in tooth mineralization. Teeth are gray-blue or amber brown and display opalescent discoloration. Bullous crown, because of cervical constriction, and partial obliteration of the pulp chamber are recognized in this phenotype. The teeth showed few and large dentinal tubules and atubular areas. Enamel chipping is also observed.

Dentin dysplasia (type II and III) with radicular defects

This type affects only deciduous teeth. The pulp exhibits a thistle-tube aspect (a large pulpal chamber, followed by thin root canals). Pulpstone are frequent.

TREATMENT OF OSTEOGENESIS IMPERFECTA

Pharmacologic treatment

(Bisphosphonates, synthetic analogues of pyrophosphate inhibit bone resorption). Deposited on the bone surface, they are ingested by osteoclasts, inducing apoptosis of the cells. Decreased osteoclastic activity is indicative by a reduction in serum levels of calcium, phosphate and alkaline phosphatase [20-22]. Alendronate demonstrated a reduction in the number of fractures and an increase in bone mineral density. Numerous cases of osteonecrosis of the jaw (namely in the mandibular and maxillary alveolar bone) have been reported due to a bisphosphonate treatment.

A family of drugs: Pamidronate, intravenous disodium pamidronate, zoledronic acid. Growth hormone (drugs inhibiting bone resorption by inducing osteoclast apoptosis) have been used successfully. Denosumab has a shorter period of treatment than bisphosphonate. Oral olpadronate, bisphosphonate, zoledronic acid are also indicated to treat or reduce the effects of OI [24].

For OI type 5 where calcification in interosseous membranes have been observed, the treatment prompt to use of indomethacin, an anti-inflammatory COX-1 and COX-2 prostaglandin inhibitor has been recommended to avert progress. Oral risedronate (Actonel[®]) seems also to cure OI and provide therapeutic beneficial effects.

Cell and Gene therapies

The aim of this approach is to supply terminally differentiated osteoblasts, the bone forming cells. Osteoblasts arise from mesenchymal stem cells that reside in the bone marrow whereas the osteoclasts, the cells that are involved in bone resorption, are derived from hemopoietic lineage. The ability for bone to regenerate is attributed to quiescent stem cells in bone that undergo proliferation and differentiation.

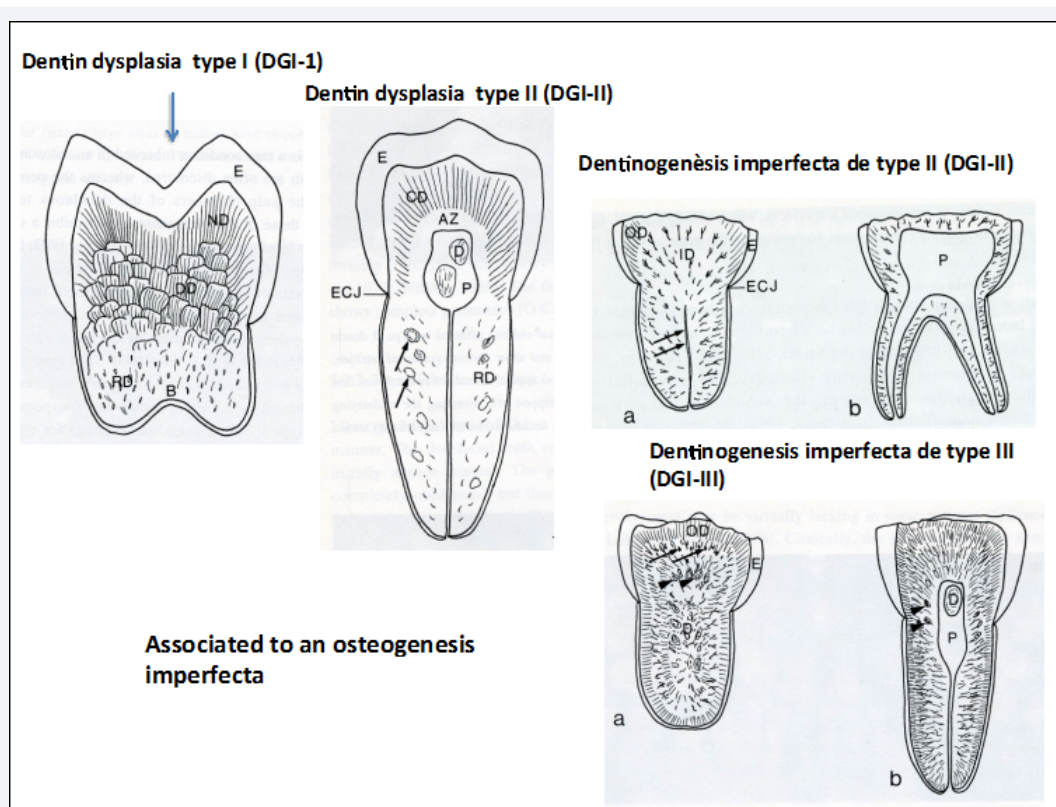


Figure 2 Dentin dysplasia alterations are found either in the root, or in the crown. Reprint from: Waltimo [17,18].

Table 2: Classification of Dentinogenesis Imperfecta [16].

Dentin Dysplasia type I (DD-I) known as rootless teeth. The crown looks normal but the root is short, conical or absent. There is a crescent-shaped pulp remnant. Abnormal dentin is seen with large pulp stones and atypical osteodentin.

Dentin Dysplasia Type II (DD-II). The dentin of deciduous teeth is opalescent grayish or brownish discoloration. Radiographic examination displays pulp obliteration. The permanent teeth show a thistle-tube pulp chamber with pulp stones. The roots seem normal in both dentitions. Dentin is disorganized with few dentinal tubules.

Dentinogenesis Imperfecta (DGI) has three subgroups Type I, II and III.

Type I is associated with OI. The mutation causes modifications of type I collagen chains. Dicolorations are seen in deciduous and permanent dentitions. The roots are constricted with progressive pulpal obliteration.

Type II, also called opalescent dentin is estimated as 1:6,000 and 1:8,000 newborns. Teeth are discolored, appearing yellow, amber, brown, or bluish gray, and translucent. Various degrees of attrition are observed. Pulp chambers and root canals are usually obliterated. The mantle dentin is normal, but the number of tubules is decreased in circum-pulpal dentin.

Type III affects the « Brandywine isolate », the subpopulation located initially in southern Maryland. This population is estimated at 1:15 newborns. The teeth are referred to as « shell teeth », the mantle dentin is normal, but the pulps appear enlarged with a high incidence of pulp exposures.

Since the transplanted cells are stem cells, they will self-renew and thus it is expected that they provide treatment for life. Normal transplanted cells may also possess survival advantage over the endogenous cells because they synthesize normal matrix.

Gene therapy using a mutation-independent approach by targeting polymorphic sites within procollagen genes may be used in conjunction with collagen genes supplementation.

In addition, it may be possible to overexpress the normal collagen gene in cells of the OI patients, reaching an equilibrium toward the formation of normal collagen molecules.

The potential of collagen gene replacement as an approach for OI treatment was further evaluated by determining the ability

of the bone marrow stromal cells to be transduced with collagen genes and to express the genes with high efficiency *in vitro* and *in vivo*.

As a proof of concept, an adenoviral vector carrying the murine procollagen $\alpha 2(I)$, cDNA was constructed and used to transduce osteoprogenitor cells harvested from oim mice that are deficient in the pro $\alpha 2(I)$, collagen synthesis.

A combination of gene silencing and gene replacement approaches in stem cells will need to be developed for the treatment of OI patients with dominant-negative mutations. In addition, a clear understanding of the nature of the stem cells for gene delivery to the skeleton is mandatory, and also the engraftment characteristics of the cells. This implies to take

advantages of methods of cell delivery and methods aiming to increase efficiency of the mesenchymal stem cell engraftment. This approach need to be developed for the successful gene therapy and OI treatment [24].

CONCLUSIONS

All these therapeutic approaches may be efficient if in addition to dental treatment (bleaching, porcelain laminated veneers, composite resins), performed under general analgesia, and mental health support. Cardiopulmonary complications should be taken into account because they are the major cause of morbidity. The treatment implies also recommended surveillance, musculo-skeletal, neurologic, dental and audiological treatment [25,26].

REFERENCES

- Sillence DO, Senn A, Danks DM. Genetic heterogeneity in osteogenesis imperfecta. *J Med Genet.* 1979; 16: 101-116.
- Witkop Jr CJ. Hereditary defects of dentin. *Dental Clinics North America.* 1975; 19: 25-45.
- Van Dijk FS, Sillence DO. Osteogenesis Imperfecta : clinical diagnosis, nomenclature and severity assessment. *Am J Medical Genetics Part A.* 2014 ; 164A : 1470-1481.
- Keupp K, Beleggia F, Kayserili H, Barnes AM, Steiner M, Semler O, et al. Mutations in WNT1 cause different forms of bone fragility. *Am J Human Genet.* 2013 ; 92: 565- 574.
- Pyott SM, Tran TT, Leistriz DF, Pepin MG, Mendelsohn NJ, Temme RT, et al. WNT1 mutations in families affected by moderately severe and progressive recessive osteogenesis imperfecta. *Am J Hum Genet.* 2013 ; 92: 590-597.
- Van Dijk FS, Pais G, Van Rijn RR, Nikkels PGJ, Cobben JM. Classification of osteogenesis Imperfecta revisited. *Eur J Medical Genet.* 2010; 53: 1-5.
- Valadares ER, Carneiro TB, Santos PM, Oliveira AC, Zabel B. What is new in genetics and osteogenesis imperfecta classification? *Jornal de Pediatria.* 2014; 90: 536-541.
- Rauch F, Glorieux FH. Osteogenesis imperfecta. *Lancet.* 2004; 363: 1377-1385.
- Byers PH, Steiner RD. Osteogenesis Imperfecta. *Annu Rev Med.* 1992; 43: 269-282.
- Marini J, Bissett AR. New genes in bone development : What's new in odontogenesis imperfecta. *J Clin Endocrinol Metab.* 2013; 98: 3095-3103.
- Van Dijk FS, Cobben JM, Kariminejad A, Maugeri A, Nikkels PGJ, van Rijn RR, Pals G. Osteogenesis Imperfecta: a review with clinical examples. *Mol Syndromology.* 2011 ; 2: 1-20.
- Forlino A, Cabral WA, Barnes A, Marini JC. New perspectives in odontogenesis Imperfecta. *Nat Rev Endocrinol.* 2012; 7: 540-557.
- Shields ED, Bixler D, El-Kafrawy AM. A proposed classification for heritable human dentin defects with a description of a new entity. *Arch Oral Biol.* 1973; 18: 543-553.
- Marini JC, Reich A, Smith SM. Osteogenesis Imperfecta due to mutations in non-collagenous genes-lessons in the biology of bone formation. *Curr Opin Pediatr.* 2014; 26: 500-507.
- Majorandra A, Bardellini E, Brunelli PC, Lacaíta M, Cazzolla AP, Favia G . Dentinogenesis imperfecta in children with osteogenesis imperfecta: a clinical and ultrastructural study. *Int J Paediatr Dent.* 2010; 20: 112-118.
- MacDougall M, Dong J, Acevedo AC. Molecular Basis of human dentin diseases. *Am J Med Genet. Part A.* 2006; 140A: 2536-2546.
- Waltimo J, Ranta H, Lukinmaa PL. Transmission electron microscopic appearance of dentin on type II dentin dysplasia. *Scand J Dent Res.* 1991; 99: 349-356.
- Waltimo J. Developmental defects of human dentin matrix- an ultrastructural study. *Academic Dissertationn University of Helsinki.* 1996.
- De La Dure-Molla, M., Philippe Fournier, B., Berdal, A. Isolated dentinogenesis imperfecta and dentin dysplasia: revision of the classification. *Eur J Hum Genet.* 2015; 23: 445-451.
- Sahni M, Guenther HL, Fleisch H, Collin P, Martin TJ. Bisphosphonates act on rat bone resorption through the mediation of osteoblasts. *J Clin Invest.* 1993; 91: 2004-2011.
- Fleisch H. Bisphosphonates in osteoporosis. *Eur Spine J.* 2003; 12: S142-S146.
- Graham R, Russell G. Bisphosphonates: the first 40 years. *Bone.* 2011; 49: 2-19.
- Vuorimies I, Toiviainen-Salo S, Hero M, Mäkitie O. Zoledronic acid treatment in children with osteogenesis Imperfecta. *Horm Res Paediatr.* 2011; 75: 346-353.
- Niyibizi C, Wang S, Mi Z, Robbins PD. Gene therapy approaches for osteogenesis imperfect. *Gene therapy* 2004; 11: 408-416.
- Marini J, Smith SM. Osteogenesis Imperfecta. In Feingold KR, Anawalt B, Boyce A et al. (eds) *Endotext* 2015.
- Steiner RD, Basel D. COL1A1/2 Osteogenesis Imperfecta *Gene Reviews.* 2005; 1-29.

Cite this article

GOLDBERG M (2020) *The Influence of Gene Mutations on Bone and Teeth Mineralization: Osteogenesis and Dentinogenesis Imperfecta.* *JSM Dent* 8(3): 1131.