SciMedCentral Journal of Dermatology and Clinical Research

Case Report

Trichilemmal Carcinoma: A Diagnostic Challenge Case Report

Paola Caceres[1]*, Franklin Cabrera[2], Verónica Posso[3], Augusta Basantes[1], Camila Felix[1], Andrea Cueva[1], Lesly López[1], Janyna Jaramillo[1] and Yoselin Chamorro[1]

[1]Dermatology Resident, Universidad Tecnológica Equinoccial. Quito, Ecuador

[2]Department of Dermatology, Hospital Carlos Andrade Marín, Universidad Central del Ecuador, Quito, Ecuador

[3]Department of Dermatopathology, Hospital Carlos Andrade Marín, Universidad UTE, Quito, Ecuador

*Corresponding author

Paola Caceres, Hospital Carlos Andrade Marín, Universidad UTE, 18 de Septiembre, Quito, Ecuador, Tel: + 593 99 565 3803; ORCID: 0009-0000-7047-0962

Submitted: 22 April 2024

Accepted: 10 May 2024

Published: 16 May 2024

ISSN: 2373-9371

Copyright

© 2024 Caceres P, et al.

OPEN ACCESS

Keywords

- Trichilemmal carcinoma
- Adnexal tumor

Abstract

Trichilemmal carcinoma is a rare cutaneous tumor, representing only 1% of all adnexal carcinomas. It derives from the outer root sheath of the hair follicle. Clinically, it manifests as a skin-colored or slightly pink papule in sun-exposed areas in elderly patients. The following is a case report detailing trichilemmal carcinoma arising from a previous lesion and its correlation with histopathology.

ABBREVIATIONS

ORS: Outer Root Sheath; UV: Ultraviolet; TC: Trichilemmal Carcinoma

INTRODUCTION

Trichilemmal carcinomas are uncommon adnexal neoplasms that are malignant and separate from the hair follicle's Outer Root Sheath (ORS) [1]. Its incidence rate is unknown; however it is an extremely uncommon tumor [2].

The most common place for these tumors is the face, although they also commonly occur in older people on sun-exposed parts of the head and neck. There is a slight male predominance with a mean diagnostic age of 70 years [1]. Another characteristic of TC is its slow clinical progression. Generally speaking, TC is treatable with surgery, such as a broad surgical excision. While specific clinical features of TC are often overlooked, medical attention becomes necessary when an abrupt development phase ensues during the later stages of the disease's course [3]. It can replicate as keratoacanthoma, malignant pylomatricoma or trichoblastic carcinoma, basal or squamous cell carcinoma, or a pilar tumor that is growing [4]. Known risk factors include immunosuppression, a history of burns or other local trauma, Ultraviolet (UV) and ionizing radiation, and hereditary diseases such as Cowden disease and xeroderma pigmentosa [1]. The absence of a granular layer between the stratum spinosum and stratum corneum in a tumor exhibiting trichilemmal keratinization is the primary histological characteristic that distinguishes a TC from other types of tumors [5].

CASE PRESENTATION

We report a 53-year-old female patient who 20 years ago came with a skin lesion consistent with lipoma; the lesion appeared to disappear following surgical excision and the ruling out of cancer. The tumor recurred years later in the same anatomical position, this time with a nodular lesion and an erythematous-violaceous patch on its surface. Wide surgical excision was performed, and histology reported a hair-follicle derived tumor that was growing and had distinct surgical margins. Seven years later, a localized cutaneous disease characterized by a 6 cm erythematous-violaceous, indurated, deeply adherent neoformation appeared in the patient's left subscapular region (Figure 1). Histologically, the diagnosis of trichilemmal carcinoma was supported by several infiltrative lobules containing squamous cells and a few anucleate basaloid cells producing keratin masses without a granular layer (Figure 2). Following this, a "reading-man" flap

Figure 1 Clinical images of neoformation with an erythematous-violaceous patch on its surface.

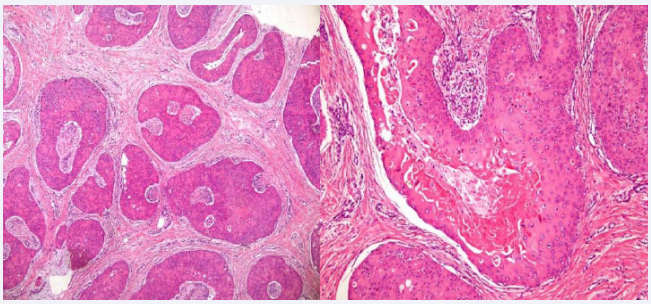

Figure 2 Trichilemmal keratinization.

technique was used to close the large surgical excision in two stages, with periodic imaging controls in between.

DISCUSSION

Headington originally defined trichilemmal carcinoma as "a clear cell neoplasm of adnexal keratinocytes that is in continuous with the epidermis and/or follicular epithelium and is histologically invasive and cytologically atypical" in 1976 [6]. Trichilemmal carcinoma's pathophysiology is still unknown, although known risk factors include UV radiation, solid organ transplantation, immunosuppression, ionizing radiation, burns, prior trauma or scarring, and genetic disorders (xeroderma pigmentosum and Cowden disease). Anecdotal evidence suggests that p53 suppresses the immune system during the malignant transformation of trichilemmal carcinomas [7].

The clinical presentation varies and lacks specificity. Grossly papular, nodular, or exophytic appearances are all possible in trichilemmal carcinomas. It may imitate keratoacanthoma, malignant pilomatricoma or trichoblastic carcinoma, basal or squamous cell carcinoma, or a growing pilar tumor [8].

The tumor displays dermal invasion and trichilemmal keratinization with an abrupt or pagetoid interface. Trichilemmal carcinoma cells exhibit high mitotic indices and unusual nuclei, in contrast to trichilemmomas [9].

In our case, the patient presented with multiple risk factors, notably fair skin type, prolonged exposure to UV radiation, and a clinical lesion located over a prior scar with a history of proliferating trichilemmal tumor [8]. Histologically, the presence of non-invasive margins is pivotal in assessing the potential for a locally aggressive pattern and the risk of local recurrence [10].

CONCLUSIONS

Trichilemmal carcinoma is a rare neoplasm that seldom metastasizes. Its differential diagnosis includes squamous cell carcinoma, keratoacanthoma, and amelanotic melanoma. Recurrence is uncommon, but patients should undergo regular surveillance examinations to detect any sequelae.

REFERENCES

1. Fronek L, Brahs A, Farsi M, Miller R. A rare case of trichilemmal carcinoma: Histology and management. J Clin Aesthet Dermatol. 2021; 14: 25-30.
2. Ha JH, Lee C, Lee KS, Pak CS, Sun CH, Koh Y, et al. The molecular pathogenesis of trichilemmal carcinoma. BMC Cancer. 2020; 20: 516.
3. Zhuang SM, Zhang GH, Chen WK, Chen SW, Wang LP, Li H, et al. Survival study and clinicopathological evaluation of trichilemmal carcinoma. Mol Clin Oncol. 2013; 1: 499-502.
4. Usseglio J, Pagès E, Guyot A, Laloze J, Ferri J. Trichilemmal carcinoma of the scalp. Int J Oral Maxillofac Surg. 2021; 50: 1289-1292.
5. Chai MK, Tenzel P, Iacob C, Jordan A, Reddy HS. Eyelid trichilemmal carcinoma. Saudi J Ophthalmol. 2017; 3:183-185.
6. Ha JH, Lee C, Lee KS, Pak CS, Sun CH, Koh Y, et al. The molecular pathogenesis of Trichilemmal carcinoma. BMC Cancer. 2020; 20: 516.
7. Maya-Rico AM, Jaramillo-Pulgarín C, Londoño-García Á, Peña-Zúñiga B. Locally aggressive trichilemmal carcinoma. An Bras Dermatol. 2018; 93: 579-581.
8. Rhoul C, Miry A, Bennani A, Serji B, El Harroudi T. A rare case report of trichilemmal carcinoma. Cureus. 2022; 14: e31261.
9. Romeu M, Foletti JM, Chossegros C, Dales JP, Berbis P, Cribier B, et al. Les tumeurscutanées malignes à différentiation pilaire de la face et du cuir chevelu : mise au point diagnostique et thérapeutique. Journal of stomatology, oral and maxillofacial surgery. 2017; 118: 95–102.
10. Hamman MS, Brian Jiang SI. Management of trichilemmal carcinoma: An update and comprehensive review of the literature. Dermatol Surg. 2014; 40: 711-717.