

Case Report

Primary Hydatid Cyst of the Sphenoid Sinus: Case Report

Sharfi Ahmed*

Faculty of Medicine, Omdurman Islamic University, Sudan

*Corresponding author

Faculty of Medicine and Health Sciences
Omdurman Islamic University, Sudan, Tel: 249912347884,
Email: doctorsharfi@gmail.com

Submitted: 19 November 2016

Accepted: 10 January 2017

Published: 12 January 2017

Copyright

© 2017 Sharfi Ahmed

OPEN ACCESS

Abstract

Hydatid disease (also known as hydatidosis) is a cyclozoonotic infection caused by the cestode genus *Echinococcus*. The incidence of humans infected with hydatid disease is approximately 1.0-2.0:1,000, although it may be higher in rural areas of regions that are affected. Infection occurs via ingestion of infected meat. A hydatid cyst of the head and neck is a very rare condition, even in areas where *Echinococcus* infestation is endemic. Primary infection of the Lt sphenoid sinus is odd and very rare.

Case Report: We report a rare case of primary hydatid cyst of the Lt sphenoid sinus in a 65-year-old Sudanese Female. The initial diagnosis of the presence of a cystic mass was the result of physical examination, computed tomography (CT) scan, MRI (magnetic resonance imaging) and Histopathology. We diagnose the cystic mass by biopsy using FESS (Functional Endoscopic Sinus Surgery). A definitive diagnosis was confirmed by postoperative histopathologic examination.

Conclusion: Hydatid cyst of the sphenoid sinus is a highly rare presentation. However, this condition should be considered in differential diagnosis of cystic lesions of the sinuses. This article reviews a case report involving this rare condition.

Keywords

- Cystic lesion
- Echinococcus
- Hydatid cyst
- Sphenoid sinus

INTRODUCTION

Hydatid disease (also known as hydatidosis) is usually caused by the cestode *Echinococcus granulosus* (*E. granulosus*), of which humans are an intermediate host [1,2]. The main host and source of infection for humans is the dog. The infection is transferred to humans from unwashed hands after having touched a dog that has swallowed tapeworm eggs, from drinking water contaminated with dog faeces, or by consuming fresh fruit and vegetables washed or irrigated with contaminated water [3].

Hydatid disease occurs throughout the world and is especially common in sheep- and cattle-raising regions of Africa, Australia, New Zealand, India, the Middle East, South America, and the Mediterranean. The incidence of humans infected with hydatid disease is approximately 1-2:1,000, although it may be higher in rural areas of regions that are affected [4]. It mainly affects the pulmonary and digestive systems. The liver is the most frequently involved organ (75%), followed by the lung (15%) and the rest of the body (10%) [5].

The occurrence of hydatid cysts in the head and neck is rare, even in countries where *Echinococcus* infestation is endemic [6]. Furthermore, hydatid cyst of the nose and paranasal sinuses region has rarely been reported in the literature [2,4]. Herein, we report a rare case of a hydatid cyst located in the left sphenoid sinus and extended intraorbital causing vision problem. A broad review of the literature identified few cases of hydatid cyst of the sinuses [2,4,7-11].

CASE REPORT

A 65-year-old Sudanese female with a painless swollen left eyelid, blindness and headache was referred to our department (Figure 1). The swelling had progressed gradually over the course of at least 5 months and the patient had shown no improvement despite antibiotic treatment. The patient had clear rhinorrhea and a history of close contact with sheep. Physical examination revealed a left blind eye. There was no tenderness in the affected area. Nasoendoscopy revealed anterior bulging of the anterior wall of the sphenoid sinus, otherwise the general condition of the patient was normal. Computed tomography imaging (CT) of the sinus showed a soft tissue density in the left sphenoid sinus with erosion of the lateral and anterior walls, as well as the orbit and engulfing the optic nerve and the MRI (magnetic resonance imaging) showed:-There is a lobulated mass [42 x 4.0 cm] epicentered at the left sphenoid wing and blending with left cavernous sinus invading it & encasing the left ICA, which showed Luminal narrowing. The lesion showed destruction of the sphenoid bone with extension into the left temporal extra-axial space, impinging moderately into the left temporal lobe with mild perifocal white matter oedema. The lesion has also extended into the sphenoid sinus & orbital roof. Extension along cribriform plate on the midline. The lesion showed low T1, iso/high T2 signals & Ovid contrast enhancement (Figure 2-6).

The soft tissue density involved the left orbit and compressed the globe causing eye displacement (Figure 1).



Figure 1 Protrusion and swollen of the left eyelid and displacement.

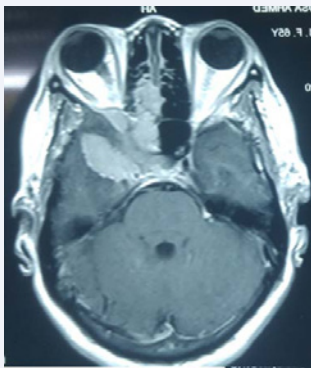


Figure 2 MRI /T2 Axial view showed a mass invading the optic nerve and extension into the left temporal and sphenoid-ethmoid area.

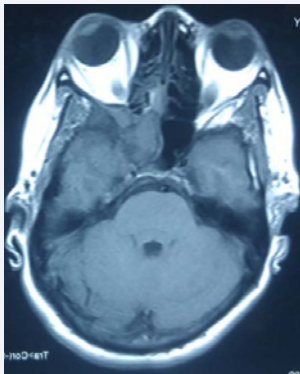


Figure 3 Axial view showed a mass invading the optic nerve and extension into the left temporal and sphenoid-ethmoid area.

The appearance of the suspected mass by MRI and CT was suggestive of Skull base cystic mass on the left side at the sphenoid wing with extension to the cavernous sinus, orbital roof & sphenoid sinuses as well as early impingement to the temporal lobe.

An abdominal ultrasound and CT scan of the abdomen and thorax ruled out visceral or pulmonary involvement in the hydatid disease, which confirmed the diagnosis of a primary hydatid cyst of the left sphenoid sinus.

FESS was done to the patient under general anaesthesia Cyst identified as a pulsatile vascular lesion a biopsy was taken from the cyst wall histopathology and it confirmed the diagnosis

(Microscopic description:- section show membranous strip of columnar cells around ovoid structures. There is no remarkable inflammation or tumour tissue. No prominent blood vessels to explain the pulsatile nature, are seen. The histological features are suggestive of parasitic infection possibly hydatid.). The patient was in a healthy condition after the operation. A 2-month course of albendazole (800 mg/d) with a 2-week interval after the first month was prescribed to the patient for prophylaxis

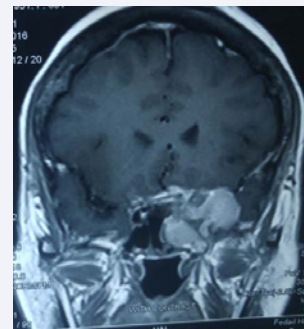


Figure 4 MRI /T2 Coronal view- destructive mass involving left sphenoid sinus and wing with extension to the cavernous sinus, orbital roof as well as early impingement to the temporal lobe.

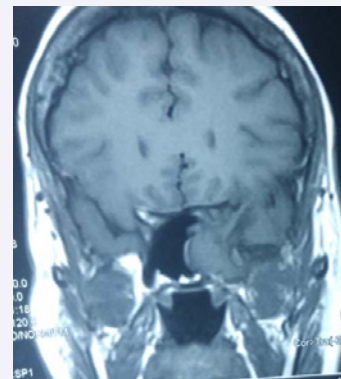


Figure 5 Coronal view- destructive mass involving left sphenoid sinus and wing with extension to the cavernous sinus, orbital roof as well as early impingement to the temporal lobe.

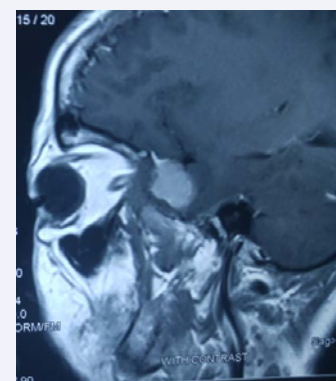


Figure 6 MRI T2 This is a sagittal view-show a mass as cystic lesion behind the orbit filling the sphenoid sinus and extended intracranial.

against recurrence. Then the patient disappear during the follow-up period.

DISCUSSION

Primary hydatid cysts of the Nasosinuses region are relatively rare. Of the reported cases in the current literature review, only a few have involved the maxillary sinus [2,4,7-11]. The first report of a probable hydatid cyst in the maxillary sinus was by BohiguesSapena in 1969 [7]. Since then only six other cases have been reported in the literature [2,4,8-11]. Including the present case, there have been just nine cases of maxillary sinus hydatidosis reported.

Most hydatid cysts in the head and neck are asymptomatic, with symptoms depending on the location and size of the cyst. Lesions are characteristically slow growing [6,12]. A complete history of the patient's occupation, residence, and exposure to specific animals or materials play a key role in clinical suspicion.

Plain radiography, ultrasound, CT, and magnetic resonance imaging (MRI) are the most useful diagnostic tools for detection of hydatid cystic lesions [2]. CT and MRI in particular are highly sensitive for the diagnosis of hydatidosis and provide a complete lesion work-up [2,13]. Serologic tests such as direct hemagglutination, latex agglutination, and immunoelectrophoresis are widely used to confirm the diagnosis; however, they have low sensitivity and specificity [6,14].

Surgery or FESS is generally the treatment of choice for hydatid disease unless resection is not possible (for example in cases of multiple organ involvement, inaccessible location, or poor general health) [6,15]. During the operation, the cyst should be removed with the germinative layer, carefully avoiding the spillage of the cystic contents.

Combination of endoscopic surgical therapy with imidazole derivatives has been used for the prevention of recurrences [2,6]. Although there were no signs of abdominal or pulmonary involvement in the present case, we prescribed a 2-month course of albendazole (800 mg/d) to the patient. In addition to prophylaxis against recurrence, medical therapy may also be a substitute for surgery when surgery is not possible [6]. Percutaneous treatment of the hydatid cyst has also been suggested as another alternative to surgery, but may not be preferred in the treatment of sinuses hydatid cyst if there is intervening bone [6,16].

CONCLUSION

Although sphenoid sinus is a highly rare location for a hydatid cyst, this possibility should be considered in the differential diagnosis. Imaging techniques are highly beneficial in the primary diagnosis; however, the definitive diagnosis is usually made by postoperative histopathologic examinations. FNA carries the risk of anaphylactic reactions and it should be avoided when the

diagnosis of hydatid cyst is considered.

ETHICAL CLEARANCE

I explained verbally to the patient the aim of the study, data collection, the need of investigations and regular follow up. Privacy of patient represents top priority to us.

REFERENCES

1. Sielaff TD, Curley SA. Liver. In: Brunnicardi FC, Andersen DK, Billiar TR, et al. editors. Schwartz's Principles of Surgery. 8th ed. New York: McGraw-Hill. 2005; 1163-1164.
2. Ataoglu H, Uckan S, Oz G, Altinörs N. Maxillofacial hydatid cyst. J Oral Maxillofac Surg. 2002; 60: 454-456.
3. Glunčić I, Roje Z, Bradarić N, Petricević A, Pisac VP, Glunčić V. Primary echinococcosis of the sternocleidomastoid muscle. Croat Med J. 2001; 42: 196-198.
4. Mortazavi SH, Motamedi MH. Primary hydatid cyst of the maxillary sinus: case report. Gen Dent. 2008; 56: 444-446.
5. Orhan Z, Kara H, Tuzuner T, Sencan I, Alper M. Primary subcutaneous cyst hydatid disease in proximal thigh: an unusual localisation: a case report. BMC MusculoskeletDisord. 2003; 4: 25.
6. Katılmış H, Oztürkcan S, Ozdemir I, AdadanGüvenç I, Ozturan S. Primary hydatid cyst of the neck. Am J Otolaryngol. 2007; 28: 205-207.
7. BohiguesSapena J. Probable hydatid cyst in the maxillary sinus. ActaOtorinolaryngollber Am.1969; 20: 251-257.
8. Shuker S. Hydatid cyst in the maxillofacial region. J Oral Maxillofac Surg. 1982; 40: 171-174.
9. Goldsher M, Eliachar I, Joachims Z, Golz A. Primary hydatid cyst of the maxillary sinus. J Laryngol Otol. 1983; 97: 869-870.
10. Shuker S. Hydatid cyst in the maxillofacial region. J Oral Maxillofac Surg. 1994; 52: 1086-1089.
11. el Gbouri H, Seghrouchni H, Bouladaas M, Rzin A, Nassih M, Ihray H, et al. Iatrogenic cervicofacial hydatid cysts: Apropos of a case. Rev StomatolChirMaxillofac. 1997; 98: 26-30.
12. Akal M, Kara M. Primary hydatid cyst of the posterior cervical triangle. J Laryngol Otol. 2002; 116: 153-155.
13. Hafsa C, Ben Alaya T, Kriaa S, Jerbi S, Golli M, Hamdi MH, et al. Maxillofacial location of hydatid cyst. Ann OtolaryngolChirCervicofac. 2008; 125: 160-163.
14. Bouckaert MM, Raubenheimer EJ, Jacobs FJ. Maxillofacial hydatid cysts. Oral Surg Oral Med Oral Pathol Oral RadiolEndod. 2000; 89: 338-342.
15. Turgut S, Ensari S, Katirci H, Celikkanat S. Rare otolaryngologic presentation of hydatid cyst. Otolaryngol Head Neck Surg. 1997; 117: 418-421.
16. Akhan O, Ensari S, Özmen M. Percutaneous treatment of a parotid gland hydatid cyst: a possible alternative to surgery. EurRadiol. 2002; 12: 597-599.

Cite this article

Ahmed S (2017) Primary Hydatid Cyst of the Sphenoid Sinus: Case Report. J Ear Nose Throat Disord 2(1): 1016.