

Case Report

Subglottic Lobular Capillary Hemangioma: A Case Report

Vinh Ly Pham Hoang¹, Nguyen Pham Dinh¹, Hoang Nguyen^{2*}, Joseph P. Kitzmiller², Linh Bui Doan Hai¹, and Huy Nguyen The¹

¹Department of Otorhinolaryngology, Children Hospital I, Ho Chi Minh City, Vietnam

²The Ohio State University, College of Medicine, Department of Biological Chemistry and Pharmacology, Columbus, Ohio, USA

*Corresponding author

Hoang Nguyen, Department of Biological Chemistry and Pharmacology, The Ohio State University, College of Medicine, Columbus, Ohio, USA, Email: Hoang.Nguyen@osumc.edu

Submitted: 20 July 2017

Accepted: 08 August 2017

Published: 10 August 2017

ISSN: 2475-9473

Copyright

© 2017 Nguyen et al.

OPEN ACCESS

Abstract

Lobular capillary hemangioma (LCH) is a benign proliferation of capillary blood vessels adopting a lobular configuration. A laryngeal origin of LCH is exceedingly rare. Here, we describe a case of an 11-year-old boy presenting with a subglottic lesion, leading to a subglottic stenosis. Histopathologic findings of the lesion implicated an LCH, which was removed successfully by a coblator. This is the first report of a subglottic LCH. Physicians should be aware of this unique lesion and laryngeal LCH should be considered in diagnosing the cause of a subglottic stenosis. Additionally, coblation should be an effective treatment for laryngeal LCH.

Keywords

- Lobular capillary Hemangioma
- Subglottic
- Pyogenic granuloma
- Coblator

INTRODUCTION

Lobular capillary hemangioma (LCH), also known as pyogenic granuloma, is a benign proliferation of capillary blood vessels adopting a lobular configuration [1]. The term 'pyogenic granuloma' is a misnomer as the lesion does not contain purulent material and is not a granuloma. LCH is a smooth or lobulated red lesion on a sessile or pedunculated base that varies in size from a few millimeters and rarely exceeds 2.5 cm [2,3]. The usual sites for this tumor are the skin and the nasopharyngeal and oral mucosal surfaces [4]. LCH in the gastrointestinal tract has also been reported [5]. LCH lesions are very rare in the airway, with only a few cases reported to date [6-23] and subglottic LCH is unique. Here, we present the case of an 11-year-old boy who presented with a subglottic LCH, posing both a diagnostic and therapeutic challenge.

CASE REPORT

An 11-year-old Vietnamese boy presented to the Department of Otolaryngology, Children Hospital I, Ho Chi Minh City, Vietnam, with a complaint of dyspnea and dry coughing. He had been suffering from increasing dyspnea, coughing, and occasional wheezing for two weeks but had not been suffering from hoarseness or fever. He had no history of previous intubation, airway surgery, trauma, or tuberculosis.

Clinical examination of lung and heart revealed no abnormalities. Consequently, a neck and chest computed tomography (CT) with intravenous contrast was performed, which did not reveal any parenchymal lung disease. However, we observed a lesion on the left and posterior wall of the larynx, which probably caused a subglottic stenosis leading to dyspnea, wheezing, and coughing in this patient (Figure 1).

We further performed a laryngeal endoscopy and observed a pink soft and hyperemic lesion with smooth surface located just under the surface of the left vocal cord. Consistent with the CT scan findings, the lesion was located on the left wall of the subglottic site, leading to a grade III subglottic stenosis with a 75% obstruction (Figure 2). Based on the clinical symptoms and imaging findings, a diagnosis of hemangioma was established. The patient received a tracheostomy and intravenous propranolol

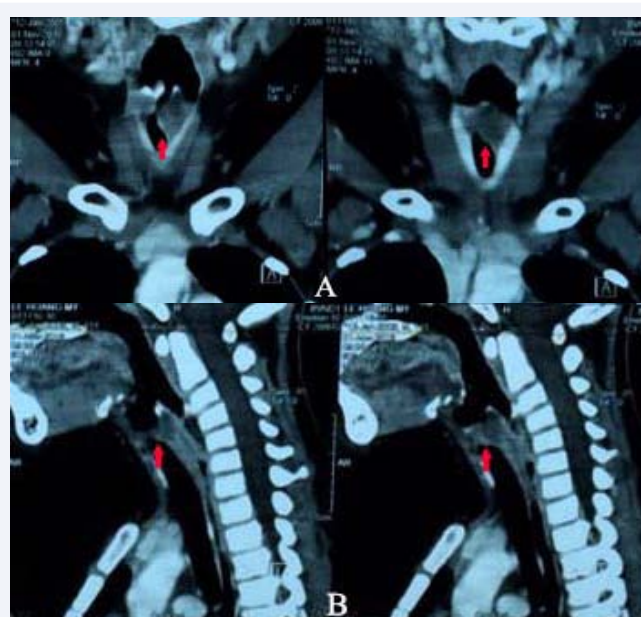


Figure 1 Neck CT scan revealed 2-cm diameter lesion on the left and posterior wall of the larynx (arrow). (A) Coronal image. (B) Sagittal image.

(1mg/kg/day) for 2 weeks.

To follow up, a second laryngeal endoscopy was done. Surprisingly, the lesion grew into a firm red tumor on the left wall of the subglottic site, resulting in a grade III subglottic stenosis with a 95% obstruction (Figure 3).

Aspiration of the lesion revealed no blood, and a biopsy for pathologic analysis was performed using a micro forceps. Histopathological findings of the lesion biopsy revealed a pyogenic granuloma (Figure 4) with a lobular pattern of vascular proliferation with inflammation and edema resembling granulation tissue covered by squamous epithelium. There was no pathological evidence of dysplasia or malignancy.

Consequently, the patient underwent an endoscopy for a complete excision of the tumor using a coblator needle-tip wand (in the coagulation mode) (Coblator II, model RE 8000E, from Arthrocare, Costa Rica 680 Vaqueros Ave, Sunnyvale CA 94085). No complications occurred during or after the procedure. The tumor specimen was sent for pathologic analysis. Histopathological findings of the specimen revealed a pyogenic granuloma. At follow-up 2 months later, a third endoscopy was performed and did not reveal any recurrent laryngeal lesion (Figure 5). The patient did not suffer from dyspnea after decannulation.

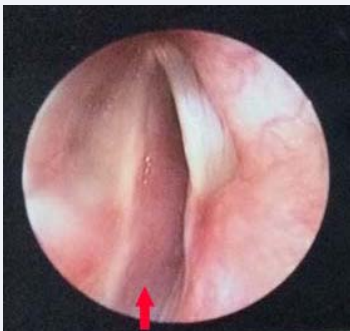

Figure 2 Laryngeal endoscopy revealed a pink soft lesion (arrow) located under the left vocal cord, leading to a grade III subglottic stenosis with a 75% obstruction.

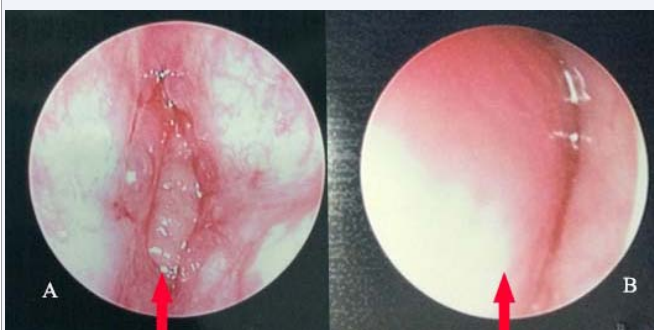


Figure 3 A second laryngeal endoscopy performed 2 weeks after the first tracheostomy revealed a firm red lesion in the left wall of the subglottic site (arrow), leading to grade III subglottic stenosis with a 95% obstruction. Endoscopy image was taken through (A) the patient's mouth and (B) the opening of the trachea.

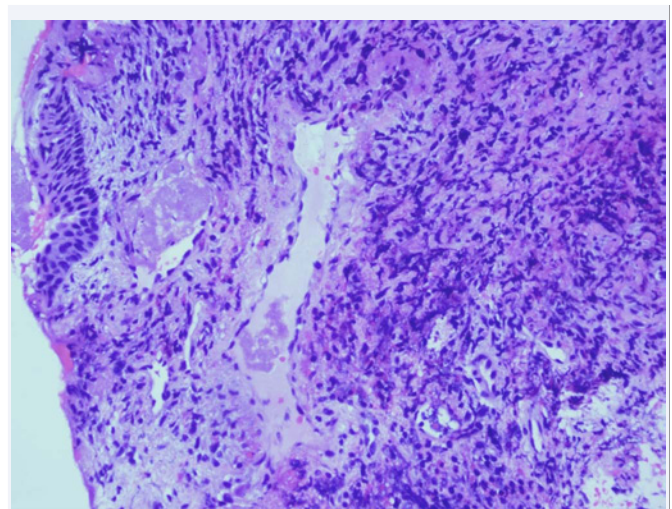


Figure 4 Histopathological findings of the subglottic lesion biopsy specimen revealed a pyogenic granuloma with a lobular pattern of vascular proliferation with inflammation and edema resembling granulation tissue covered by squamous epithelium. (Hematoxylin and Eosin stain; original magnification $\times 40$).

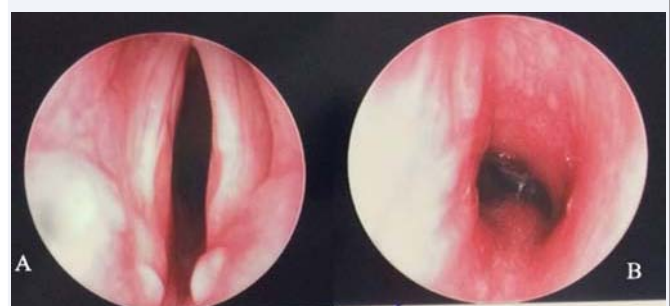

Figure 5 Laryngeal endoscopy was performed through (A) the patient's mouth and (B) the opening of the trachea, after 2 months follow-up. No recurrence was observed.

DISCUSSION

LCH is also called pyogenic granuloma (PG) although it is neither induced by bacterial infection nor a true granuloma [24]. The causes of this disease remain unclear, and may include trauma, drug side effects, hormonal shifts, viral oncogenes, production of angiogenic factors, cytogenetic clonal deletion abnormalities, low-grade local irritation, and traumatic injury [14,15,20,24-26]. In children, 76.9% of LCH lesions appear on the head and neck, and 76.7% of those have no history of trauma or predisposing factors. Most of the manifestations are single lesions [27,28].

LCH lesions are very rare in the airway, with only 18 cases reported in the trachea and the main bronchus, and 4 cases reported in neonatal vocal cords [6-23]. Table 1 summarizes all reported LCH cases, including the current one. However, to the best of our knowledge, LCH has not been described in the subglottic area previously.

Based on the clinical symptoms as well as the chest and neck CT and laryngeal endoscopy findings, a diagnosis of

Table 1: Summary of LCH case reports in the literature.

Author	Age, Male/Female (M/F)	Location of LCH lesion	Size	Treatment	Outcome
Madhumita et al.[10]	40 years, F	Upper third of right anterolateral tracheal wall	10 × 5 mm	Endoscopic excision	Good at 1 year
Irani et al.[8]	72 years, F	3 cm below vocal cords	2–3 mm	Endoscopic excision	Good at 1 year
Amy and Enrique[14]	22 years, M	3 cm above carina on left posterior tracheal wall	10–15 mm	Electrocautery	Good
Porfyridis et al.[13]	17 years, M	Upper third of left anterolateral tracheal wall	4 mm	Endoscopic excision	Good at 1 year
Zambudio et al.[21]	66 years, F	Between first and third tracheal rings	Occluding 30–40% of airway	Embolisation	Good at 1 year
Prakash et al.[7]	23 years, F	Posterior tracheal wall	20 × 40 mm	Endoscopic excision with extracorporeal membrane oxygenation	Good
Xu et al.[6]	64 years, M	Left anterolateral tracheal wall	3–4 mm	Endoscopic excision	Good at 8 months
Chawla et al.[9]	62 years, M	Distal right tracheal wall	Unknown	Endoscopic excision and laser therapy	Unknown
Chen et al.[22]	14 years, F	Lower third of anterior tracheal wall	15–20 mm	Cryotherapy and argon plasma coagulation	Good at 3 months
Udoji and Bechara[15]	55 years, M	Distal left lateral tracheal wall	4 × 5 mm	Cryotherapy	Good at 3 months
Kalanjeri et al.[17]	57 years, M	Posterior middle tracheal wall	Occluding 70% of airway	Electrocautery	Unknown
Jie et al. [12]	35 years, M	Lateral wall of proximal left main bronchus	15–20 mm	Brachytherapy	Good at 2 years
Dabó et al.[19]	51 years, F	Lower third of left lateral tracheal wall	Unknown	Endoscopic excision and laser photocoagulation	Good at 27 months
Putora et al.[23]	64 years, M	Distal tracheal wall	Unknown	Spontaneous remission on cessation of erlotinib for lung cancer	Good
Acharya et al.[18]	56 years, F	2 cm below vocal cords on right tracheal wall	7 mm	Endoscopic excision and electrocautery	Good at 1 year
Liu et al.[11]	17 years, M	Right wall of middle of the trachea	5–10 mm	Argon plasma coagulation, cryotherapy	Good at 11 months
Liu et al.[11]	15 years, F	Lower segment of trachea	15–20 mm	Argon plasma coagulation, cryotherapy	Good at 6 months
Qui et al.[16]	39 years, M	Right intermedius	10 mm	Endoscopic excision, cryotherapy	Good at 2 years
Walner et al.[20]	Neonatal, M	Midportion of the right true vocal cord and ventricle region	Unknown	Endoscopic excision	Good at 36 months
Walner et al. [20]	Neonatal, F	Right true vocal cord	Obstructing 70% of the laryngeal inlet	Endoscopic excision	Good at 6 months
Walner et al. [20]	Neonatal, M	Anterior and midportion of the right true vocal cord	Obstructing 50% of the laryngeal inlet	Endoscopic excision	Good at 2 months
Walner et al. [20]	Neonatal, F	Right false vocal cord and ventricle region	Obstructing 90% of the laryngeal inlet	Endoscopic excision	Good at 2 months
Present case	11 years	Left wall of the subglottic site, just under the surface of the left vocal cord	20mm	Coblation	Good at 2 months

hemangioma was established first. We did not perform a biopsy during the first laryngeal endoscopy due to the high risk of bleeding of the hemangioma. The differential diagnoses of this type of lesion may include granulation tissue, tuberculosis, hemangiopericytoma, angiofibroma, angiosarcoma, and LCH. Notably, LCH located in the airways is very rare. Granulation tissue may result from an endotracheal intubation, or sometimes

secondary to an inflammation or chemical irritation. Hyperplasia lesion of laryngeal tuberculosis was also considered; however, patients who suffer from laryngeal tuberculosis often have a chief complaint of hoarseness with the lesion mainly located on the vocal cord [29, 30]. LCH is distinguished from hemangioma clinically and histologically based on its lobular growth pattern, fibromyxoid background, overlying ulceration, and

acute inflammation [31]. LCH is also distinguished from other neoplasms based on its histopathological findings. Consequently, biopsy for histopathology could play a key role in diagnosis of a laryngeal lesion, and LCH should be considered when diagnosing the cause of a subglottic stenosis.

Many effective treatment modalities have been reported for LCH of the airway, including endoscopic excision, electrocautery, embolization, brachytherapy, argon plasma coagulation, and cryotherapy [6-23]. To date, there have been no comparisons among the various treatment methods for LCH located in the airway. These methods generally achieve good therapeutic effects, but long-term observation is still needed. In the present case, the laryngeal LCH lesion did not respond to intravenous propranolol, but it was successfully removed by an endoscopic coblator, which could be an effective treatment for this type of LCH. Recurrence of skin and mucosal LCH after local therapy is well-known. A recurrence rate of 16% has been reported for oral LCH; the causes were incomplete excision, failure to eradicate the etiological factors, or reinjury of the area [12]. Nevertheless, neither recurrence nor malignant degeneration has been reported with LCH of the airways [6-23]. We recommend close follow up for patients who have a history of laryngeal LCH with endoscopy as necessary.

CONCLUSION

To the best of our knowledge, this is the first report of unique presentation and management of a subglottic LCH. Physicians should be aware of this unique lesion and consider laryngeal LCH as a differential diagnosis of subglottic stenosis, where biopsy for histopathology could play a key role in diagnosis. Moreover, coblation was effective in treating this laryngeal LCH. Finally, further studies are necessary to understand the etiology of laryngeal LCH and ensure effective treatment for these lesions.

ACKNOWLEDGEMENT

We thank Dr. Duy Le Pham, MD., PhD. (Faculty of Medicine, University of Medicine and Pharmacy, Ho Chi Minh City, Vietnam) for his technical support in revising the manuscript. The authors are grateful to all medical staffs, statistician of Children's Hospital I, Ho Chi Minh City, Vietnam for assistance with data acquisition. Special thanks to scientists and professors at The Ohio State University, College of Medicine, Department of Biological Chemistry and Pharmacology, Columbus, Ohio, USA for re-evaluate, recommend and validate important basic intellectual concepts correlate to clinical. The authors are also thankful for the oversight of all aspects of this case report but the Internal Review Boards (IRB) in Vietnam, as well as Department of Public Health, Board of Medicine in Vietnam. Special thanks to all the participant patients who volunteered to sign the consent and followed IRB guidelines/protocol in Vietnam.

REFERENCES

- Antonio C, Pieter J S, Nina Get al. Pathology of the Head and Neck 2nd edition. Springer. 2017.
- Harris MN, Desai R, Chuang TY, Hood AF, Mirowski GW. Lobular capillary hemangiomas: An epidemiologic report, with emphasis on cutaneous lesions. *J Am Acad Dermatology*. 2000; 42: 1012-1016.
- Moffatt DC, Warwryko P, Singh H. Pyogenic granuloma: an unusual cause of massive gastrointestinal bleeding from the small bowel. *Can J Gastroenterol*. 2009; 23: 261-264.
- Fechner RE, Cooper PH, Mills SE. Pyogenic granuloma of the larynx and trachea. A causal and pathologic misnomer for granulation tissue. *Arch Otolaryngol*. 1981; 107: 30-32.
- van Eeden S, Offerhaus GJ, Morsink FH, van Rees BP, Busch OR, van Noesel CJ. Pyogenic granuloma: an unrecognized cause of gastrointestinal bleeding. *Virchows Archiv: an international journal of pathology*. 2004; 444: 590-593.
- Xu Q, Yin X, Sutedjo J, Sun J, Jiang L, Lu L. Lobular capillary hemangioma of the trachea. *Archives of Iranian medicine*. 2015; 18: 127-129.
- Prakash S, Bihari S, Wiersema U. A rare case of rapidly enlarging tracheal lobular capillary hemangioma presenting as difficult to ventilate acute asthma during pregnancy. *BMC Pulmonary Medicine*. 2014; 14: 41.
- Irani S, Brack T, Pfaltz M, Russi EW. Tracheal lobular capillary hemangioma: a rare cause of recurrent hemoptysis. *Chest*. 2003; 123: 2148-2149.
- Chawla M, Stone C, Simoff MJ. Lobular capillary hemangioma of the trachea: the second case. *J Bronchology Interv Pulmonol*. 2010; 17: 238-240.
- Madhumita K, Sreekumar KP, Malini H, Indudharan R. Tracheal haemangioma: case report. *J Laryngol Otol*. 2004; 118: 655-658.
- Liu FL, Chen EG, Zhou P, Jin M, Yang L, Ying KJ. Tracheal lobular capillary hemangioma: two case report and review of the literature. *Zhonghua Jie He He Hu Xi Za Zhi*. 2010; 33: 849-852.
- Jie S, Hong-rui L, Fu-quan Z. Brachytherapy for tracheal lobular capillary haemangioma (LCH). *J Thorac Oncol*. 2012; 7: 939-940.
- Porfyridis I, Zisis C, Glinos K, Stavarakaki K, Rontogianni D, Zakyntinos S, et al. Recurrent cough and hemoptysis associated with tracheal capillary hemangioma in an adolescent boy: a case report. *J Thorac Cardiovasc Surg*. 2007; 134: 1366-1367.
- Amy FT, Enrique DG. Lobular capillary hemangioma in the posterior trachea: a rare cause of hemoptysis. *Case reports in pulmonology*. 2012; 2012: 592524.
- Udoji TN, Bechara RI. Pyogenic granuloma of the distal trachea: a case report. *J Bronchology Interv Pulmonol*. 2011; 18: 281-284.
- Qiu X, Dong Z, Zhang J, Yu J. Lobular capillary hemangioma of the tracheobronchial tree: A case report and literature review. *Medicine*. 2016; 95: e5499.
- Kalanjeri S, Kumar A, Mukhopadhyay S, Mehta AC. Lobular Capillary Hemangioma ("Pyogenic Granuloma") of the Trachea. *Am J Respir Crit Care Med*. 2016; 193: 1429-1430.
- Acharya MN, Kotidis K, Loubani M. Tracheal Lobular Capillary Haemangioma: A Rare Benign Cause of Recurrent Haemoptysis. *Case reports in surgery*. 2016; 2016: 6290424.
- Dabo H, Gomes R, Teixeira N, Teixeira G, Fernandes G, Magalhaes A. Tracheal lobular capillary hemangioma treated with laser photocoagulation. *Jornal brasileiro de pneumologia : publicacao oficial da Sociedade Brasileira de Pneumologia e Tisiologia*. 2016; 42: 72-73.
- Walner DL, Parker NP, Kim OS, Angeles RM, Stich DD. Lobular capillary hemangioma of the neonatal larynx. *Archives of otolaryngology--head & neck surgery*. 2008; 134: 272-277.
- Zambudio AR, Calvo MJ, Lanzas JT, Medina JG, Paricio PP. Massive hemoptysis caused by tracheal hemangioma treated with interventional radiology. *The Annals of thoracic surgery*. 2003; 75:

- 1302-1304.
22. Chen E, Yu X, Zhang Z. A large tracheal capillary hemangioma treated with interventional bronchoscopy. *Respiratory Medicine CME*. 2011; 4: 60-61.
 23. Putora PM, Benz G, Rodriguez R, Brutsche M, Fruh M. Tracheal granuloma pyogenicum with erlotinib treatment for lung cancer. *The European respiratory journal*. 2011; 38: 1228-1230.
 24. Mills SE, Cooper PH, Fechner RE. Lobular capillary hemangioma: the underlying lesion of pyogenic granuloma. A study of 73 cases from the oral and nasal mucous membranes. *The American journal of surgical pathology*. 1980; 4: 470-479.
 25. Yuan K, Wing LY, Lin MT. Pathogenetic roles of angiogenic factors in pyogenic granulomas in pregnancy are modulated by female sex hormones. *Journal of periodontology*. 2002; 73: 701-708.
 26. Jafarzadeh H, Sanatkhan M, Mohtasham N. Oral pyogenic granuloma: a review. *Journal of oral science*. 2006; 48: 167-175.
 27. Pagliai KA, Cohen BA. Pyogenic granuloma in children. *Pediatric dermatology*. 2004; 21: 10-13.
 28. Lian TS. Benign tumors and tumor-like lesions of the oral cavity. *Cummings Otolaryngology-Head and Neck Surgery*. 4th ed, 2005.
 29. Shin JE, Nam SY, Yoo SJ, Kim SY. Changing trends in clinical manifestations of laryngeal tuberculosis. *The Laryngoscope*. 2000; 110: 1950-1953.
 30. Zhao N, Sun Y, Sun Z. Clinical analysis of the diagnosis of laryngeal tuberculosis. *Lin chuang er bi yan hou tou jing wai ke za zhi = Journal of clinical otorhinolaryngology, head, and neck surgery*. 2009; 23: 261-263.
 31. Taira JW, Hill TL, Everett MA. Lobular capillary hemangioma (pyogenic granuloma) with satellitosis. *Journal of the American Academy of Dermatology*. 1992; 27: 297-300.
 32. The English in this document has been checked by at least two professional editors, both native speakers of English. For a certificate, please see:
 33. <http://www.textcheck.com/certificate/Rb4Y6T>

Cite this article

Pham Hoang VL, Dinh NP, Nguyen H, Kitzmiller JP, Doan Hai LB, et al. (2017) Subglottic Lobular Capillary Hemangioma: A Case Report. *J Ear Nose Throat Disord* 2(3): 1028.