

## Case Report

# Resistant Arterial Hypertension in a Patient with Adrenal Incidentaloma Multiple Steno-Obstructive Vascular Lesions and Antiphospholipid Syndrome

Marinelli C<sup>1</sup>, Petramala L<sup>1</sup>, Iannucci G<sup>1</sup>, Gambale G<sup>2</sup>, Concistré A<sup>1</sup>, De Vincentis G<sup>3</sup>, Zaccaria A<sup>4</sup>, De Toma G<sup>5</sup> and Letizia C<sup>1\*</sup>

<sup>1</sup>Department of Internal Medicine and Medical Specialties, University of La Sapienza, Italy

<sup>2</sup>Department of Cardiology, ASL RMB, Italy

<sup>3</sup>Department of Radiology, University of La Sapienza, Italy

<sup>4</sup>Department of Vascular Surgery, University of La Sapienza, Italy

<sup>5</sup>Department of Surgery, University of La Sapienza, Italy

**\*Corresponding author**

Claudio Letizia, Department of Internal Medicine and Medical Specialties, Policlinico Umberto I, Viale del Policlinico 155, Rome, Italy, 00165, Email: claudio.letizia@uniroma1.it

Submitted: 30 December 2014

Accepted: 20 January 2015

Published: 21 January 2015

**Copyright**

© 2015 Letizia et al.

**OPEN ACCESS****Keywords**

- Resistant hypertension
- Multiple arterial stenosis
- Antiphospholipid syndrome
- Sub-clinical Cushing's syndrome
- Adrenal incidentalomas

**Abstract**

Resistant hypertension is defined as above of blood pressure ( $\leq 140/90$  mmHg) despite therapy with three or more antihypertensive drugs of different classes at maximum tolerable doses with one bling a diuretic.

An important consideration in defining a patient with resistant hypertension is the mislabeling of secondary hypertension as resistant hypertension.

Here, we report a patients with resistant hypertension caused by multiple steno-occlusive arteries due to antiphospholipid syndrome and coexisting with subclinical Cushing's syndrome.

**INTRODUCTION**

Hypertension is one of the most popular fields of research in modern medicine due to its high prevalence (around 30% worldwide), and its major impact on cardiovascular risk, such as myocardial infarction, stroke, or cardiovascular death [1]. On the other hand, an effective treatment of hypertension substantially reduces the risk of complications.

Surprisingly, a considerable number of subjects with arterial hypertension remain untreated or uncontrolled despite a combination of antihypertensive drugs [2]. Resistant arterial hypertension is defined as blood pressure higher than 140/90 mmHg despite adherence to at least three maximally tolerated doses of antihypertensive medications from complementary classes including a diuretic at an appropriate dose [3].

An important consideration in defining a patient with resistant hypertension is the mislabeling of secondary hypertension as resistant hypertension [4,5]. Secondary forms of arterial hypertension are not rare and are frequently associated with treatment resistance unless the etiological factor is removed. The list for secondary hypertension is long and includes a wide

variety of conditions [5]. Special attention should be given to the most common causes of secondary hypertension: primary aldosteronism, renal parenchyma diseases, reno vascular diseases, adrenal pheochromocytoma, Cushing's syndrome, and obstructive sleep apnea [6].

Here, we report a patient with resistant hypertension caused by multiple steno-occlusive arteries due to antiphospholipid syndrome (APS) and coexisting with sub-clinical Cushing's syndrome.

**CASE REPORT**

A 58-year-old woman with resistant hypertension, blood pressure (BP) of 220/110 mmHg despite therapy with four antihypertensive drugs (telmisartan, nebivolol, nifedipine, furosemide), post-prandial abdominal pain and left adrenal mass (3 cm) incidentally discovered (Figure 1), was referred to our Specialized Center of Secondary Hypertension, University of Rome "La Sapienza", Rome, Italy. The patient underwent the established clinical and laboratory evaluation to identify essential hypertension and she did not have any secondary causes of hypertension.

Physical examination did not show the typical Cushingoid features such as central obesity, moon face, skin atrophy, purple striae and buffalo hump. Her average BP was 175/105 mmHg equal in both arms, and 24-h-ambulatory blood pressure (ABPM) was 140/90 mmHg with a non-dipping profile. Her height was 165 cm, weight was 65 Kg, and body mass index (BMI) was 25.4 Kg/m<sup>2</sup>. No cardiac murmurs or abdominal bruits were revealed. The ECG showed evidence of mild left ventricular hypertrophy on voltage criteria. The echocardiography confirmed mild ventricular concentric remodeling. Hypertensive retinopathy grade 2 was found at fundus examination.

General laboratory test did not reveal any remarkable abnormalities, except for mild elevation of serum creatinine to 1.16 mg/dl (normal value: 0.50-0.90 mg/dl), a reduction of serum potassium 3.3 mEq/l (normal value: 3.5-5 mEq/l), and microalbuminuria 100 mg/24h (normal value: < 30 mg/24h). The 24 hr creatinine clearance was 87 ml/min (normal value: 95-140 ml/min). Examination of urine showed microematuria.

Renal ultrasonography including Doppler revealed that the right kidney longitudinal size was 11 cm while the left kidney longitudinal size measured 7 cm. Renal blood flows was decreased in the left kidney.

Renal scanning with [99m Tc] diethylenetriaminepentaacetic acid (DTPA) showed lower uptake of the tracer in the left kidney than in the right, and the curve for the left kidney was flat after captopril administration. The scintigraphic images suggested the presence of stenosis of the left renal artery.

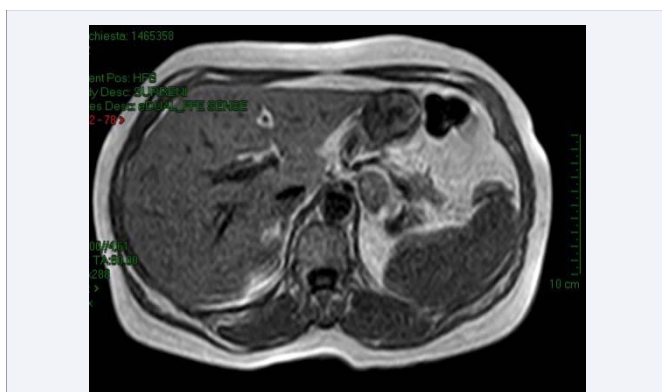
Table 1 shows the hormone test's results. Plasma renin activity (PRA) (19.4 ng/ml/h; normal value 0.2-2.7 ng/ml/h) and plasma aldosterone (PAC) (16.5 ng/dl; normal value 3-16 ng/dl) levels were high. Morning cortisol (PC) levels (27 µg/dl; normal value 4.5-24 µg/dl) and urinary free cortisol excretion (UFC) (170 µg/24h) were high as well. PC levels were not suppressed after overnight dexamethasone suppression test (6.2 µg/dl). Plasma ACTH was 9 pg/ml (normal value: 10-90 pg/ml). Urinary total metanephrines (30 µg/24h) vanillic-mandelic acid (6 mg/24h) excretions were within normal limits (normal values 20-345 µg/24h and 1-13.6 mg/24h, respectively). These findings suggested autonomous secretion of cortisol from the left gland and hyperreninemic aldosteronism. Subsequently, an abdominal

**Table 1:** Data of the hormone tests.

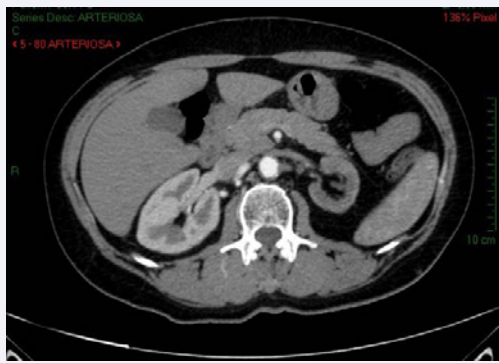
	At diagnosis	Follow-up	range
<b>Serum</b>			
Plasma renin activity (PRA)	19.4	19.0	0.2-2.7 ng/ml/h
Plasma aldosterone (PAC)	16.5	18.9	3.0-16.0 ng/dl
Plasma cortisol (PC)	22.0	23	4.5-21 µg/dl
ACTH	9	10	10-90 pg/ml
PAC/PRA	0.85	0.99	< 40 ng/ml/h:ng/dl
<b>Urine</b>			
Free cortisol (UFC)			30-100 µg/24h
Aldosterone (AUR)	170	270.5	2.8-34 µg/24h
Total metanephrines	23	26	20-345 µg/24h
Vanillic mandelic Acid	30	62	< 13 mg/24h
	6	7	
<b>Desametasone sopprimer test (1 mg/23h)</b>			
PC	6.2	6.0	< 1.8 µg/dl

tomography (CT) with arterial phase was performed. It confirmed the left adrenal mass (30 x 20 cm of diameter) and revealed a thrombosis of the superior mesenteric artery, stenosis of left renal artery and stenosis of common iliac artery (Figure 2). No stenosis was found on the right renal artery. The imaging didn't show evidences of inflammatory vasculitis. Further laboratory evaluation revealed positivity for lupus anticoagulant (LAC), prolonger partial time, anti-β<sub>2</sub>- glycoprotein I antibodies (382 CU; normal value: 0 - 20 CU) while anticardiolipin antibodies (ACA IgG 2,6, ACA IgM 2.1, respectively; normal value 0 - 20 CU), anti-ds-DNA and anti-neutrophil cytoplasmatic antibodies were not found. More parameter of hyper coagulability was within normal range. Antiphospholipid syndrome (APS) was supposed. Angioplasty and stenting was performed for the stenosis of the superior mesenteric artery, left renal artery and common iliac artery. The procedure has been successfully performed and the abdominal pain vanished with amelioration of BP and general conditions. The patient was treated with vitamin k-antagonist (VKA: warfarin) keeping international normalized ratio (INR) about 3. Lupus anticoagulant was also positive after 12 weeks, confirming the diagnosis of APS.

Six months later, the follow up visit revealed poor blood pressure control (BP 150/100 mmHg) despite antihypertensive treatment (telmisartan, nebivolol, furosemide) and the ABPM showed moderate hypertension with non-dipping profile. The hormone tests were performed again. In particular, UFC was 270 µg /24h and the early morning plasma concentration of ACTH was 10.2 pg/ml, while PC was 23 µg /dl. In the dexamethasone (1 mg) suppression test, ACTH was suppressed less than 8.2 pg/ml, whereas PC level decreased 6 µg /dl, confirming insufficient suppression of cortisol secretion. An adrenocortical scintigraphy using 131-I-methyl-norcholesterol showed significant uptake of radiotracer in left adrenal gland, concordant with adrenal mass (Figure 2). Subclinical Cushing's syndrome due to an inappropriate cortisol secretion by left adrenal lesion was diagnosed. One month later, laparoscopic left adrenalectomy was performed. Pre-operative control of BP (140/90 mmHg)



**Figure 1** Abdominal RMN: left adrenal mass with diameter size of 3 cm.



**Figure 2** Angio TC abdomen: stenosis of left renal artery.

was achieved with oral nifedipine 60 mg, telmisartan 80 mg and spironolactone 25 mg. After adrenalectomy, a nodule of 2.5 cm size was removed. Microscopic examination revealed no area of capsule or blood vessel invasion, consistent with a benign adrenocortical adenoma.

Post-operative Glucocorticoid therapy consisted of parenteral hydrocortisonhemisuccinate (200 mg to 30 mg/day) for six days and oral hydrocortisone 20 mg, decreased to 10 mg after the operation. After two months, UFC, PC and ACTH concentrations were within normal range (90.3 $\mu$ g/24h; 15 $\mu$ g/die and 22pg/ml respectively). Duplex ultrasound evidenced elevated velocities within the left renal artery.

## DISCUSSION

In several epidemiological studies, the prevalence of arterial hypertension has been documented with worldwide prevalence of 30% [1]. Essential hypertension is a term applying to cases in which no causes can be identified and accounts for approximately 85% of cases [7].

Secondary forms of hypertension are not rare and are frequently associated with treatment resistance unless the etiological factor is removed [8]. In this paper, we report a case of patient referred in our Center for resistant hypertension and adrenal incidentalomas. Subclinical Cushing's syndrome due to left adrenal adenoma associated with multiple steno-obstructive vascular lesions (comprised left renal artery stenosis) and APS was diagnosed basing on clinical laboratory hormonal tests and imaging studies. In our clinical case the arterial hypertension was considered to be resistant because the patient had been unable to reach his BP goal ( $\leq$  140/90 mmHg) despite of 4 appropriate medications. In fact, resistant hypertension is defined as above goal BP despite therapy with three or more antihypertensive medications of different classes at maximum tolerable doses with one being a diuretic [3]. Prevalence of resistant hypertension is 10% within the hypertensive population [9], and should be considered after excluding pseudo-hypertension and secondary causes of hypertension as primary aldosteronism, renovascular hypertension, Cushing's syndrome and pheochromocytoma.

In particular, guidelines for the management of hypertension recommended performing further examinations such as normal tests and renography if a clinical feature suggests secondary hypertension among hypertensive [10].

In our case, the resistant hypertension is secondary to the multiple artery stenosis due to APS coexisting with hypercortisolism (subclinical Cushing's syndrome). APS is defined by the combination of venous arterial occlusive events, predominantly a thrombotic condition, accompanied by thrombocytopenia, in the presence of anti phospholipid antibodies [11-13]. The absence of any connective tissue disease is a characteristic of the primary form of the syndrome.

Major thrombotic events occur in the deep venous system, and the arterial occlusion is more frequently and predominates in the central territory [14]. Moreover, the thrombosis may develop anywhere in the renal vein and arteries [15]. Physiopathology of stenosis in APS remains unclear, but some investigators suggested arterial wall thrombosis, accelerated atherosclerosis, and/or proliferation of smooth muscle cells.

In particular, some data suggest that antiphospholipid antibodies have an effect on the initiation of endothelial cell lesions that characterize arteriosclerosis [16]. In fact, antiphospholipid antibodies have been shown to have atherogenesis properties, because they can cross-react with oxidized low density lipoprotein (OX-LDL) and may activated the endothelium system, a potent vasoconstrictor peptide [17]. In our patient we found many steno-obstructive disorders in abdominal vascularization and in particular in the left renal artery. Sangle et al [18] have demonstrated a significantly higher prevalence of renal artery stenosis (26%) in patients with APS who have difficult control hypertension, than in a hypertensive group, and suggested that renal artery stenosis may be an important cause of hypertension in APS.

Approximately, 70 percent of adrenal incidentalomas discovered in patients without extra-adrenal malignancy are benign adrenocortical adenoma [19-20].

Several studies have shown that a subset of these tumors secrete a mild excess of cortisol leading to the concept of "subclinical cortisol-secreting adenomas" [21]. Depending on the diagnostic criteria and the study design used, subclinical Cushing's syndrome is found in 5% to 20 % of patients with adrenal incidentalomas [22]. Several studies have reported increasing evidence that subtle cortisol production and abnormalities in the hypothalamic-pituitary-adrenal axis are more frequent than previously thought.

Barzon et al [23] found the estimated cumulative risk to develop overt Cushing's syndrome of 12.5% after one year when considering only patients with subclinical autonomous glucocorticoid over- production. Recent evidence suggests that subclinical Cushing's syndrome might be associated with increased risk for arterial hypertension, diabetes, or osteoporosis [24]. In particular, the prevalence of hypertension in patients with endogenous hypercortisolism is approximately 80%, and the majority of patients present mild to moderate hypertension, whereas 17% could present severe form. Moreover, the hypertension is characterized by dysregulation of the BP circadian rhythm, with loss of the physiological nocturnal fall [24,25]. Our patient has a severe form hypertension with no-dipping profile at ABPM.

The mechanism of Glucocorticoid-induced hypertension

and resistant hypertension was been largely elucidated: 1) activation of the renin-angiotensin system; 2) enhancement of cardiovascular reactivity to vasoconstrictors (catecholamine, endothelin, vasopressin and angiotensin II); 3) increased beta-adrenergic receptor sensitivity to catecholamine; 4) suppression of the vasodilatory systems (NO synthase, prostacyclin and kinin-kallicrein); 5) increased cardiac output, total peripheral resistance and renovascular resistance [24]-

The hypertension in patients with endogenous hypercortisolism is significantly correlated with the duration of disease, and optimal treatment is the correction of the hypercortisolism without permanent dependence of hormone replacement.

In conclusion, we report the case of patient with resistant hypertension caused by multiple steno-occlusive arteries due to APS and coexisting with subclinical Cushing's syndrome. BP falls is related to both dilatation of renal artery stenosis and removal of the cortisol-adrenal adenoma, so that antihypertensive therapy was successfully reduced, but not completely stopped. Probably, stable renal dysfunction occurred from too much time prior our specific treatment, preventing the complete normalization of blood pressure.

## REFERENCES

- Kearney PM, Whelton M, Reynolds K, Muntner P, Whelton PK, He J. Global burden of hypertension: analysis of worldwide data. *Lancet*. 2005; 365: 217-223.
- Kaplan NM. Resistant hypertension. *J Hypertens*. 2005; 23: 1441-1444.
- Calhoun DA, Jones D, Textor S, Goff DC, Murphy TP, Toto RD, et al. Resistant hypertension: diagnosis, evaluation, and treatment: a scientific statement from the American Heart Association Professional Education Committee of the Council for High Blood Pressure Research. *Circulation*. 2008; 117:510-526.
- Vrijens B, Vincze G, Kristanto P, Urquhart J, Burnier M. Adherence to prescribed antihypertensive drug treatments: longitudinal study of electronically compiled dosing histories. *BMJ*. 2008; 336: 1114-1117.
- Veglio F, Grassi G, Mancia G, Volpe M; Italian Society of Hypertension. Clinical management of resistant hypertension: practical recommendations from the Italian Society of Hypertension (SIIA). *High Blood Press Cardiovasc Prev*. 2013; 20:251-256.
- Sukor N. Endocrine hypertension--current understanding and comprehensive management review. *Eur J Intern Med*. 2011; 22: 433-440.
- Rimoldi SF, Scherrer U, Messerli FH. Secondary arterial hypertension: when, who, and how to screen? *Eur Heart J*. 2014; 35: 1245-1254.
- Faselis C, Doumas M, Papademetriou V. Common secondary causes of resistant hypertension and rational for treatment. *Int J Hypertens*. 2011; 2011: 236239.
- Persell SD. Prevalence of resistant hypertension in the United States, 2003-2008. *Hypertension*. 2011; 57: 1076-1080.
- Mancia G, Fagard R, Narkiewicz K, Redón J, Zanchetti A, Böhm M, et al. 2013 ESH/ESC Guidelines for the management of arterial hypertension: the Task Force for the management of arterial hypertension of the European Society of Hypertension (ESH) and of the European Society of Cardiology (ESC). *J Hypertens*. 2013, 31:1281-1357.
- Hughes GR. Thrombosis, abortion, cerebral disease, and the lupus anticoagulant. *Br Med J (Clin Res Ed)*. 1983; 287: 1088-1089.
- Lim W, Crowther MA, Eikelboom JW. Management of antiphospholipid antibody syndrome: a systematic review. *JAMA*. 2006; 295: 1050-1057.
- Keeling D, Mackie I, Moore GW, Greer IA, Greaves M; British Committee for Standards in Haematology. Guidelines on the investigation and management of antiphospholipid syndrome. *Br J Haematol*. 2012; 157: 47-58.
- Wong M, Sangle S, Jan W, Hughes GR, D'Cruz DP. Intracerebral arterial stenosis with neurological events associated with antiphospholipid syndrome. *Rheumatology (Oxford)*. 2005; 44:948-949.
- Sangle SR, D'Cruz DP, Jan W, Karim MY, Khamashta MA, Abbs IC, et al. Renal artery stenosis in the antiphospholipid (Hughes) syndrome and hypertension. *Ann Rheum Dis*. 2003; 62: 999-1002.
- Ben-Ami D, Bar-Meir E, Shoenfeld Y. Stenosis in antiphospholipid syndrome: a new finding with clinical implications. *Lupus*. 2006; 15: 466-472.
- Hasunuma Y, Matsuura E, Makita Z, Katahira T, Nishi S, Koike T. Involvement of beta 2-glycoprotein I and anticardiolipin antibodies in oxidatively modified low-density lipoprotein uptake by macrophages. *Clin Exp Immunol*. 1997; 107: 569-573.
- Sangle SR, D'Cruz DP, Jan W, Karim MY, Khamashta MA, Abbs IC, et al. Renal artery stenosis in the antiphospholipid (Hughes) syndrome and hypertension. *Ann Rheum Dis*. 2003; 62: 999-1002.
- Kloos RT, Gross MD, Francis IR, Korobkin M, Shapiro B. Incidentally discovered adrenal masses. *Endocr Rev*. 1995; 16: 460-484.
- Chidiac RM, Aron DC. Incidentalomas. A disease of modern technology. *Endocrinol Metab Clin North Am*. 1997; 26: 233-253.
- Terzolo M, Osella G, Ali A, Borretta G, Cesario F, Paccotti P, et al. Subclinical Cushing's syndrome in adrenal incidentaloma. *Clin Endocrinol (Oxf)*. 1998; 48: 89-97.
- Mantero F, Terzolo M, Arnaldi G, Osella G, Masini AM, Ali A, et al. A survey on adrenal incidentaloma in Italy. Study Group on Adrenal Tumors of the Italian Society of Endocrinology. *J Clin Endocrinol Metab*. 2000; 85: 637-644.
- Barzon L, Fallo F, Sonino N, Boscaro M. Development of overt Cushing's syndrome in patients with adrenal incidentaloma. *Eur J Endocrinol*. 2002; 146: 61-66.
- Cicala MV, Mantero F. Hypertension in Cushing's syndrome: from pathogenesis to treatment. *Neuroendocrinology*. 2010; 92 Suppl 1: 44-49.
- Magiakou MA, Smyrnaki P, Chrousos GP. Hypertension in Cushing's syndrome. *Best Pract Res Clin Endocrinol Metab*. 2006; 20: 467-482.

### Cite this article

Marinelli C, Petramala L, Iannucci G, Gambale G, Concistré A, et al. (2015) Resistant Arterial Hypertension in a Patient with Adrenal Incidentaloma Multiple Steno-Obstructive Vascular Lesions and Antiphospholipid Syndrome. *Ann Clin Exp Hypertension* 3(1): 1020.