

## Review Article

# Treatment of Chronic Lateral Ankle Instability - A Review

Bäcker H\*, Krause FG, and Attinger MC

*Department of Orthopaedic Surgery and Traumatology, University Hospital Berne, Switzerland*

## \*Corresponding author

Bäcker H, Department for Orthopaedic Surgery and Traumatology, University Hospital Berne, 3010 Bern, Switzerland, Email: henrikbaecker@gmx.de

Submitted: 11 April 2016

Accepted: 21 January 2017

Published: 25 January 2017

## Copyright

© 2017 Bäcker et al.

## OPEN ACCESS

**Abstract**

Ankle sprain is a common type of sports injury that may cause chronic ankle instability in approximately 20 - 30% of cases. Patients typically suffer from pain, recurrent ankle sprains and swelling of the ankle. In the long run, 20 - 30% of chronic ankle instability patients will develop ankle arthritis. To enable appropriate sufficient early treatment, a contemporary diagnosis is required, which in turn influences the choice and type of treatment option. In addition to the conservative treatment options - general muscle strengthening, biofeedback and feed forward programs - with or without external supports, a variety of surgical procedures exist. According to the latest consensus the conservative treatment shall be performed first, followed by ankle arthroscopy and the Broström-Gould repair in case of failure. In more complex cases with insufficient ligamentous remnants an anatomical minimal invasive procedure is the treatment of choice. The latest achievements of research like arthroscopic repair/reconstructions or muscular simulation controlled by plantar sensors show promising results. We want to give an overview of different treatment options, possibilities and cascade to simplify the therapy.

**Keywords**

- Chronic lateral ankle instability
- Ligaments
- Operative procedures; Stabilization
- Ankle ligament reconstruction

**INTRODUCTION**

Ankle sprain is the most common injury of the musculoskeletal system that covers approximately 25%. It may occur in every age, sex and activity group. Approximately 10 to 15%, who sprain their ankle, rupture the lateral ankle ligaments [1,2].

**ANATOMY**

The lateral ankle stabilization is warranted by three ligaments: anterior and posterior talofibular ligaments (ATFL and PTFL) and calcaneo fibular ligament (CFL). The ATFL is the weakest one, coursing obliquely from posterolateral to anteromedial in the sagittal plane and restricts internal rotation and anterior subluxation of the talus in the ankle mortise [3]. An isolated rupture of the ATFL is most common and occurs at supination sprains. The stronger CFL connects the fibula and calcaneus, running from the anterior distal part of the tip inferiorly and about 30 degrees posteriorly to the lateral calcaneal wall underneath the peroneal tendons. It restricts lateral tilting of the talus and calcaneus and ruptures especially in isolation at inversion sprains. Even so isolate ruptures occur; a combination of simultaneous ATFL and CFL tears is more frequent. An injury of the PTFL is extremely rare and occurs only in high-energy trauma.

The range of motion of the ankle joint can be divided into active and passive one. It allows dorsiflexion and plantar flexion (active from 20° to 55°). Because of a wider anterior trochlea than

posterior one, talus rotation in the ankle mortise is enabled. In dorsiflexion an external rotation up to 6° with a slight pronation is possible and vice versa - in plantar flexion the talus is rotating internally as well as a slight supination.

The talocrural joint is mainly stabilized by passive ligamentous structures and bony contour. As no muscle is attached to the talus, muscular support accounts only for little stabilization. The musculo tendinous units cross the ankle and stabilize the subtalar joint dynamically -above all the peroneal and posterior tibialis tendons [14].

**ACUTE ANKLE SPRAIN**

There are extrinsic factors such as high exercise loads or traumatic injuries as well as intrinsic ones for example strength deficits, anatomic variations and gender participating in chronic ankle instability.

The anatomical variations have been described by Scranton et al., and later confirmed by Mc Dermott et al., stating that a posterior position of the fibula predisposes chronic ankle instability by weakening the ATFL which secures subluxation and internal rotation in plantar flexion [5,6]. In a cadaveric study Mc Dermott et al., discovered that weight-bearing provokes distal movement of the fibula and deepening the mortise there by. This may also explain why patients, mainly children, with restricted ankle dorsiflexion are more prone for chronic instability. Another anatomical variation is a hind foot varus which leads to instability but is only present in a small population [7,8].

Classically, ankle sprains occur when inverting the plantar flexed ankle and rotating the tibia outward simultaneously at heel strike during the gait circle. The medial malleolus acts as fulcrum and increases stress on the lateral side. A high strain acts on the ATFL leading to partial or even complete tear. An isolated rupture occurs in approximately 50% to 75% of cases; however a partial rupture or isolated capsular lesion is present in only 1% [9]. As the foot hits the ground a rebound dorsiflexion occurs accompanying failure of the CFL in 15% to 25% of cases [10].

Another type of injury is the high ankle sprain when the anterior inferior tibiofibular ligament - a part of the syndesmosis - is injured. This may be caused by internal rotation of the leg on a planted, fully plantigrade foot (external rotation of the foot). It occurs in 1% to 5% mainly in high traumatic injuries like soccer players or skiers [11].

The injuries are classified in grade I to III (mild, moderate and severe). Macroscopic ruptures can be seen beginning from grade II up to complete rupture of the ligaments and joint capsula leading to loss of function and reduction of motion in grade III. The prognosis depends on the grade where grade I shows significantly better outcome than higher grades. No significant difference can be observed between grade II and III [12].

## CHRONIC LATERAL ANKLE INSTABILITY

Once an acute ligament rupture occurs, chronic lateral ankle instability will result in about 20% from inappropriate healing after one or recurrent ligamentous injuries. Common accompanying complications are tendinitis, soft tissue impingement or rupture of the stabilizing muscles or osteochondral lesions at the medial and lateral talar dome. In the long-term, osteochondral lesions and chronic elevated shear forces of the ankle cartilage may lead to posttraumatic ankle arthritis. Weakness of the injured ligaments cause higher stress on the remaining intact ones - mainly leading to medial instability [13].

## DIAGNOSIS

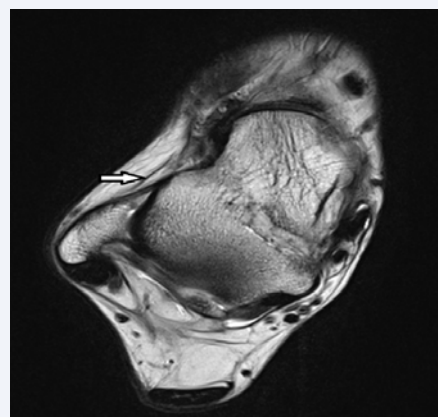
To begin with an anamnesis is essential for clinical assessment. Hereby it is important to distinguish between lateral supination or inversion and medial eversion ankle sprain. Accordingly, the symptoms may be primarily present at the lateral or medial malleolus. In chronic ankle instability patients often complain about recurrent acute ankle sprains or non-traumatic giving ways, leading to avoidance or adaptation of sport activities. Patients may also perceive an unstable or abnormal ankle with pain or swelling [14].

During clinical examination the gait cycle and the weight bearing foot must be evaluated as a hind foot varus predisposes to chronic ankle instability. Furthermore the range of motion of the ankle shall be measured actively and passively as well as the individual muscles in terms of strength, pain and tightness - such as gastrocnemius, peroneal and both tibial muscles. The most sensitive test to evaluate the laxity is the anterior drawer test, which should be performed in sitting position for better evaluation. The proprioception may be measured by performing a single leg stance first with open- and later on with closed eyes. The test allows distinguishing between mechanical and functional

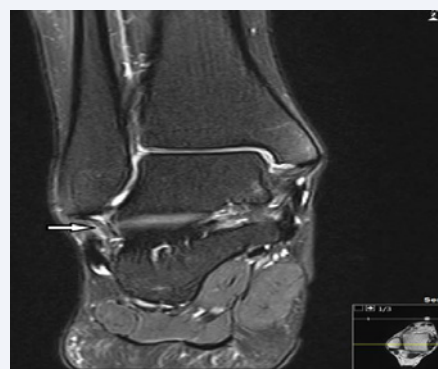
instability [15]. All examinations must be performed on both feet to compare and identify individual differences. To estimate the generalized joint laxity the Beighton scale may be used.

In addition to clinical examination, radiographies shall be performed - weight-bearing of the ankle in three different views (antero-posterior, lateral and mortise view) - to exclude a fracture and to estimate the hindfoot position. Applying anterior and lateral stress under fluoroscopy, lateral chronic ankle instability may be visualized by more than 10mm anterior talar translation or 9° talar tilt (or more than 3mm anterior talar translation and more than 3° talar tilt in relation to the opposite side). A gravity stress view (lateral talar migration) allows assessing syndesmosis instability - even though the false negative rate is high [16,17]. If there is still doubt after clinical and radiological examinations, ultrasound or MR imaging help to evaluate any ligament injuries (Figures 1,2).

Several scores exist to quantify the functional status of patients with lateral ankle instability, such as the Karlsson score, Foot and ankle assessment measure as well as the American orthopaedic foot and ankle score. For patients who require a ligament reconstruction the consensus agreed to use the foot and ankle outcome score (FAOS) in conjunction with the EuroQol - EQ5D as both tests are easy to perform and valuable for diagnosis [14].



**Figure 1** T2 axial MRI image of ruptured ATFL (indicated by arrow).



**Figure 2** T2 coronal MRI image of ruptured CFL (indicated by arrow).

## TREATMENT

There is a huge range of treatment options in chronic ankle instability. In the first place a non-surgical management shall be considered. If the conservative treatment fails, the surgical options vary from numerous anatomical repairs and reconstructions to non-anatomical reconstructions using a tendon auto- or allograft for stabilization of the ankle which will be listed in the following.

### Conservative management

The conservative treatment follows the paradigm of acute ankle sprain according the RICE principles, which is applied directly after trauma. At least 2 to 3 months after trauma, physiotherapy allows improving proprioception, strengthening the peroneal tendons and stretching the Achilles tendon to avoid an equinus deformity. During the rehabilitation program only symptom free multidirectional exercises shall be performed to stabilize and strengthen all muscles of the lower leg. At the end of the program, stress exercises are performed in plantar flexion and inversion of the foot allowing functional stabilization. An alternative option is a biofeedback program to avoid "tetanisation" described by Freeman et al., or a feed forward program - also called pre activation - aiming for a neurovascular reprogramming of the ankle according Thonnard et al. Overall, approximately half of the patients regain satisfactory functional stability after a 12 week program [18-20].

### Ankle external forces - braces

To support the healing process of the ligaments, and improve ankle positioning, external devices such as orthoses or taping may be used. Semi rigid ankle orthoses tend to be too limiting in sports, however show good results in stabilization – mechanical as well as functional in terms of proprioception [21,22]. Ankle taping is also effective to reduce the incidence of recurrent ankle sprains by limiting range of ankle motion; however, the positive effect is lost approximately 10 minutes after exercising. Significant improvement in speed, static and dynamic balance and proprioception were reported three-month after application of an ankle bandage in patients who suffered from functional ankle instability. Mickel TJ et al., performed a prospective study on the primary prevention of ankle sprain and stated that no significant difference in the onset could be observed between ankle orthoses and taping in high school football players. In terms of cost and time the taping was less efficient. These results support other studies on the positive benefit in ankle sprain. Furthermore a lace up ankle brace deteriorated single and double limb balance in healthy people by inhibiting the peripheral receptors or limiting the range of motion. In addition an improvement in the proprioception – the feedback from the ankle angle position and the perception of the orientation - is described. This may be related to ligament mechanoreceptors for proprioception in three dimensional ankle orientations, other joint receptors as well as plantar skin receptors [23,24].

As mentioned earlier the peroneal muscles have major impact on the functional stability. Cordova et al., investigated the effect of the peroneus longus stretch reflex when wearing a brace and short time after. He concluded that the peroneal reaction amplitude is influenced positively when wearing a brace leading

to a faster pronation. This prohibits ligament damages when twisting one's ankle than without wearing a brace.

To summarize there is good evidence for the use of ankle brace or tape to prevent recurrent ankle sprain in patients who suffered from ankle instability. According Dizon JMR et al., the incidences of knee injuries is increased in relation to the control group but were not further investigated. For healthy people no real evidence could be noted.

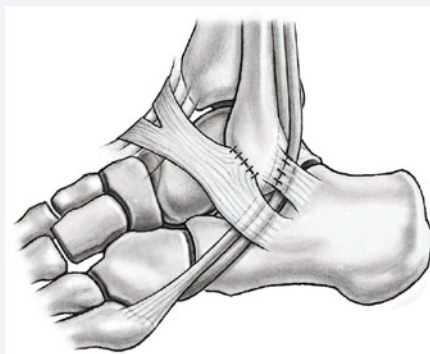## OUTLOOK

There are a couple of new approaches displaying the ankle kinematics by using inertial motion sensors and predicting ankle sprain. Therefore an electrical stimulator is connected to the peroneal muscles via surface electrodes. Continuous data logging is performed wireless (Bluetooth) between the cell phone and the electrodes. When an injury is predicted, the peroneal muscles are stimulated electrically causing a dorsiflexion of the foot. This system allows monitoring as well as preventing chronic ankle sprain and quantifies progression with a time of response of 7msec (prototype). As only a prototype exists, the short- and long-term results are missing [25-30].

## SURGICAL TREATMENT

A whole lot of surgical procedures exist in chronic lateral ankle instability which can be divided into anatomical repair and reconstruction.

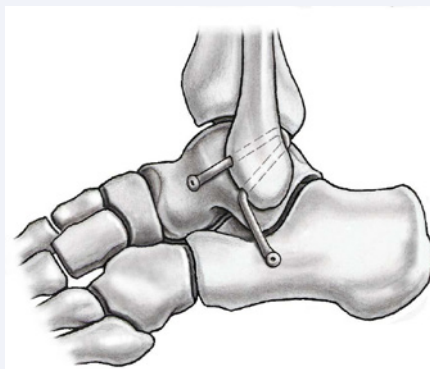1. Anatomical repair: The most common local ligament and soft tissue repair is the Broström procedure. It was first described in 1966 and includes a transfer of the extensor retinaculum to the proximal advancement. The procedure is mainly performed in combination with a repair of the lateral talocalcaneal ligament - Gould procedure - or a pedicle flap of the retinaculum [31-34]. It is controversially discussed whether the retinaculum transfer provides mechanical or mainly functional (proprioceptive) stability. Because of good long-term results (functional stability in 85%) [33], especially in those patients who do not suffer from a generalized hypermobility of the joints, the Broström procedure is primarily performed in chronic lateral ankle ligament instability [35]. Alternatively Karlsson et al., recommend



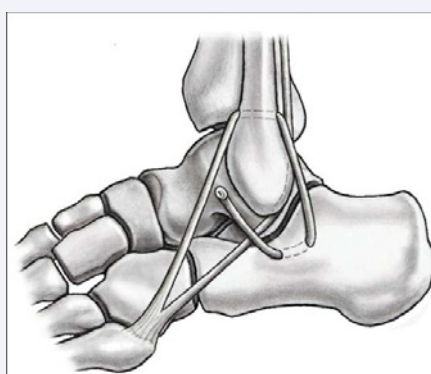
**Figure 3** Broström-Gould technique – transfer of the extensor retinaculum in addition to a repair of the CFL and ATFL.

a shortening and reattachment to the fibula as the ATFL and CFL is rather elongated and scarified than ruptured (Figure 3).

2. In patients who failed a prior Broström-Gould repair, a non-arthroscopic minimally invasive tendon transfer or tendon graft anatomical reconstruction of the ligaments is recommended. This procedure suits also for patients with congenital laxity, high body mass index or heavy labor and sports occupation [36]. This repair method using the plantaris tendon for reconstructing the ATFL was first described by Weber et al., in 1968. Later on it was modified by Segesser and Gosele to reconstruct the CFL. Alternative methods are the Solheim and Elmslie procedure using the Achilles tendon respectively the free fascia lata [28,29]. Common grafts used are peroneal tendons or peroneal tendon splits, hamstrings / semitendinosus or allograft. The fixation on the talus and calcaneus is ensured by anchors, interference-screws or endobuttons. The tendons are routed through fibula-tunnels where the numbers and angles are important. In 2004, Coughlin published good short term follow up results - up to 23 months - using the gracilis tendon for anatomically reconstruction of the ATFL and CFL. It is an effective salvage procedure, without causing an extensive exposure of risk for neural lesions, in long-standing chronic lateral ankle instability without any residual ligaments (Figure 4).
3. The non-anatomical reconstructions of the lateral ankle ligaments are rather old stabilization techniques. In the past the tenodeses was one of the most favored surgical treatments. Three different classic procedures exist: Evans, Watson- Jones and Chrisman-Snook. The Watson-Jones procedure is a reconstruction of the ATFL only; whereas the Chrisman-Snook technique - being the most common non-anatomic reconstruction performed at the moment - restores the ATFL as well as the CFL. These techniques utilize part or the entire peroneal tendon as graft for transfer. In short-term the results are good, however in the long-term the results deteriorated [30]. It may result in weakness leading to a restricted range of subtalar and ankle motion and a persistent mechanical laxity, developing degenerative changes over years. 14 years after surgical intervention satisfactory results were in less than 50%. Major problems were increased laxity, reduction of ankle function as well as pain (Figure 5) [31-34].
4. In addition to lateral reconstruction or repair procedures, ankle arthroscopy is recommended as it allows detecting intra articular osteochondral and ligamentous lesions. The first arthroscopic repair was reported in 1987. Ever since various options to repair or reconstruct the lateral ligaments arthroscopically have been described using either stapling, bone tunnel or suture anchor. A rather new arthroscopic technique is the thermal shrinkage technique of the ATFL or thermal assist capsular shrinkage. Approximately 30% of the elongated ATFL is shrunk (from 30mm to about 20mm). The different



**Figure 4** Coughlin procedure using a gracilis graft.

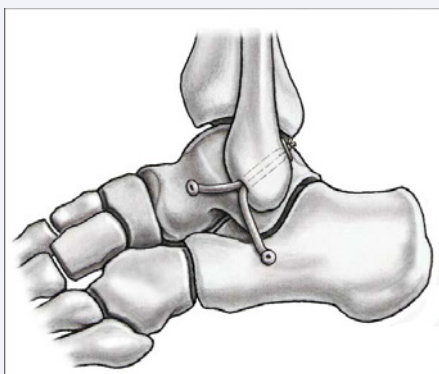


**Figure 5** Chrisman-Snook procedure - split of the peroneus brevis tendon and threaded through the anterior talocalcaneal ligament followed through the fibula tunnel.

techniques show promising results; however, only short-term follow-up exists. Some studies mentioned that ligament and capsular shrinkage is ineffective in case of a complete ligament rupture [35,36].

5. Reconstruction using arthroscopy was first described by Priano et al., in 1994. He dissected a pedicle flap of fibular periosteum to reinforce the ATFL and fixate it with anchors [37]. A rather technical demanding procedure was described by Lui et al. In ankle and subtalar instability he recommends a reconstruction of the CFL and the ATFL using the peroneal tendon. The anterolateral arthroscopically portal is chosen to drill two bone tunnels for anatomical reconstruction. The peroneal tendon sheath is dissected and stripped through the middle subtalar portal. In 2014 Guillo et al., described a utilized peroneal tendoscopy to perform a better identification of ATFL and CFL [38-40]. This allows greater accuracy of tunnel localization using a gracilis tendon graft. Latest ligament reconstruction procedures use synthetic materials, however because these techniques are new no follow-up results have been reported so far. All techniques have in common to place suture anchors into the fibula to replicate the Broström-Gould procedure. In a systemic review of the minimal invasive surgical treatment, Matsui et al., concluded that there is poor quality evidence to





**Figure 6** Arthroscopic reconstruction of the ATFL and CFL using the gracilis tendon described by Guillo et al.

support this arthroscopic reconstruction in chronic ankle instability yet (Figure 6) [41,42].

6. A more invasive procedure is the osteotomy. In varus or neutral hindfoot alignment a lateral sliding osteotomy is recommended to prevent recurrent ankle sprains and protect the repaired or reconstructed ligaments. Alternatively a supramalleolar valgus osteotomy can be performed which provides similar outcome to reduce joint pressure in cavovarus feet (Figure 7) [43-46].

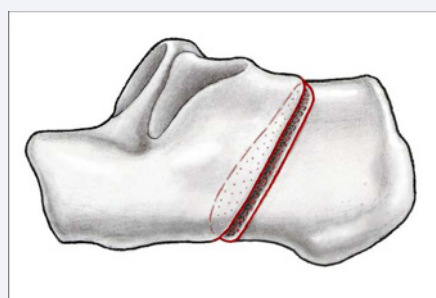
## AUTHOR'S PREFERRED APPROACH

In our clinical practice the most common procedure performed is the anatomical reconstruction of the ATFL and CFL using a technique similar to Coughlin's approach. The patient is under general or spinal anesthesia and positioned in half or full lateral decubitus position. Double-check of the clinical and / or radiological instability under anesthesia is recommended. A tourniquet is inflated between 250 and 350mmHg located at the thigh. Ankle arthroscopy is performed in the majority of cases. A 6-7cm curved skin incision runs from the lateral malleolus to the inferior aspect of the talar head. Care is taken not to injure the sural nerve or branches of the superficial peroneal nerve [47-50]. The ATFL and CFL are exposed by opening the anterolateral ankle capsule and the peroneal tendon sheath. If the quality of the ligamentous remnants is poor, the indication for an anatomic ligament reconstruction is given (Figure 8a, 8b).

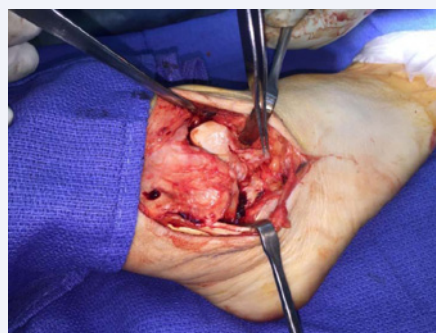
The gracilis tendon is harvested from the ipsilateral pes anserinus. For the talar insertion a 4.5mm tunnel is drilled at the original ATFL insertion through the talar neck. A second 4.5mm tunnel is drilled at the fibular ATFL insertion but directed upwards about 30 degrees. For the CFL a third 4.5mm tunnel is drilled 10mm lower into the posterior aspect of the fibula, aiming for the fibular CFL insertion. The 10mm bony bridge prevents a cutout of the tendon in weak bone and allows drawing the tendon through the bone faster than through a 180 degrees curved tunnel, as described in Coughlin's technique. The final 4.5mm tunnel is drilled at the calcaneal CFL insertion directing to the medial Achilles insertion at the calcaneal tuberosity while the peroneal tendons are gently retracted inferiorly. The gracilis tendon is armed with non-absorbable sutures at both ends (Ethibond 3-0, Ethicon, and Sommerville, NJ, USA) and

routed through all four tunnels by shuttle sutures [51-53]. To draw the suture ends through the skin on the medial talar neck and the medial plantar calcaneal tuberosity, stab incisions are necessary. The tendon is fixed with one 5x23 mm interference screw (Milagro, De Puy Synthes, Warsaw, IN, USA) each, with the hindfoot held in eversion and the non-absorbable sutures held tight at their ends on the medial talar neck and the medial plantar calcaneal tuberosity (Figure 9).

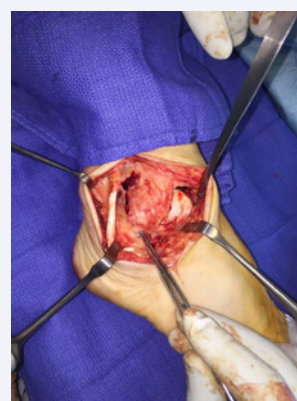The indication for an additional lateral sliding calcaneal osteotomy is generously given in case of a neutral, respectively varushind foot alignment or in cases of failure of a primarily stabilization. Postoperatively a cast is adjusted in slight hindfoot eversion for a total of 6 weeks. The patient is kept non-weight bearing for the first three weeks followed by 10kg for another



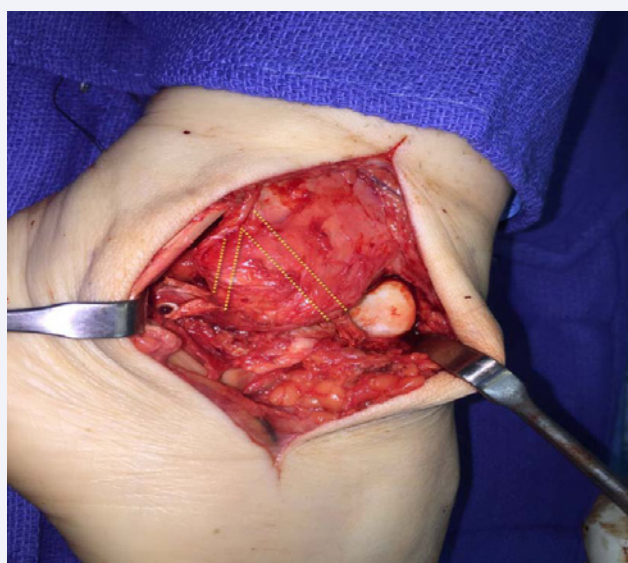
**Figure 7** Lateral sliding calcaneus osteotomy.



**Figure 8a** Intraoperative pictures of a ruptured ATFL.



**Figure 8b** Intact CFL indicated by the forceps.



**Figure 9** Intraoperative picture of the Coughlin procedure modified with interference screws.

three weeks.

## COMPARISON OF GRAFTS IN RECONSTRUCTION TECHNIQUES

The Coughlin procedure shows great results in short term follow up of up to two years. Five patients suffered from recurrent sprains, which could be treated conservatively. When using a semitendinosus tendon the risk of complications are about the same, however the good/ excellent results measured using the Karlsson score were a bit less (88%) published by Jung et al., Yung et al., reported slightly better outcome in patient satisfaction using the gracilis tendon than the semitendinosus allograft however no significant difference could be identified between suture fixation and interference screws. No significant difference could be identified between semitendinosus autograft and allograft (Table 1).

## CONCLUSION

The acute lateral ankle sprain is a common injury which leads to a chronic ankle instability in about 20% to 30%. Primarily a conservatively treatment based on physiotherapy shall be

**Table 1:** Comparison of ligament reconstruction using gracilis vs. semitendinosus graft in short term follow up.

Year published; Journal	Author	Number of patients	Number of ankle stabilized	Mean age	Follow up (month)	Good/ Excellent results (%)	Complications	Graft used	Reconstructed structures
2004 Foot Ankle Int.	Coughlin MJ	28	29	31	23	100	2 cases of cellulitis, 1 dysesthesia in sural nerve, 5 recurrent sprains – conservative treated	Gracilis autograft; suture fixation	ATFL + CFL
2005 Am J Sports Med	Takao M	21	21	29.6	Min 24	Unclear	None	Semitendinosus allograft and interference screw	17 patients ATFL 4 patients ATFL + CFL
2006 Foot and Ankle Clinics	Caprio A	11	11	Unknown	14.1	Unclear	None	Semitendinosus allograft; suture anchor	ATFL + CFL
2011 Foot Ankle Surg.	Ibrahim SA	16	16	25	33.5	100	None	Gracilis autograft ; interference screw	ATFL + CFL
2012 Int Orthop	Hua Y	35	36	29.2	37.9	Unclear	2 cases of infections ; 2 patients with residual instability	Semitendinosus allograft; interference screws in calcaneus and sutures elsewhere	ATFL + CFL
2012 Knee Surg Sports Traumatol Arthrosc.	Jung HG	27	28	36.5	19	88	none	Semitendinosus allograft; interference screw	ATFL + CFL

performed. External supports may be used for more functional stability. In cases of failure of the conservative treatment or complex ligament ruptures, surgical procedures are the method of choice. Overall the preliminary results of minimal invasive surgery, techniques using arthroscopy or thermal shrinking of ligaments are promising but require longer follow-up researches to prove its effectiveness. According the current consensus in "simple" ankle instability a Broström-Gould repair shall be performed primarily. In complex chronic ankle instabilities or failure of the Broström-Gould repair an anatomic non-arthroscopic tendon transfer or tendon graft reconstruction is recommended. Minimal invasive procedures are preferred when an accurate anatomical repair or reconstruction can be accomplished. Prior ankle arthroscopy enables to identify intraarticular lesions. Aim of all conservative and surgical treatment procedures is to provide functional and mechanical stability of the ankle.

## REFERENCES

- Krips R, de Vries J, van Dijk CN. Ankle instability. *Foot Ankle Clin.* 2006; 11: 311-329.
- Hamilton WG. Current concepts in the treatment of acute and chronic lateral ligament instability. *Sports Medicine and Arthroscopic Review.* 1994; 2: 264-271.
- Mc Cullough CJ, Burge PD. Rotatory stability of the load-bearing ankle. An experimental study. *J Bone Joint Surg Br.* 1980; 62-B: 460-464.
- Simon SR, Alaranta H, An K. Kinesiology. In: *Orthopaedic basic science.* Boston: American Academy of Orthopaedic Surgeons. 2000; 797-800.
- Scranton PE, Mc Dermott JE, Rogers JV. The relationship between chronic ankle instability and variations in mortise anatomy and impingement spurs. *Foot Ankle Int.* 2000; 21: 657-664.
- Mc Dermott JE, Scranton PE, Rogers JV. Variations in fibular position, talar length, and anterior talofibular ligament length. *Foot Ankle Int.* 2004; 25: 625-629.
- Tabrizi P, Mc Intyre WM, Quesnel MB, Howard AW. Limited dorsiflexion predisposes to injuries of the ankle in children. *J Bone Joint Surg Br.* 2000; 82: 1103-1106.
- Van Bergeyk AB, Younger A, Carson B. CT analysis of hindfoot alignment in chronic lateral ankle instability. *Foot Ankle Int.* 2002; 23: 37-42.
- Prins JG. Diagnosis and treatment of injury to the lateral ligament of the ankle. A comparative clinical study. *Acta Chir Scand Suppl.* 1978; 486: 3-149.
- Karlsson J, Lansinger O. Lateral instability of the ankle joint. *Clin Orthop Relat Res.* 1992; 253-261.
- Hopkinson WJ, St Pierre P, Ryan JB, Wheeler JH. Syndesmosis sprains of the ankle. *Foot Ankle.* 1990; 10: 325-330.
- van Dijk CN. CBO-guideline for diagnosis and treatment of the acute ankle injury. National organization for quality assurance in hospitals. *Ned Tijdschr Geneesk.* 1999; 143: 2097-2101.
- Hintermann B. Medial ankle instability. *Foot Ankle Clin.* 2003; 8: 723-738.
- Guillo S, Bauer T, Lee JW, Takao M, Kong SW, Stone JW, et al. Consensus in chronic ankle instability: Aetiology, assessment, surgical indications and place for arthroscopy; *Orthopaedics & Traumatology: Surgery & Research.* 2013; 99: 411-419.
- Fridén T, Zätterström R, Lindstrand A, Moritz U. A stabilometric technique for evaluation of lower limb instabilities. *Am J Sports Med.* 1989; 17: 118-122.
- Pijnenburg AC, Van Dijk CN, Bossuyt PM, Marti RK. Treatment of ruptures of the lateral ankle ligaments: a meta-analysis. *J Bone Joint Surg Am.* 2000; 82: 761-773.
- Tourne Y, Besse JL, Mabit C, Sofcot. Chronic ankle instability. Which tests to assess the lesions? Which therapeutic options? *Orthop Traumatol Surg Res.* 2010; 96: 433-446.
- Safran MR, Zachazewski JE, Benedetti RS, Bartolozzi AR, Mandelbaum R. Lateral ankle sprains: a comprehensive review part 2: treatment and rehabilitation with an emphasis on the athlete. *Med Sci Sports Exerc.* 1999; 31: 438-447.
- Freeman MA, Dean MR, Hanham IW. The etiology and prevention of functional instability of the foot. *J Bone Joint Surg Br.* 1965; 47: 678-685.
- Thonnard JL, Plaghki L, Willems P, Benoit JC, De Nyer J. Pathogenesis of ankle sprain: testing of a hypothesis. *Acta Belg Med Phys.* 1986; 9: 141-145.
- Kerkhoffs GM, Rowe BH, Assendelft WJ, Kelly KD, Struijs PA, van Dijk CN. Immobilisation for acute ankle sprain. A systematic review. *Arch Orthop Trauma Surg.* 2001; 121: 462-471.
- Karlsson J, Lansinger O. Lateral instability of the ankle joint (1). Non-surgical treatment is the first choiced 20 per cent may need ligament surgery. *Lakartidningen.* 1991; 88: 1399-1402.
- Fumich RM, Ellison AE, Guerin GJ, Grace PD. The measured effect of taping on combined foot and ankle motion before and after exercise. *Am J Sports Med.* 1981; 9: 165-170.
- Jerosch J, Schoppe R. Midterm effects of ankle joint supports on sensori motor and sport-specific capabilities. *Knee Surg Sports Traumatol Arthrosc.* 2000; 8: 252-259.
- Mickel TJ, Bottoni CR, Tsuji G, Chang K, Baum L, Tokushige KA. Prophylactic Bracing Versus Taping for the Prevention of Ankle Sprains in High School Athletes: A Prospective, Randomized Trial. *J Foot Ankle Surg.* 2006; 45: 360-365.
- Cordova ML, Scott BD, Ingersoll CD, LeBlanc MJ. Effects of ankle support on lower-extremity functional performance: a meta-analysis. *Med Sci Sports Exerc.* 2005; 37: 635-641.
- Papadopoulos E, Karzis K, Tsakoniti K, Karteroliotis K, Athanasopoulos S. The immediate effect of ankle bracing, head extension and vision on single limb balance. In: *Proceedings of the 7<sup>th</sup> Congress of the European College of Sport Science.* 2002; 868.
- Heit EJ, Lephart SM, Rozzi SL. The effect of ankle bracing and taping on joint position sense in the stable. *J Sport Rehabil.* 1996; 5: 206-213.
- Feuerbach JW, Grabiner MD, Koh TJ, Weiker GG. Effect of an ankle orthosis and ankle ligament anesthesia on ankle joint proprioception. *Am J Sports Med.* 1994; 22: 223-229.
- Cordova ML, Ingersoll CD. Peroneus longus stretch reflex amplitude increases after ankle brace application. *Br J Sports Med.* 2003; 37: 258-262.
- Dizon JM, Reyes JJ. A systematic review on the effectiveness of external ankle supports in the prevention of inversion ankle sprains among elite and recreational players. *J Sci Med Sport.* 2010; 13: 309-317.
- Attia M, Taher MF. A wearable device for monitoring and prevention of repetitive ankle sprain. *Conf Proc IEEE Eng Med Biol Soc.* 2015; 2015: 4667-4670.
- Broström L. Sprained ankles: a pathologic, arthrographic and clinical

- study [doctoral dissertation]. Stockholm: Karolinska Institute. 1966.
34. Gould N, Seligson D, Gassman J. Early and late repair of lateral ligament of the ankle. *Foot Ankle*. 1980; 1: 84-89.
  35. Karlsson J, Bergsten T, Lansinger O, Peterson L. Reconstruction of the lateral ligaments of the ankle for chronic lateral instability. *J Bone Joint Surg Am*. 1988; 70: 581-588.
  36. Segesser B, Goesele A. Weber fibular ligament-plasty with plantar tendon with Segesser modification. *Sportverletz Sportschaden*. 1996; 10: 88-93.
  37. Jeys LM, Harris NJ. Ankle stabilization with hamstring autograft: a new technique using interference screws. *Foot Ankle Int*. 2003; 24: 677-679.
  38. Coughlin MJ, Schenck RC, Grebing BR, Treme G. Comprehensive reconstruction of the lateral ankle for chronic instability using a free gracilis graft. *Foot Ankle Int*. 2004; 25: 231-241.
  39. Youn H, Kim YS, Lee J, Choi WJ, Lee JW. Percutaneous lateral ligament reconstruction with allograft for chronic lateral ankle instability. *Foot Ankle Int*. 2012; 33: 99-104.
  40. Wang B, Xu XY. Minimally invasive reconstruction of lateral ligaments of the ankle using semitendinosus autograft. *Foot Ankle Int*. 2013; 34: 711-715.
  41. Karlsson J, Bergsten T, Lansinger O, Peterson L. Lateral instability of the ankle treated by the Evans procedure. A long-term clinical and radiological follow-up. *J Bone Joint Surg Br*. 1988; 70: 476-480.
  42. Krips R, Brandsson S, Swensson C, van Dijk CN, Karlsson J. Anatomical reconstruction and Evans tenodesis of the lateral ligaments of the ankle. Clinical and radiological findings after follow-up for 15 to 30 years. *J Bone Joint Surg Br*. 2002; 84: 232-236.
  43. Hawkins RB. Arthroscopic stapling repair for chronic lateral instability. *Clin Podiatr Med Surg*. 1987; 4: 875-883.
  44. Lui TH. Arthroscopic-assisted lateral ligamentous reconstruction in combined ankle and subtalar instability. *Arthrosc J Arthrosc Relat Surg*. 2007; 23: 554.e1-e5.
  45. Kashuk KB, Landsman AS, Werd MB, Hanft JR, Roberts M. Arthroscopic lateral ankle stabilization. *Clin Podiatr Med Surg*. 1994; 11: 407-423.
  46. Matsui K, Burgesson B, Takao M, Sones J, Guillo S, Glazebrook M, et al. Minimally invasive surgical treatment for chronic ankle instability: a systematic review. *Knee Surg Sports Traumatol Arthrosc*. 2016; 24: 1040-1048.
  47. de Vries JS, Krips R, Blankevoort L, Fievez AW, van Dijk CN. Arthroscopic capsular shrinkage for chronic ankle instability with thermal radiofrequency: prospective multicenter trial. *Orthopedics*. 2008; 31: 655.
  48. Priano F, Gatto P. Arthroscopic reconstruction of inveterate anterior talofibular ligament tears. Notes on the technique employed and the short-term results. *J Sports Traumatol Relat Res*. 1994; 16: 97-104.
  49. Guillo S, Archbold P, Perera A, Bauer T, Sonnery-Cottet B. Arthroscopic anatomic reconstruction of the lateral ligaments of the ankle with gracilis autograft. *Arthroscopy Tech*. 2014; 3: 593-598.
  50. Prissel MA, Roukis TS. All-inside, anatomical lateral ankle stabilization for revision and complex primary lateral ankle stabilization: a technique guide. *Foot Ankle Spec*. 2014; 7: 484-491.
  51. Schmid T, Zurbriggen S, Zderic I, Gueorguiev B, Weber M, Krause FG. Ankle joint pressure changes in a pes cavovarus model: supramalleolar valgus osteotomy versus lateralizing calcaneal osteotomy. *Foot Ankle Int*. 2013; 34: 1190-1197.
  52. Jung HG, Kim TH, Park JY, Bae EJ. Anatomic reconstruction of the anterior talofibular and alcano fibular ligaments using a semitendinosus tendon allograft and interference screws. *Knee Surg Sports Traumatol Arthrosc*. 2012; 20: 1432-1437.
  53. Xu X, Hu M, Liu J, Zhu Y, Wang B. Minimally invasive reconstruction of the lateral ankle ligaments using semitendinosus autograft or tendon allograft. *Foot Ankle Int*. 2014; 35: 1015-1021.

#### Cite this article

Bäcker H, Krause FG, Attinger MC (2017) Treatment of Chronic Lateral Ankle Instability - A Review. *JSM Foot Ankle* 2(1): 1018.