

## Short Communication

# A Short Screening of Tattoo Marks amongst Drug Addicts

Saurabh Bhargava and Rajvinder Singh\*

Department of Genetics, Maharshi Dayanand University, India

## \*Corresponding author

Rajvinder Singh, Assistant Professor in Forensic Science, Department of Genetics, Maharshi Dayanand University, Rohtak, Haryana-124001, India, Tel: 91-9896398962; Fax: 01262-274640; Email: rvsforensic@gmail.com

Submitted: 30 October 2015

Accepted: 07 January 2016

Published: 08 January 2016

ISSN: 2378-9476

Copyright

© 2016 Singh et al.

OPEN ACCESS

## Keywords

- Tattoo mark
- Forensic science
- Medicolegal
- Drug addict

## Abstract

Practice of imprint tattoo on human body has been witnessed since ancient time. The glimpse of tattoos on human body may be substantially and logical connected with different trends. The practice of tattooing human body undertakes for a number of reasons. During autopsy, a forensic pathologist generally looks for and records tattoos marks in the same way as for any other body marks that could be identified like scars or birthmarks. Sometimes, the location and nature of the tattoo may validate identity of the missing person. Present pilot study has screened tattoos in fifty male subjects with drug abuse history. Aim of this research work was to investigate possible symbolic nature of tattoo with drug abused. Conversation with the subjects disclosed their connection with drug abused. This study has also inferred probable association of substances abused and typical tattoo design.

## INTRODUCTION

A tattoo is a design imprinted onto the skin that can sometimes be a useful mark of identification and lifestyle of an individual. An increase in the popularity of tattooing in the young population in western countries has been seen in past few years [1]. Although tattoos were once found predominantly amongst sailors, soldiers and prostitutes, this situation has changed with a large number of individuals having tattoos that show considerable variation in style and content [2]. Forensically, the tattoos have been suggested very useful in assisting with body identification if physical appearance or fingerprints are spoiled. Decedent's history may also be inferred from certain rudimentary line tattoos with antisocial and anti-police messages in ex-prisoners, syringes, marihuana leaves or mushrooms in illicit drug users. Tattoos on body in different forms of designs may provide additional basis in personal identification, religion, culture, life-style, region, history, war, occupation, sex interest, gang members and drug abuse [3-13]. A tattoo is made by inserting dye or inks on body with the help of a needle. To draw near conclusion to identifying the body is to extract a tiny amount of the dye or pigments and later analysis by techniques such as atomic absorption spectroscopy or thin layer chromatography that may trace back to a specific tattoo artist [14]. A tattoo may be an indicator of a person's history of drug abuse. In an important study tattoos were found related to drug use [15-23]. Problem of drug abuse is becoming very dangerous for the youth of this area. Purpose of this study was simply to screen the usual drug addicted by the individuals based on the tattoo trends amongst them. It can reflect the abuse of a particular drug in any area, especially while covering studies under drugs of abuse in forensic science. Rohtak is a small town and tattoo trend as fashion is uncommon here. Even there is no

published literature available from Rohtak Therefore, the aim of this study was to make a record of the different types of tattoo marks from the body of male adults involved in drug abuse activities in and around the Rohtak city of Haryana.

There are no female sex workers or other female groups ever reported or came into limelight from Rohtak city, therefore the emphasis of this study revolves around males only. No exact data on drug abused in Rohtak city was available yet so this study was conducted.

## MATERIALS AND METHODS

Fifty male subjects age between 18-35 years who ever had the history of drug abuse, having a background of drug abuse and tattooed bodies were inspected during March-April, 2014 from Rohtak city and the surrounding localities. There is no report of female drug addict from Rohtak city so the focus of research was on males only. Most of these subjects were linked with rehabilitation centers, gymnasium, sports complexes and hostels etc. During interviews the subjects were also asked about history and timing of tattooing engraved on bodies and their relationship if any, with the substance abused. The focus was to find out any valid connection between drug abused and tattoos imprinted on the body. For the sake of anonymity of the subjects, only tattooed portion of their body was sketched for research purpose. This is a short study so neither number nor any formula was fixed for small sample size from Rohtak city. Subjects were randomly selected. There was face to face interview with the consent of subjects. No questionnaire was designed only important aspects related to drug abuse and tattoo relation with that were considered.

## RESULTS

Variety of tattoo marks were observed on different body

parts of the subjects. It was observed that most of the tattoos were engraved on the upper limbs (fingers, hands, wrist, forearm, upper arm). Some subjects were also seen having with at least one tattoo imprinted on the lateral region of the neck. Tattooed shoulders were also in fashion. Twenty four subjects confessed use of steroids for the purposes of bodybuilding and athletics. Most of them had at least one *lion* tattoo of different style (Figure 1a,1b) commonly imprinted on the shoulder, the outer sides of biceps and on pectoral side. Symbols of lion eventually portray aggression and strength. These types of symbols have been seen on the body of body builders mostly associated with steroid abuse. Twenty two subjects also disclosed of being cannabis and other narcotic drug abuser. In some cases the bodies of these subjects were also ornamented with multiple tattoos. Tattoo marks in form of 'Eagle' (Figure 2a, 2b) were mostly observed in the subjects. Tattoos of 'Eagle', the celestial symbols of strength and maximum damage can be justified in the body. Likewise, an eagle is famous for its ability to fly high mountains and for silently swooping into the valleys among the abusers as a symbol of unchallenged free spirit. Use of initial letter of the names of the subjects was also seen in some cases. One of the Interesting observations was a change in the pattern of the initial letter before and after the influence of drugs. Tattoos made after the start of the drug abuse were found to be more bold and stylish than the simpler tattoo somewhere made before the start of drug abuse in the same subject. A subject had imprinted initial letters of his name and surname on his forearm before he was under the influence of drugs. After being under the influence drugs he imprinted same letters again but in different style this time (Figure 3a, 3b) on both sides of his neck. Some uncommon use of abstract and dragon tattoos (Figure 4a, 4b) were also found on the bodies of the drug addicts. Abstraction tattoos were mostly seen on the back side of the body.




Figure 1 Different styles of lion tattoos.

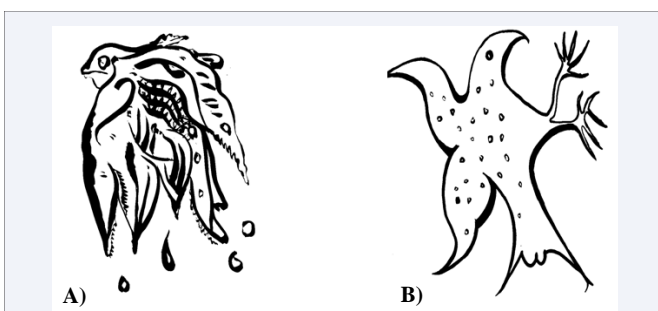


Figure 2 Different styles of Eagle tattoos.




Figure 3 Initial letter 'S' and 'M' in tattoo form (Before and after).




Figure 4 Types of abstract and dragon tattoo.

## CONCLUSIONS

Benefit of this study can be taken by the forensic anthropologists and forensic psychologists. Even the forensic drug related studies can also be started after reviewing the trend of drug abused in any particular area. The observations of this study support considerable connection between tattoo images and drug addicts. This study can be taken a hypothetical attempt unless until more subjects addicted to cocaine, amphetamines, heroin and other hallucinogens are reviewed. Therefore, it is suggested that there is needs of extensive research on this topic before reaching to the theorization that a tattoo on the body of a drug abuser can be used as a marker for determining the type of drug abused by the abuser.

## REFERENCES

1. Roberts TA, Ryan SA. Tattooing and high-risk behavior in adolescents. *Pediatrics*. 2002; 110: 1058-1063.
2. Caplan J. 'Speaking scars': the tattoo in popular practice and medico-legal debate in nineteenth-century Europe. *Hist Workshop J*. 1997; 107-142.
3. Cains G, Byard RW. The forensic and cultural implications of tattooing. In: Tsokos M, editor. *Forensic Pathology Reviews*, Vol. 5. Totowa: Humana Press; 2008:197-220.
4. Prahlow J, Byard RW. *An atlas of forensic pathology*. New York: Springer Publishers; 2012.
5. Byard RW, Winskog C. Potential problems arising during international disaster victim identification (DVI) exercises. *Forensic Sci Med Pathol*. 2010; 6: 1-2.
6. Coppleston VM. *Shark attack*. Melbourne: Pacinc Books. 1986: 14-22.
7. Byard RW. Tattoos: forensic considerations. *Forensic Sci Med Pathol*. 2013; 9: 534-542.
8. Rodrigues EJ, Fernandes AV, Benaulikar SS, Kamat GS, Kantak M.

- Tattoo marks. *J Forensic Med Toxicol*. 2005; 22:1-3
9. Kosut M. An ironic fad: The commodification and consumption of tattoos. *Journal of Popular Culture*. 2006; 39:1035-48.
  10. Doss K, Ebesu Hubbard AS. The communicative value of tattoos: The role of public self-consciousness on tattoo visibility. *Communication Research Reports*. 2009; 26:62-74.
  11. Mallon W, Russel M. Clinical and Forensic significance of tattoos. *Topographical Emergency medicine* 1999; 21:2129.
  12. Birx HJ. *Encyclopedia of Anthropology*, SAGE Publications, Inc. 2006
  13. Mackay J. *Forensic Art (Crime Scene Investigations)*, Lucent, Gale, Cengage Learning USA, 2009.
  14. Lerner KL, Lerner BW. *World of Forensic Science, Tattoo Identification*. Thomson Gale, 2005.
  15. Bitensky V, Khersonsky B, Dvoryak S, Glushkov V. Drug addiction in adolescents. Kiev: Zdorov'ya, 1989 (in Russian).
  16. Bennahum DA. Tattoos of heroin addicts in New Mexico. *Rocky Mt Med J*. 1971; 68: 63-66.
  17. Borokhov A, Popov T, Tumasov S, Gofman V, Vostrikov V. The significance of tattoos as a marker of self-destructive behaviour in adolescence and youths. In: Popov Y, Lichko E, editors. *Self-destructive behaviour in adolescence*. Leningrad: The Bekhterev Institute, 1991:107-112.
  18. Drews DR, Allison CK, Probst JR. Behavioral and self-concept differences in tattooed and nontattooed college students. *Psychol Rep*. 2000; 86: 475-481.
  19. Braithwaite R, Robillard A, Woodring T, Stephens T, Arriola KJ. Tattooing and body piercing among adolescent detainees: relationship to alcohol and other drug use. *J Subst Abuse*. 2001; 13: 5-16.
  20. Carroll ST, Riffenburgh RH, Roberts TA, Myhre EB. Tattoos and body piercings as indicators of adolescent risk-taking behaviors. *Pediatrics*. 2002; 109: 1021-1027.
  21. Brooks TL, Woods ER, Knight JR, Shrier LA. Body modification and substance use in adolescents: is there a link? *J Adolesc Health*. 2003; 32: 44-49.
  22. Borokhov A, Bastiaans R, Lerner V. Tattoo designs among drug abusers. *Isr J Psychiatry Relat Sci*. 2006; 43: 28-33.
  23. Brown E. *Tattoo Ideas: The Ultimate Guide To Tattoo Shops, Perfect Tattoo, Tattoo Art and Much More*. J Clinic Patho. 2014.

**Cite this article**

Bhargava S, Singh R (2016) A Short Screening of Tattoo Marks amongst Drug Addicts. *Ann Forensic Res Anal* 3(1): 1024.