

Research Article

Treatment of Humerus Diaphyseal Fractures with Minimally Invasive Plate Osteosynthesis

Madhura Kulkarni*, Vidisha Kulkarni, and Sujay Kulkarni

Department of Orthopaedics, Postgraduate Institute of Swasthiyog Pratisthan Miraj, India

*Corresponding author

Madhura Kulkarni, Postgraduate Institute of Swasthiyog Pratisthan Miraj, Maharashtra, Pin Code: 416410, India, Tel: 91-9922-009-981; Email: drmsk18@gmail.com

Submitted: 23 October 2017

Accepted: 15 December 2017

Published: 18 December 2017

Copyright

© 2017 Kulkarni et al.

OPEN ACCESS

Keywords

- Humerus
- MIPO
- Exfix assisted
- Anterior bridge plating

Abstract

Introduction: Humerus fractures remain to be in the spectrum of multiple treatments. With the evolution of surgical care, newer methods of treating humerus fractures are coming to light, most important being minimally invasive plate osteosynthesis (MIPO). MIPO has discreet advantages with regards to minimal dissection, preservation of fracture biology and rotator cuff, and providing stability with elasticity to the bone plate construct. It is evident that biological fixation is superior to mechanical fixation, which forms the basis of MIPO.

The aim of our study was to evaluate the functional and radiological outcome of MIPO.

Materials and methods: 33 cases were studied over 2 years. Closed and open fractures, polytrauma patients, unstable fractures were included in the study. Pathological fractures, non-unions and malunions, refracture, and patients presenting after a delay of 21 days were excluded. 8 cases were aided by external fixators. Patients were followed up with UCLA and MEPS scores.

Results: 100 % union was seen in our series with an average union time of 10.94 ± 2.4 weeks. Majority of the cases had excellent UCLA shoulder score and MEP scores. The 3 cases of post traumatic radial nerve palsy recovered after surgery. Mean angulations of 6.09° was seen postoperatively. Infection was seen in 2 cases which resolved later.

Conclusion: MIPO brings out a balance in fracture stability and biology preservation. It is thus a very novel and successful way of treating humerus with careful patient selection and mastering the art of this surgery.

ABBREVIATIONS

MIPO: Minimally Invasive Plate Osteosynthesis; IMN: Intramedullary Nailing; ORPO: Open Reduction Plate Osteosynthesis; UCLA: University of California; Los Angeles; MEPS: Mayo Elbow Performance Score

INTRODUCTION

The fractures of shaft humerus constitute around 1-2 % of all fractures in the human body and 14% of the entire humerus fractures [1]. These fractures are caused by direct or indirect trauma, ground level falls, road traffic accidents, with osteoporosis contributing to the intensity of the injury [2,3]. Radial nerve injury is most commonly encountered during diaphysis fractures on account of its anatomy.

Many methods, both surgical and nonsurgical have been developed to manage these fractures with a new method of Minimally Invasive Plate Osteosynthesis being currently studied [3,4].

As the surgical practices are evolving, more importance is now given to soft tissues, and fracture hematoma which are major factors in fracture healing.

MIPO is a non-extensile surgical method of fixing the fracture by preserving the fracture biology. Thus the stripping of tissues is prevented as well as the rotator cuff is spared from iatrogenic trauma [5].

The goal of treatment is to reduce the fracture, maintain reduction in proper alignment, length and rotation and facilitate early joint movement.

The aim of this study was to evaluate the new MIPO technique based on clinical radiological and functional outcomes.

The hypothesis to be tested in this study is that MIPO is a good method of treating humerus diaphysis fractures with regard to clinical and functional outcomes.

MATERIALS AND METHOD

This is an observational prospective study conducted at our institute from May 2014 to May 2016. A total of 33 patients were studied in this time frame. All patients were informed about the study and informed consent was obtained. Patients with diaphyseal fractures of humerus AO/OTA type A B C, open fractures type 1,2 and 3A 3B; polytrauma patients; unstable humerus fractures; age more than 18 years and patients in

whom conservative management had failed were included in the study [6-9]. Patients having pathological fractures; open type 3C injuries; septic or aseptic nonunion of humerus; refractures of humerus and patients presenting with a delay of 21 days were excluded from the study [10]. In case of pathological fracture, manipulation of fracture fragments may cause further fracture, thus excluded from the study. In nonunion whether septic or aseptic, exploration of the fracture site is necessary and closed procedure should be avoided. Fractures in patients who presented with a delay of 21 days or more, demand an open procedure as it is difficult to attain reduction with the soft tissue interpositions and callus. Open trauma requires thorough debridement for which opening of fracture site is necessary and is thus excluded from our study. After thorough examination of the patient surgery was performed using the following method [11-13] shown in Figure 1.

In supine position with shoulder abducted 90° and elbow extended and supinated, two anterior incisions were taken. The distal incision was taken 4 cm from the elbow crease being 5-7 cm in length. Plane was developed by retracting the biceps medially and visualizing the brachialis and musculocutaneous nerve. The brachialis was split in the middle and the anterolateral surface of humerus is exposed. Routinely the radial nerve was not dissected but in certain cases of distal shaft fractures, it was necessary. Proximally Coracoid process of the scapula is palpated and an incision 5-6 cm vertically was made 5 cm inferior to it. Deltopectoral plane was used to approach upper end of humerus. Certain fibers of pectoralis major and deltoid were released for better plate positioning.

In cases where external fixator was applied to the humerus, two small incisions were taken on the lateral aspect of the humerus, on the medial epicondyle and proximal humerus. Care was taken not to injure the axillary nerve by proximal pin. 4 mm schanz pins were inserted and fracture reduced under image intensifier guidance and external rod applied, as shown in Figure 2.

From the distal to the proximal incision a tunnel was made sub-muscularly by a tunneling instrument, forceps or in our case a 4.5mm locking plate. Locking plate was used for its obvious advantages [14-19].

The plate is passed close to the bone and exited from the proximal site. Under the image intensifier the plate is positioned on the anterior surface of the bone and temporarily fixed by 2 1.2 mm K-wires in each segment, as shown in Figure 3.

The reduction is checked under image intensifier. The elbow is flexed at 90° to relax the brachialis muscle, aiding the reduction.

Reduction being a blind procedure here, the step sign used by Krettek et al., in distal femur was used to maintain rotation and alignment [20].

In each segment a cortical screw was inserted and then the K-wires removed. A total of 3 locking head screws per fragment were inserted thus making the construct not too rigid [3,11,14,21].

Patients were started on postoperative antibiotics for a total of 3 days. Physiotherapy was started on day 3 as the pain

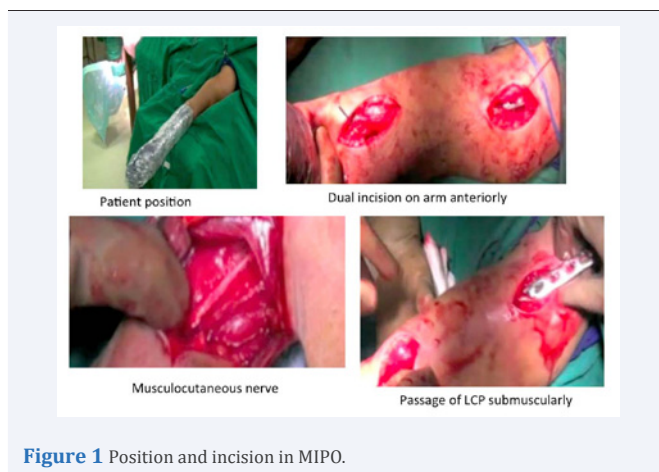

Figure 1 Position and incision in MIPO.

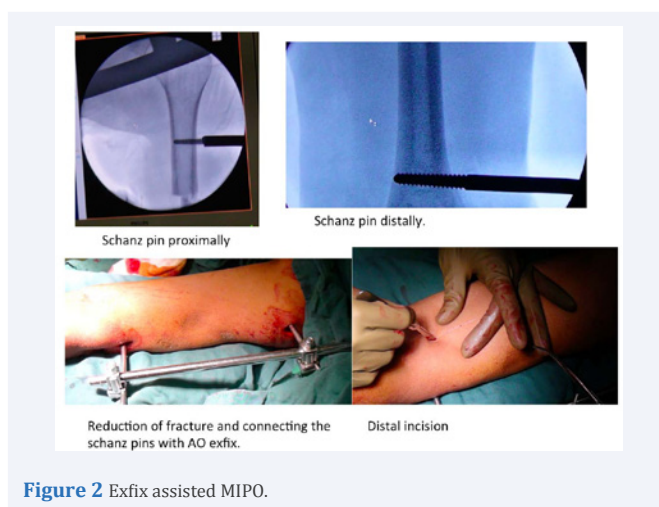


Figure 2 Exfix assisted MIPO.

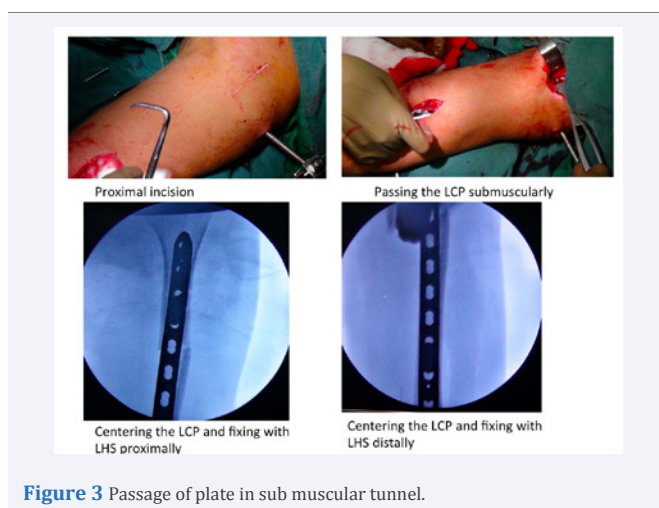


Figure 3 Passage of plate in sub muscular tunnel.

permitted. Patients were followed up every 15 days for 2 months then monthly. During the post-operative follow-up, UCLA and MEP scores were assessed for shoulder and elbow function respectively.

Union time was determined on visualizing at least 3 cortices on anteroposterior and lateral radiographs of the humerus.

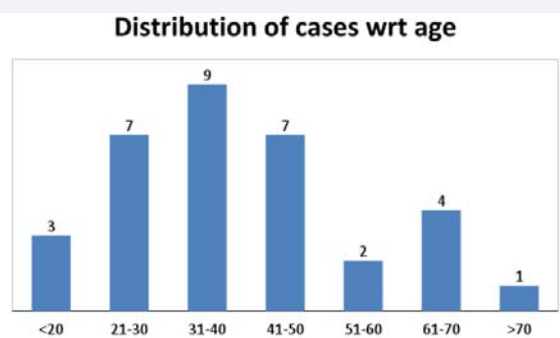


Figure 4 Age wise distribution of cases.

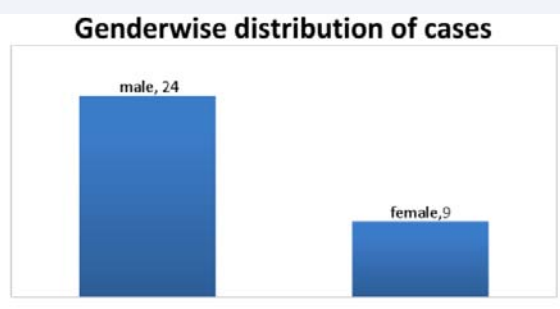


Figure 5 Sex wise distribution of cases.

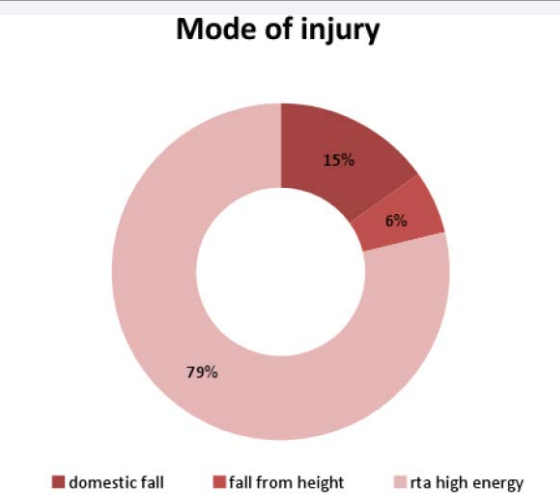


Figure 6 Mode of injury in humerus fractures (rt a-road traffic accident).

RESULTS

The study included 33 patients within the age group of 16 years to 77 years (mean 40.5 ± 16 years), of whom all were available for follow up (Figure 4). The study has taken place from May 2014 to May 2016,

There were 24 males and 9 female patients as depicted below in Figure 5.

Out of the 33 cases, majority (90.9%) were closed fractures while the remaining 3 (9.1%) cases were open fractures.

Maximum numbers of cases were due to road traffic accidents (79%) as shown in Figure 6. This was followed by domestic fall and fall from height.

As shown in the Figure 7 maximum cases fall in the 12 A3 type, followed by A1, A2 and B1. Time between admission and surgery ranged from 1 to 8 days with mean time of 3.6 ± 1.8 days and mean hospital stay lasted for 10.52 ± 5 days.

Appearance of Callus ranged from 4 weeks to 18 weeks with average at 10.94 ± 2.4 weeks, with 100% union in our series. Union time was expressed in weeks and ranged from 12 weeks to 30 weeks as shown below in Figure 8. It was observed that union time was less than 20 weeks for 81% (27/33) cases. Average

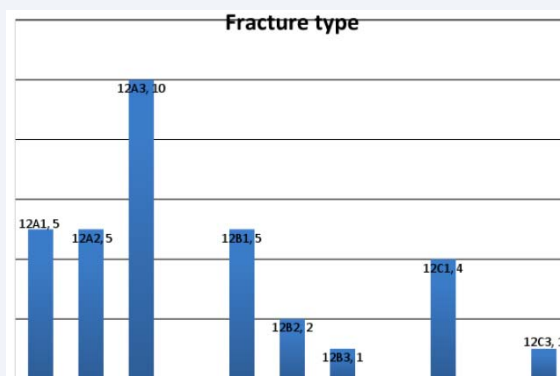


Figure 7 Case distribution according to fracture type.

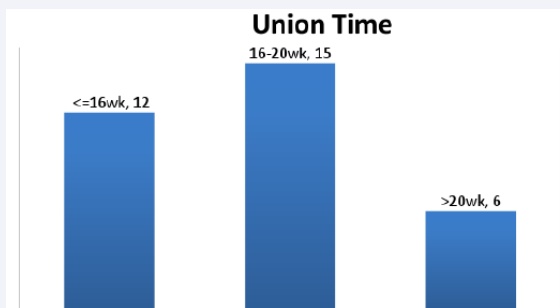


Figure 8 Union time.

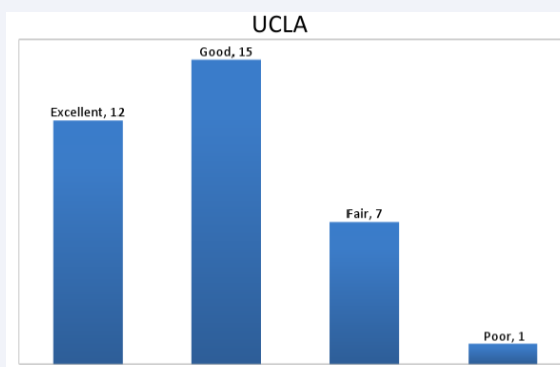
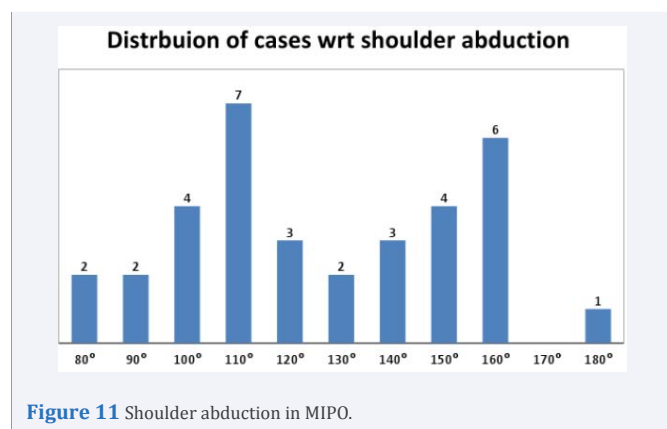
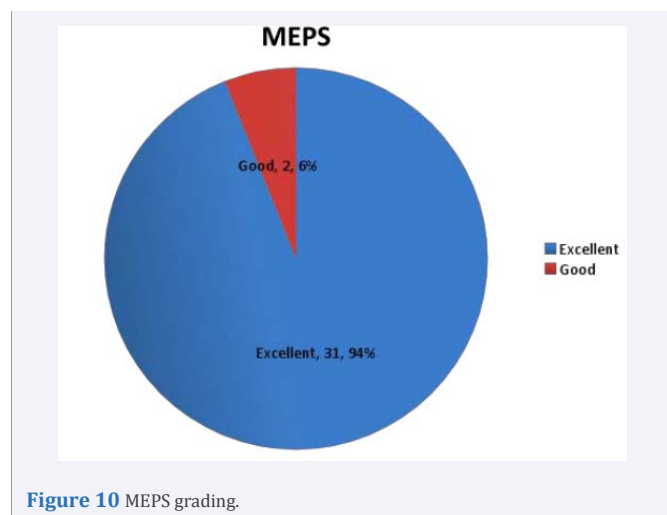


Figure 9 UCLA grading in MIPO follow-up.



union time was 18.3 ± 2.4 weeks.

UCLA score is graded as excellent if it is more than 27 and poor if it is less. It was observed that majority of the cases had excellent or good UCLA, with an average of 18.3 ± 4.0 shown in Figure 9. Only 1 case had a poor score.

MEP score is graded as excellent more than 90, good from 75-89, fair from 60-74 and poor less than 60. 2 cases had less than excellent MEP score, while the rest had excellent score, shown in Figure 10.

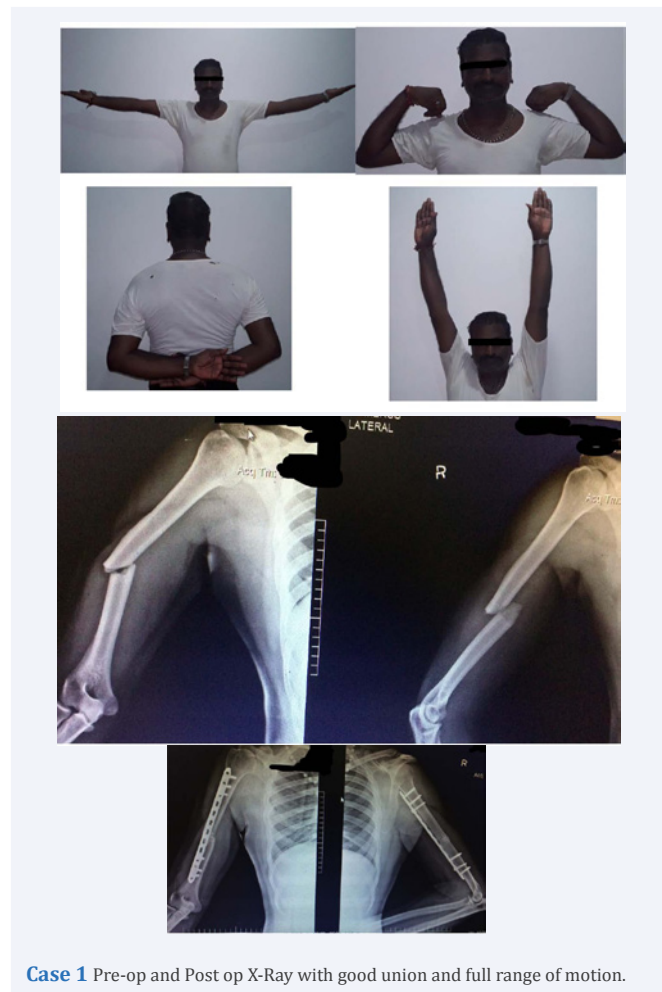The means of the shoulder movement is given below in Table 1. Only 8 patients had shoulder abduction less than 110 degrees shown in Figure 11. The elbow range of motion ranged from least of 100 to maximum of 140 degrees depicted in Table 2.

Some cases had flexion deformity owing to the brachialis injury while fixation of the fracture. It was intermittent and recovered in a few months. The mean of flexion deformity was of 3.03°

There were 17 cases which required less than 120 minutes for surgery, while 16 cases required more. Mean surgical time was $116 \text{ min} \pm 17 \text{ min}$ depicted in Table 3.

COMPLICATIONS

There were 2 cases (Case 1 and 2) in which infection was



detected. Both the cases had a compound injury. The infection was dealt with repeated debridement and antibiotic bead insertion, responding with total elimination of infection.

We had 4 cases of intraoperative radial nerve injury that recovered postoperatively. One case of intraoperative radial nerve injury occurred while placing the schanz pin, which recovered.

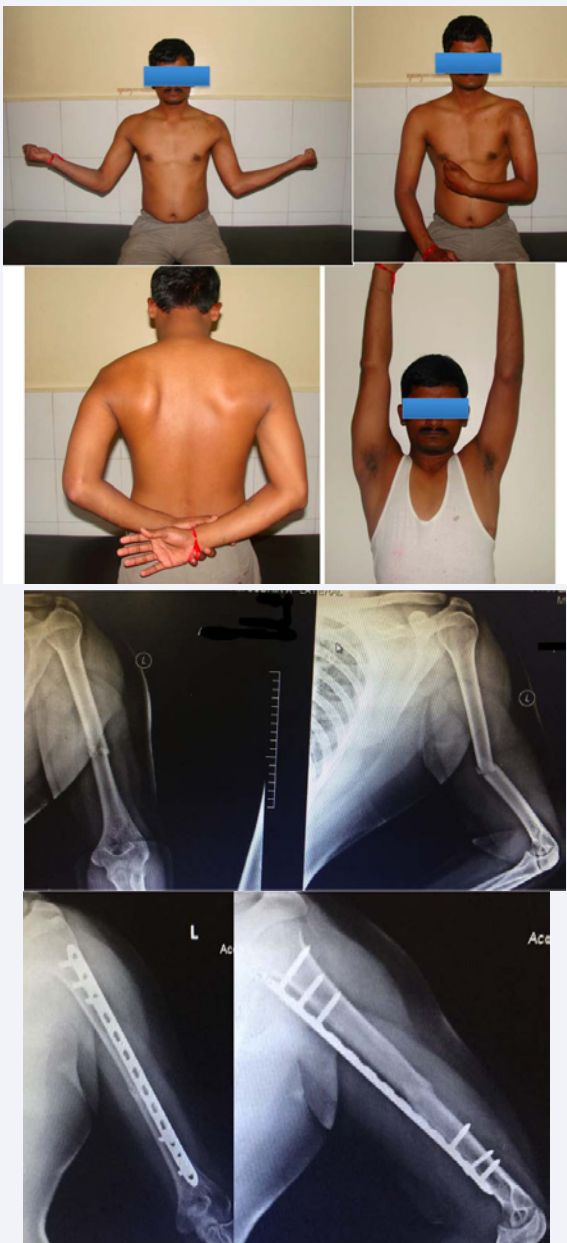One patient had elbow stiffness. It resolved completely after removal of splint used for forearm injury.

Thus the complication rate was 12% (4/33). The valgus and varus angulation was calculated on the AP and lateral X-rays and shown as follows in Table 4.

DISCUSSION

Humerus fractures till recent years have been treated by a number of ways ranging from bracing to Ilizarov ring fixators [2]. Currently intramedullary nailing (IMN), open reduction plate osteosynthesis (ORPO), Enders nails are most widely used. It has been observed by many studies that AO/OTA type A fractures and long oblique fractures do not respond well to nonsurgical treatment [3,22,23]. Surgery has been instituted in patients for better rehabilitation and early joint mobility [5,10,24].

In this era of minimally invasive surgery, soft tissue



Case 2 40 year old man with MIPO technique with good range of motion.

importance has increased tremendously. MIPO was first developed for its use in tibia and femur [25], and was popularized for humerus by Apivatthakakul in 2005(5). It revolves around the principle proposed by Hunter and Haller that bone healing occurs in response to vascular injury around the fracture site [26].

MIPO bridge plating uses the plate as an extramedullary splint, fixing the two main fragments while the intermediate zone is left untouched. Anatomical reduction of the fracture is not necessary. Direct manipulation of the fragments risks the blood supply [27]. As the soft tissues are preserved and fragments relatively aligned, healing is predictable [11]. Humerus tolerates 10-20 degrees of sagittal plane deformity and up to 30 degree of rotational deformity.

The vascular anatomy of humerus is favorable for MIPO with respect to the constancy of nutrient artery [27-29].

According to the principles of working length, MIPO can be used for diaphyseal humerus fractures with proximal and distal extensions. This has been shown successfully by multiple publications by Apivatthakakul et al., Zhiquan An et al., Wang et al., Shetty et al., and many more [12,21,30-35].

A newer development in MIPO was devised by Lee et al., who used intraoperative external fixator to guide the fracture reduction [36]. This aided easier reduction and faster operative time. We operated 8 such cases with positive results.

Certain complications are associated with this procedure as it has a lengthy learning curve [37]. The surgical time required in our series had a mean of 116 ± 17 mins.

MIPO can be successfully used in post traumatic radial nerve palsy, with gradual recovery seen post operatively [38,39]. It has been seen in 3 of our cases.

The radial nerve is closely related to the humerus. The study by Apivatthakakul describes the danger zones in screw placement in MIPO [40]. Radial nerve damage can occur in this procedure during manipulation more than during screw placement. We had 4 cases of intraoperative nerve palsy, and neuropraxia recovered soon after.

During surgery as the brachialis is handled, elbow function can be stiffened, but generally improves with physiotherapy. Mild Malunion is evident, as the fracture is reduced indirectly. In open fractures, it is mandatory to treat the wound else leading to infection, which may lead to implant failure and nonunion. In our study, there were 2 infected cases but no event of nonunion occurred.

Many studies comparing MIPO with other traditional methods

Table 1: range of motion of shoulder joint.

Shoulder movement	Range(degrees)	Mean \pm sd (degrees)
abduction	80-180	126.36 ± 26.55
Forward flexion	80-180	110.91 ± 21.12

Table 2: Elbow movement in MIPO.

Elbow	Range	Mean \pm sd
flexion	100-140	115.75 ± 13.46
Flexion deformity	0-20	3.03 ± 5.4

Table 3: surgical time required in MIPO.

No. of cases	Surgical time
17	< 120 mins
16	> 120 mins

Table 4: angulation in the follow up cases.

Angulation	Range	Mean \pm sd
anteroposterior	0-18°	$4.94 \pm 4.3^\circ$
varus angulation	0-20°	$6.09 \pm 4.7^\circ$

like IMN ORPO, detailed the distinct advantages of this minimally access surgery [8,41-47].

Studies by Baltov et al., and Ikpeme et al., enumerated that rotator cuff damage can occur with IMN, by the protrusion of the nail and collection of reamed debris underneath the cuff [48,49]. Also distraction at the fracture site can occur owing to the flattened anatomy of the distal humerus, leading to nonunion. ORPO involves stripping of the periosteum and devitalizing the tissues, leading to excessive blood loss, scarring and nonunion [41,44].

MIPO involves minimal blood loss, preservation of fracture biology and is a more cosmetic procedure. Considering the advantages and drawbacks of all procedures, MIPO emerges as a better option with regard to patient function and radiological outcome.

CONCLUSION

MIPO merits an overwhelming advantage compared to other conventional methods. Thus the proper selection of patients, the learning curve of the surgery, and the surgeon's acumen play an important role in successful outcome following MIPO of shaft humerus. The hypothesis of our study is accepted.

ACKNOWLEDGMENTS

I would like to thank Dr. Prasad Pawar, our physiotherapist for rehabilitation and Mrs. Swati Raje for analyzing my data.

REFERENCES

- Sen'ko EI, Kudriavtsev VP. [Treatment of diaphyseal fractures of the humerus and the leg bones]. *Khirurgiia (Mosk)*. 1989; 1: 13-14.
- Ekholm R, Adami J, Tidermark J, Hansson K, Törnkvist H, Ponzer S. Fractures of the shaft of the humerus. An epidemiological study of 401 fractures. *J Bone Joint Surg Br*. 2006; 88: 1469-1473.
- Garnavos C. Humerus shaft fractures. rockwood and greens fractures in adults. 2015.
- Balfour GW, Mooney V, Ashby ME. Diaphyseal fractures of the humerus treated with a ready-made fracture brace. *J Bone Joint Surg Am*. 1982; 64: 11-13.
- Apivatthakakul T, Arpornchayanon O, Bavornratanavech S. Minimally invasive plate osteosynthesis (MIPO) of the humeral shaft fracture. Is it possible? A cadaveric study and preliminary report. *Injury*. 2005; 36: 530-538.
- Zogbi DR, Terrivel AM, Mouraria GG, Mongon ML, Kikuta FK, Filho AZ. Fracture of distal humerus: MIPO technique with visualization of the radial nerve. *Acta Ortop Bras*. 2014; 22: 300-303.
- Reignier M, el Banna S, Hayez JP, Stelmazyk J, Raynal P. [Osteosynthesis of diaphyseal fractures of the humerus]. *Acta Orthop Belg*. 1987; 53: 485-491.
- Singiseti K, Ambedkar M. Nailing versus plating in humerus shaft fractures: a prospective comparative study. *Int Orthop*. 2010; 34: 571-576.
- Jahn R, Schenk E, Berger I. [Indications for surgical management of humerus diaphyseal fractures and results]. *Zentralbl Chir*. 1989; 114: 222-227.
- Zhang W, Zeng L, Liu Y, Pan Y, Zhang W, Zhang C, et al. The mechanical benefit of medial support screws in locking plating of proximal humerus fractures. *PLoS One*. 2014; 9: e103297.
- Pol Rommens PT. MIO approach for shaft humerus fractures.
- Ziran BH, Belangero W, Livani B, Pesantez R. Percutaneous plating of the humerus with locked plating: technique and case report. *J Trauma*. 2007; 63: 205-210.
- Ziran BH, Kinney RC, Smith WR, Peacher G. Sub-muscular plating of the humerus: an emerging technique. *Injury*. 2010; 41: 1047-1052.
- Gardner MJ, Griffith MH, Demetrakopoulos D, Brophy RH, Grose A, Helfet DL, et al. Hybrid locked plating of osteoporotic fractures of the humerus. *J Bone Joint Surg Am*. 2006; 88: 1962-1967.
- Greive RM, Archdeacon MT. Locking plate technology: current concepts. *J Knee Surg*. 2007; 20: 50-55.
- Roderer G, Erhardt J, Kuster M, Vegt P, Bahrs C, Kinzl L, et al. Second generation locked plating of proximal humerus fractures--a prospective multicentre observational study. *Int Orthop*. 2011; 35: 425-432.
- Roderer G, Gebhard F, Krischak G, Wilke HJ, Claes L. Biomechanical in vitro assessment of fixed angle plating using a new concept of locking for the treatment of osteoporotic proximal humerus fractures. *Int Orthop*. 2011; 35: 535-541.
- Dickson KF, Munz J. Locked Plating: Clinical Indications. *Tech Orthop*. 2007; 22: 181-185.
- Sutherland GB, Creekmore T, Mukherjee DP, Ogden AL, Anissian L, Marymont JV. Biomechanics of humerus fracture fixation by locking, cortical, and hybrid plating systems in a cadaver model. *Orthopedics*. 2010; 33.
- Krettek C, Miclau T, Grün O, Schandelmaier P, Tschernhe H. Intraoperative control of axes, rotation and length in femoral and tibial fractures. Technical note. *Injury*. 1998; 29: C29-39.
- Shetty MS, Kumar MA, Sujay K, Kini AR, Kanthi KG. Minimally invasive plate osteosynthesis for humerus diaphyseal fractures. *Indian J Orthop*. 2011; 45: 520-526.
- Rutgers M, Ring D. Treatment of diaphyseal fractures of the humerus using a functional brace. *J Orthop Trauma*. 2006; 20: 597-601.
- Decomas A, Kaye J. Risk factors associated with failure of treatment of humeral diaphyseal fractures after functional bracing. *J La State Med Soc*. 2010; 162: 33-35.
- Sarmiento A, Horowitz A, Aboulaia A, Vangsness CT Jr. Functional bracing for comminuted extra-articular fractures of the distal third of the humerus. *J Bone Joint Surg Br*. 1990; 72: 283-287.
- Krettek C, Müller M, Miclau T. Evolution of minimally invasive plate osteosynthesis (MIPO) in the femur. *Injury*. 2001; 32: SC14-23.
- Marzona L, Pavolini B. Play and players in bone fracture healing match. *Clin Cases Miner Bone Metab*. 2009; 6: 159-162.
- Gardner MJ, Voos JE, Wanich T, Helfet DL, Lorch DG. Vascular implications of minimally invasive plating of proximal humerus fractures. *J Orthop Trauma*. 2006; 20: 602-607.
- Laing PG. The arterial supply of the adult humerus. *J Bone Joint Surg Am*. 1956; 38-A: 1105-1116.
- Khimenko MF, Chaichenko VP, Malakhov AI. [Blood supply of the humerus and treatment of its diaphyseal fractures by transosseous osteosynthesis]. *Ortop Travmatol Protez*. 1984; 11: 27-30.
- Zhiqian A, Bingfang Z, Yeming W, Chi Z, Peiyan H. Minimally invasive plating osteosynthesis (MIPO) of middle and distal third humeral shaft fractures. *J Orthop Trauma*. 2007; 21: 628-633.
- Yang T, Liu S, Liu Y. [Minimally-invasive locking compression plate to treat complex humeral shaft fracture]. *Zhongguo Xiu Fu Chong Jian*

- Wai Ke Za Zhi. 2007; 21: 817-819.
32. Apivatthakakul T, Phornphutkul C, Laohapoonrungrsee A, Sirirungruangsarn Y. Less invasive plate osteosynthesis in humeral shaft fractures. *Oper Orthop Traumatol*. 2009; 21: 602-613.
 33. Wang C, Li J, Li Y, Dai G, Wang M. Is minimally invasive plating osteosynthesis for humeral shaft fracture advantageous compared with the conventional open technique?. *J Shoulder Elbow Surg*. 2015; 24: 1741-1748.
 34. Concha JM, Sandoval A, Streubel PN. Minimally invasive plate osteosynthesis for humeral shaft fractures: are results reproducible? *Int Orthop*. 2010; 34: 1297-1305.
 35. Mahajan AS, Kim YG, Kim JH, D'sa P, Lakhani A, Ok HS. Is Anterior Bridge Plating for Mid-Shaft Humeral Fractures a Suitable Option for Patients Predominantly Involved in Overhead Activities? A Functional Outcome Study in Athletes and Manual Laborers. *Clin Orthop Surg*. 2016; 8: 358-366.
 36. Lee HJ, Oh CW, Oh JK, Apivatthakakul T, Kim JW, Yoon JP, et al. Minimally invasive plate osteosynthesis for humeral shaft fracture: a reproducible technique with the assistance of an external fixator. *Arch Orthop Trauma Surg*. 2013; 133: 649-657.
 37. Park J, Jeong SY. Complications and outcomes of minimally invasive percutaneous plating for proximal humeral fractures. *Clin Orthop Surg*. 2014; 6: 146-152.
 38. Shao YC, Harwood P, Grotz MR, Limb D, Giannoudis PV. Radial nerve palsy associated with fractures of the shaft of the humerus: a systematic review. *J Bone Joint Surg Br*. 2005; 87: 1647-1652.
 39. Pailhe R, Mesquida V, Rubens-Duval B, Saragaglia D. Plate osteosynthesis of humeral diaphyseal fractures associated with radial palsy: twenty cases. *Int Orthop*. 2015; 39: 1653-1657.
 40. Apivatthakakul T, Patiyasikan S, Luevitoonvechkit S. Danger zone for locking screw placement in minimally invasive plate osteosynthesis (MIPO) of humeral shaft fractures: a cadaveric study. *Injury*. 2010; 41: 169-172.
 41. Hadhoud M, Darwish A, Mesriga M. Minimally invasive plate osteosynthesis versus open reduction and plate fixation of humeral shaft fractures. *Menoufia Medical Journal*. 2015; 28: 154-161.
 42. Davies G, Yeo G, Meta M, Miller D, Hohmann E, Tetsworth K. Case-Match Controlled Comparison of Minimally Invasive Plate Osteosynthesis and Intramedullary Nailing for the Stabilization of Humeral Shaft Fractures. *J Orthop Trauma*. 2016; 30: 612-617.
 43. Modabber MR, Jupiter JB. Operative management of diaphyseal fractures of the humerus. Plate versus nail. *Clin Orthop Relat Res*. 1998; 347: 93-104.
 44. Changulani M, Jain UK, Keswani T. Comparison of the use of the humerus intramedullary nail and dynamic compression plate for the management of diaphyseal fractures of the humerus. A randomised controlled study. *Int Orthop*. 2007; 31: 391-395.
 45. Aksu N, Karaca S, Kara AN, Isiklar ZU. Minimally invasive plate osteosynthesis (MIPO) in diaphyseal humerus and proximal humerus fractures. *Acta Orthop Traumatol Turc*. 2012; 46: 154-160.
 46. Hu X, Xu S, Lu H, Chen B, Zhou X, He X, et al. Minimally invasive plate osteosynthesis vs conventional fixation techniques for surgically treated humeral shaft fractures: a meta-analysis. *J Orthop Surg Res*. 2016; 11: 59.
 47. Ouyang H, Xiong J, Xiang P, Cui Z, Chen L, Yu B. Plate versus intramedullary nail fixation in the treatment of humeral shaft fractures: an updated meta-analysis. *J Shoulder Elbow Surg*. 2013; 22: 387-395.
 48. Baltov A, Mihail R, Dian E. Complications after interlocking intramedullary nailing of humeral shaft fractures. *Injury*. 2014; 45: S9-S15.
 49. Ikpeme JO. Intramedullary interlocking nailing for humeral fractures: experiences with the Russell-Taylor humeral nail. *Injury*. 1994; 25: 447-455.

Cite this article

Kulkarni M, Kulkarni V, Kulkarni S (2017) Treatment of Humerus Diaphyseal Fractures with Minimally Invasive Plate Osteosynthesis. *J Fract Sprains* 1(1): 1007.