

Case Report

Report a Case of Huge Zenker's Diverticulum with Date Nucleuses Impaction in and with Aspiration Pneumonia

Manouchehr Aghajanzadeh^{1*}, Amine Shafaroudi², and Rassol Hassanzadeh³

¹Department of Internal Medicine, Guilan University of Medical Sciences, Iran

²Department of Gastroenterology, Arya Private Hospital, Iran

³Student Research Committee, Guilan University of Medical Sciences, Iran

***Corresponding author**

Manouchehr Aghajanzadeh, Department of Internal Medicine, Inflammatory Lung Disease Research Center, Razi Hospital, School of Medicine, Guilan University of Medical Sciences, Rasht, Iran, Tel: 981 13155 50028; Email: Maghajanzadeh2003@yahoo.com

Submitted: 28 June 2017

Accepted: 18 September 2017

Published: 21 September 2017

Copyright

© 2017 Aghajanzadeh et al.

OPEN ACCESS**Keywords**

• Huge zenker's; Dysphagia; Pneumonia; Date nucleuses impaction

Abstract

A Zenker's diverticulum is the rarest type of gastrointestinal diverticulum and is located immediately above the upper esophageal sphincter and typically presents in the elderly population with dysphagia regurgitation, halitosis, and malnutrition. Here we report cases of large Zenker's diverticula with malnourished secondary to dysphagia, regurgitation, hoarseness, or halitosis, profound weight loss, anemia, cough and aspiration pneumonia. She underwent an open resection of the Zenker's diverticulum and myotomy and discharged with good condition.

INTRODUCTION

Zenker's diverticulum (ZD) is a pulsion diverticulum of the upper esophagus. ZD arises from a weakness in the posterior esophageal wall (Killian's triangle), bound laterally by the oblique fibers of the thyropharyngeal muscle, which constitutes part of the inferior pharyngeal constrictor muscle, and inferiorly by the horizontal cricopharyngeal muscle. Although ZD was first described in 1769 [1], Increased intrapharyngeal pressure is the cause of pathophysiology of this disease [1,2]. The increased pressure is most frequently attributed to incomplete relaxation of the upper esophageal sphincter causing a high pressure zone within the hypopharynx [1,3]. Other abnormalities in upper esophageal sphincter function such as uncoordinated contraction and premature contraction and relaxation have also been postulated as potential causes of this increased pressure [1]. The ranges of incidence are from 0.01% to 0.11% [1,2]. Most Patients complain of regurgitation, hoarseness and halitosis. The most common complaint in 80 to 90% of people is dysphagia [1-3]. As the diverticulum progressively enlarges, symptoms may worsen leading to profound weight loss and malnutrition [1,2,4]. Approximately 30 to 40% of these patients may also present with persistent cough and aspiration, with a few even having aspiration pneumonia [2-4]. More severe symptoms such as pain or bleeding, although uncommon in ZD, have been reported. The development of squamous cell cancer which has an incidence of 0.4 to 1.5 [2-4]. Due to its posterior location, it is important to obtain lateral views of the esophagogram so as not to miss the ZD [5]. The dissection is carried down through the deep cervical fascia to the pre vertebral fascia taking care not to injure the

recurrent laryngeal nerve in the tracheoesophageal groove. At this point the pharyngeal pouch is dissected and the cricopharyngeal myotomy is performed along the posterolateral portion of the cervical esophagus for a length of 4 cm [1,2]. The diverticulum is then dissected down to its base and divided with a linear stapler. The platysma is then closed over a linear drain which is removed postoperatively after a contrast swallow study [1,2,4]. The endoscopic treatment of ZD entails division of the septum between the diverticulum and the esophagus which also contains the cricopharyngeal muscle [6-8]. This method functionally joins the lumen of the diverticulum with that of the esophagus, thereby relieving the symptoms of dysphagia without actually resecting the diverticulum. Consequently the diverticulum will continue to be visualized on radiographic examination.

CASE REPORT

A 76-year-old male patient presented with a history of progressive dysphagia for solids for a year, which evolved to dysphagia and odynophagia for liquids in 5 months. Other complaints were regurgitation, hoarseness and halitosis. The patient had lost 20 kg in 5 months. His current weight was 43 kg. The patient confirmed smoking habits (two packs of cigarettes). The patient was referred with esophageal obstruction and suspicion of neoplasia. Thoracic and abdomen CT scan: Patient underwent a barium swallow which showed a pouch like lesion in the cervical oesophagus as zenker's diverticulum. The CT scan also revealed an abrupt straightening of the proximal third of the esophagus (Figure 1). The patient, then, underwent upper GI endoscopy; the endoscope passed through the obstruction and identified the presence of a Zenker's diverticulum. Next, he

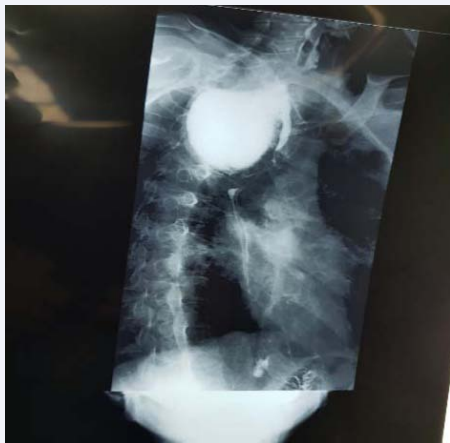

Figure 1 Anteroposterior esophagogram displaying the measures of the Zenker's diverticulum.

underwent through an another esophagogram that identified a large esophageal diverticulum (Figure 2, Figure 3). The patient positioned in a supine position with a small pillow under his shoulders and the head hyper extended and slightly turned to the right side. The operation performed under general anesthesia, the left later neck incision is made ventrally to the sternocleidomastoid muscle. Following division of the subcutaneous tissue and platysma, the pharynx and cervical oesophagus was exposed by retraction. The sternocleidomastoid and carotid sheath was retracted laterally and the larynx and thyroid gland medially. Once the pouch was identified and completely dissected from the surrounding loose connective tissue and the neck of the pouch displayed, myotomy of the cricopharyngeal muscle and proximal fibres of the oesophageal muscle was performed for a length of about 5 cm on the cervical oesophagus. Following myotomy, diverticulectomy was performed. Five days after her surgery, a barium swallow demonstrated normal swallowing function without evidence of esophageal leak or obstruction (Figure 1). Pathology demonstrated a 10 x 7 x 4cm diverticulum with two date nucleus in the diverticulum (Figure 4). The patient discharged with good conditions.

DISCUSSION

Zenker's diverticulum (ZD) is an acquired sac originating from the mucosa and submucosa layers of the pharyngo-esophageal junction and in the cervical esophagus. (ZD) typically present in elderly patients, especially during the seventh and eighth decades of life [4]. But age of our patients was less than other researches. Classical symptoms of (ZD) are progressive oropharyngeal dysphagia, regurgitation of food debris due to food retention, weight loss, chronic cough, chronic aspiration, halitosis, sensation of a lump in the throat. Hoarseness, whistling and cervical borborygmi are seen in some patients [1,2]. Our case present with dysphagia, regurgitation, weight loss, chronic cough, chronic aspiration, halitosis, hoarseness and aspiration pneumonia without neck lump. Complications of untreated ZD are diverticulitis, peptic ulceration, bleeding, iatrogenic perforations during passage of endoscopes or naso gastric tubes, fistulas, diverticulitis and vocal cord paralysis [2,3]. Cancer probably has rarely been reported in association with Zenker diverticula (ZD),

with an incidence of 0.5% [6]. A barium swallow study is the first and the mainstay tools in diagnosis of (ZD), which show the size and location of (ZD), but an esophagoscopy is mandatory to rule out the malignancy [2-5]. Our patient first underwent a barium swallow and next esophagoscopy to rule out malignancy, our cases underwent A CXR because of cough and showed aspiration pneumonia. Small asymptomatic diverticula do not need surgical treatment, because the risk of severe complications, cancer and aspiration is low [2-4,8]. Surgical Treatment indicated for all symptomatic (ZD). Open diverticulectomy with or without

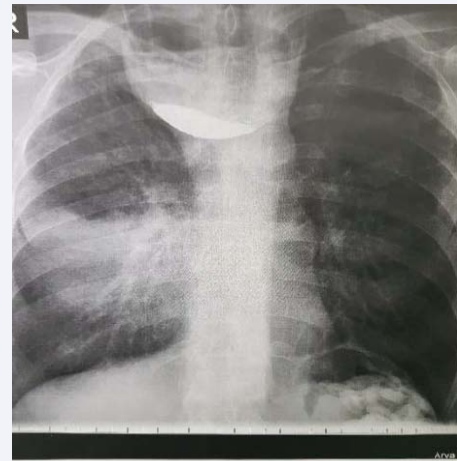


Figure 2 CXR show aspiration pneumonia of right lung with Zenker's diverticulum.

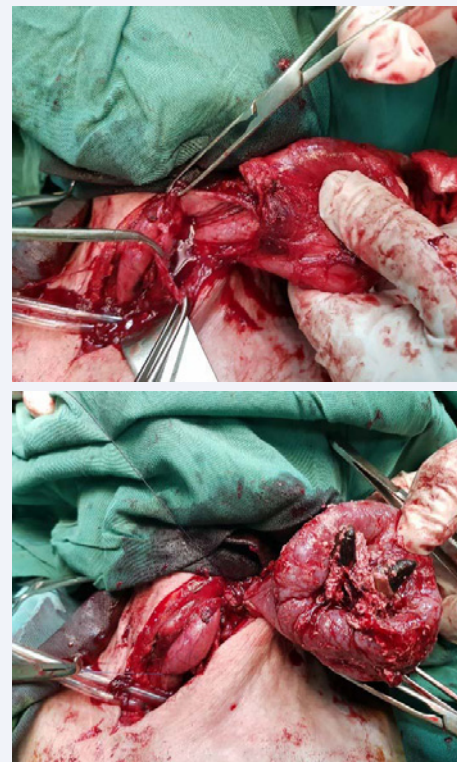


Figure 3 Zenker's diverticulum following diverticulectomy.

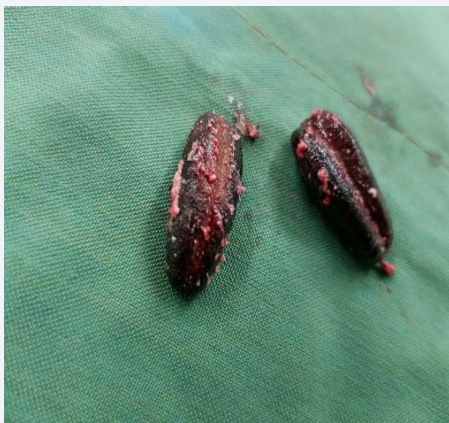

Figure 4 Two date nucleus in the Zenker's diverticulum.

myotomy or diverticulopexy, diverticular inversion and myotomy are Surgical procedures for ZD [1,3-5]. Endoscopic staple-assisted oesophago diverticulostomy, endoscopic CO₂-laser myotomy, Endoscopic harmonic scalpel diverticulotomy and flexible endoscopic diverticulotomy are New procedures for ZD [2,6,8-10] It is believed that myotomy should always be part of surgical procedures [2,7]. In our case we used open diverticulectomy with cricopharyngealmyotomy without any complication and recurrence. In medium sized diverticula (3-5cm). Endoscopic stapling diverticulotomy is better than others less invasive approaches [2,4]. In diverticula which longer than 6 cm represent a relative contraindication to endoscopic treatment because residual pouch may be too large to allow easy clearance of pouch during swallowing [1-4] Open surgical excision in very large diverticula may still be benefit, especially in younger, good surgical candidates as our cases [8,9]. Open surgical diverticulectomy with myotomy provides radicality, eliminating any theoretical risk of carcinoma and have a low morbidity , mortality and recurrences and outcome is good as our cases we have not any of this complications [2,4-6,8].

CONCLUSION

In a case with orophageal dysphagia, possibility of Zenker's

diverticulum should be in differentiated diagnosis of the cause of dysphagia. Rare presentation in ZD may occur. Barium swallow should be the first modality of investigation. Careful endoscopy should be carried out in confirming the diagnosis. In the symptomatic ZD the choice of treatment is surgery. The choice between open diverticulectomy and cricopharyngealmyotomy versus endoscopic treatment in ZD remains controversial. The choice of approach depends to surgeon, new instrument and the patient condition. The open procedure is our preferred choice.

REFERENCES

1. Salehomoum N, Chang E, Kahn S. Zenker's Diverticulum: Case Reports and Review of the Literature: Two Large Zenker's at a Single Institution. *Internet J of Surg.* 2010; 25.
2. Manouchehr A, Mashhoor MY, Adegh M, Delshad E, Massahnia S. Zenker's Diverticulum: Report Rare Presentation and Management of Six Cases. *Gastroenterol Hepatol Open Access.* 2016; 4.
3. Elbalal M, Mohamed AB, Hamdoun A, Yassin K, Miskeen E, Alla OF. Zenker's diverticulum: a case report and literature review. *Pan Afr Med J.* 2014; 17: 267.
4. Ferreira LE, Simmons DT, Baron TH. Zenker's diverticula: pathophysiology, clinical presentation, and flexible endoscopic management. *Dis Esophagus.* 2008; 21: 1-8
5. Klockars T, Sihvo E, Mäkitie A. Familial Zenker's diverticulum. *Acta Otolaryngol.* 2008; 128: 1034-1036.
6. Mantsopoulos K, Psychogios G, Künzel J, Zenk J, Iro H, Koch M. Evaluation of the different transcervical approaches for Zenker diverticulum. *Otolaryngol Head Neck Surg.* 2012; 146: 725-729.
7. Fama AF, Moore EJ, Kasperbauer JL. Harmonic scalpel in the treatment of Zenker's diverticulum. *Laryngoscope.* 2009; 119: 1265-1269.
8. Bonavina L, Rottoli M, Bona D, Siboni S, Russo IS, Bernardi D. Transoral stapling for Zenker diverticulum: effect of the traction suture-assisted technique on long-term outcomes. *Surg Endosc.* 2012; 26: 2856-2861.
9. Acharya A, Jennings S, Douglas S. Carcinoma arising in a pharyngeal pouch previously treated by endoscopic stapling. *Laryngoscope.* 2006; 116: 1043-1045
10. Dzeletovic I, Ekbohm DC, Baron TH. Flexible endoscopic and surgical management of Zenker's diverticulum. *Expert Rev Gastroenterol Hepatol.* 2012; 6: 449-465.

Cite this article

Aghajanzadeh M, Shafaroudi A, Hassanzadeh R (2017) Report a Case of Huge Zenker's Diverticulum with Date Nucleuses Impaction in and with Aspiration Pneumonia. *JSM Gastroenterol Hepatol* 5(3): 1087.