SciMedCentral

JSM Gastroenterology and Hepatology

Case Report

The Use of High Resolution Manometry in the Management of a Patient with Dysphagia Secondary to Laparoscopic Adjustable Gastric Band - A Case Study

Tracey Moran Brennan*

GI Physiology Unit, St James's Hospital, Ireland

***Corresponding author**

Tracey Moran Brennan, GI Physiology Unit, St James's Hospital, Dublin 8, Ireland, Tel: 00353-1-4162888; Email: tmoran@stjames.ie

Submitted: 19 May 2022

Accepted: 17 June 2022

Published: 18 June 2022

Keywords

- Laparoscopic adjustable gastric
- Band high resolution manometry
- Esophago-gastric junction

Abstract

A 46-year-old obese woman presented to the Gastroenterology clinic with symptoms of dysphagia, odynophagia, regurgitation and vomiting. She had a laparoscopic adjustable gastric band in situ for a period of 10 years and this was believed to be causing her troublesome symptoms. Barium swallow indicated a hold up of contrast at the esophago-gastric junction and in the gastric reservoir between the junction and the band. High Resolution Manometry could confirm the placement of the band and the dual high pressure zones of the esophago-gastric junction and the gastric band. An elevated Integrated Resting Pressure and intra-bolus pressure indicated a hold up of bolus and resistance to flow across the esophago- gastric junction and in the gastric reservoir. 12 months post laparoscopic band removal, High Resolution Manometry was repeated. This revealed normal esophageal motility, a relaxing esophago-gastric junction and normal bolus transit. The patient's symptoms improved greatly however her weight gain continued to be the cause of much stress to her and her options are under review. High Resolution Manometry is a useful tool in the assessment of patients with complicated gastric bands and is recommended both pre and post band placement or removal.

ABBREVIATIONS

LAGB: Laparoscopic Adjustable Gastric Ban; HRM: High Resolution Manometry; EGJ: Esophago-Gastric Junction

INTRODUCTION

The laparoscopic adjustable gastric band (LAGB) has been used in the treatment of morbid obesity for over 20 years. In the early days of its inception it seemed like the ideal surgical technique, as other bariatric surgeries for obesity at the time such as the Vertical Banded Gastroplasty and Roux-en-Y gastric bypass were open procedures that were seen as quite complicated. The LAGB was both adjustable and easily reversible and relied on the technique of inducing a sensation of fullness and thus forcing the patient to feel less and less hungry. However, over the years the gastric band has fallen out of favor. This is due to the high complication rates that accompany this technique [1]. Complications such as band slippage and erosion, esophageal dilatation and the effect on esophago-gastric junction (EGJ) function, have become more apparent, especially in patients who have had the gastric band in situ for many years.

There has been much controversy in the literature regarding the overall effect of the band on the physiology of the esophagus and the EGJ. With some authors arguing that there is a profound effect on function, others concluded that there was no real significant effect. However these studies based their findings on radiology alone or on stationary pull through manometry [2-4]. Stationary or conventional manometry was a four channel solid state or water perfused manometry technique which by todays standard does not give much information regarding EGJ morphology or bolus transit. Each channel is positioned 5cms apart and prone to axial displacement during swallow, which can often miss important information regarding LES relaxation.

High Resolution Manometry (HRM) is now considered the gold-standard in the assessment of esophageal motility. This technique utilizes 36 closely spaced recording sites that allow for a more detailed and dynamic assessment of esophageal and EGJ function. The data is displayed in the form of an isobaric contour plot which allows for a detailed assessment of the pressure dynamics across the EGJ taking into account esophageal shortening and the effect of crural diaphragm position relative to the lower esophageal sphincter high pressure zone [5-8].

In this case study I would like to demonstrate the clinical utility of HRM in the assessment and management of a patient with complications arising from a gastric band in situ for 10 years.

CASE PRESENTATION

A 46-year-old obese women with a BMI of >45kg/m^3, presented to the hospital with a 6-month history of severe dysphagia, odynophagia, post prandial regurgitation and vomiting. She was a non-smoker, drank alcohol occasionally and was in full time employment.

Medical history included pyloric stenosis as an infant, acid reflux, endometriosis and mild atrial regurgitation. The patient's surgical history included a LAGB and cystectomy for ovarian cysts. The patient's gastric band was in situ for 10 years prior to this presentation and needed revision after the first year of insertion. Over the course of 9 years post revision the patient did admit to bouts of intermittent dysphagia. During the last 12 months this began to increase, with symptoms becoming so severe in the last 6 months, that she felt food and liquid holding and regurgitating every time she ate.

She described bouts of being unable to swallow her own saliva. Her acid reflux was well controlled symptomatically with 40mg bd of Esomeprazole, prescribed by her GP. She was unsure about how long she had symptoms of reflux. There was no history of hematemesis. Physical exam revealed soft abdomen, with normal bowel sounds. There was weight loss of 22kg in 12 months, but she has, in general, struggled to lose weight with the Gastric Band.

Four months before her outpatient appointment the patient had an endoscopy which was ordered by her GP. Endoscopy at the time revealed the gastric band in situ with two small tongues of Barrett's mucosa at 1 and 3 o'clock with no circumferential involvement, Prague score C0M2. Bloods and abdominal ultrasound were normal. A barium swallow was ordered and HRM was suggested depending on the outcome of the barium.

Barium showed a hold up of contrast at the EGJ and into the gastric reservoir. The esophagus was dilated throughout its length and a delay in gastric emptying was noted (Figure 1).

High Resolution Manometry with Impedance, revealed essentially normal esophageal body peristalsis with dual high pressure zone (HPZ) at the level of the EGJ. In this case the dual HPZ indicated the separation between the EGJ and the gastric band. The patient had an Integrated Relaxation Pressure (IRP) of 22.5mmHg. (Normal IRP for Manoscan™ HRM <15mmHg). This elevated IRP indicated an outflow obstruction at the EGJ. The impedance signal showed poor bolus clearance and bolus entrapment which was due to the failure of the gastric band to open to allow the bolus to transit (Figure 2). Both multiple rapid swallow and bread bolus provocation studies confirmed bolus hold up. After consultation with the patient, the gastroenterology and surgical teams it was decided that the best treatment was to remove the gastric band and port to help preserve the motility of the esophagus.

Repeat manometry was carried out 12 months post operatively and this indicated a return to normal EGJ function with no evidence of outflow obstruction and preserved esophageal body peristalsis (Figure 3). The patient's last endoscopy did not indicate Barrett's but revealed a 2 cm Hiatus Hernia. The patient was advised to continue on PPI's and declined the offer of a 24 pH study to assess her reflux status. At her last outpatient appointment, the patient was feeling well with no melena or hematemesis, some dysphagia but very infrequently. Although the patient was given lifestyle advice she had gained 20kg since the surgery and now wanted to explore the option of gastric bypass surgery. A table of the timeline of the patient's care pathway is provided in the appendices (Table 1).

Figure 1 The barium image shows marked esophageal dilatation and hold up of the contrast in the reservoir created between the OGJ and the gastric band.

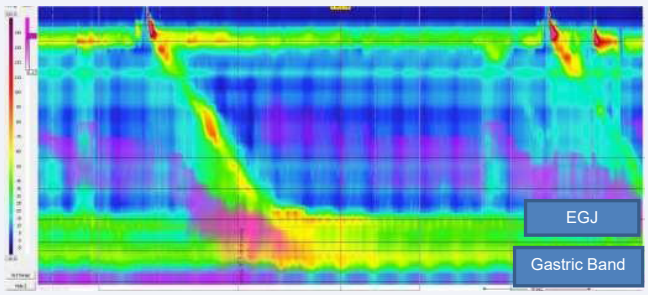

Figure 2 Pre- op High Resolution Manometry trace. The clip-out illustrates the distinct high pressure bands created by the EGJ and the gastric band. The pink impedance signal indicates the bolus entrapment between the High pressure zones and poor clearance of bolus from the esophageal body.

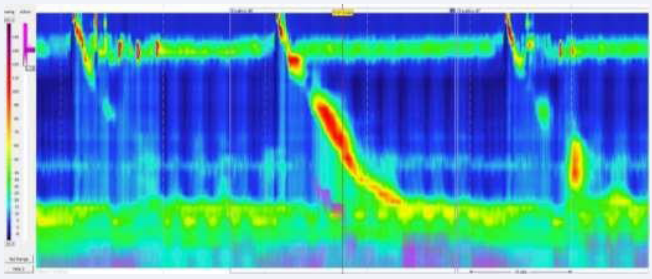

Figure 3 Post-op High Resolution manometry trace. Note there is now a single high pressure zone of the EGJ with normal bolus transit through the EGJ into the stomach.

DISCUSSION

It has been recognized that the LAGB can lead to various complications particularly on esophageal and EGJ function. In this case a middle aged female patient, with a gastric band in situ for 10 years, presented with symptoms of dysphagia, odynophagia, postprandial regurgitation and vomiting. The patient was obese with a BMI of >45kg/cm and had a history of acid reflux. Though complications of the gastric band may appear to be the main cause, other differential diagnosis needed to be ruled out. Reflux related complications such as peptic stricture, adenocarcinoma of the esophagus or gastric cardia, would have to be considered. Or possibly an underlying esophageal motility disturbance not identified pre LAGB. Many studies have shown a strong link between obesity and gastrointestinal disease from gastro esophageal reflux disease and motility disturbance to esophageal and gastric cancers [5,6].

Endoscopy with histology and a full blood work helped to rule out any sinister complications. Further testing with barium did indeed show a hold up of contrast at the EGJ and into the gastric reservoir.

However, barium did not give a lot of detail other than show that the flow of contrast was impeded and the esophagus dilated. With HRM however we can appreciate in more detail, the location of the gastric band, where it is relative to the EGJ and the overall effect it is having on motility.

High Resolution Manometry is a relatively new manometric technique used to assess esophageal motility and the function of the EGJ. In contrast to conventional manometry, HRM can record intraluminal esophageal pressures at much more closely spaced intervals with sensors spanning the length of the esophagus from pharynx to stomach. This arrangement of closely spaced sensors allows for more accurate data acquisition and generation of pressure topography plots. These pressure plots allow for the identification of the EGJ and clear assessment of esophageal function [7,8].

Esophageal pressure topography metrics are used in HRM as a means of measuring physiological function of the esophagus and the degree of relaxation of the EGJ. The IRP is a measure of mean EGJ pressure within a period of 4 seconds of maximal relaxation, in the 10-seconds after relaxation of the upper esophageal sphincter. The Distal Contractile Integral (DCI) is a measure of the amplitude x duration x length of the distal contractile segment and allows us to measure overall strength of the esophageal contraction. The Intra-bolus pressure (IBP) represents the degree of resistance to flow across the EGJ. This is assessed in conjunction with the IRP as an indicator of hold-up in the distal esophagus. The addition of impedance sensors to the HRM assembly can provide additional information on bolus-transit and regurgitation [7].

Though much research has been done on the effect of LAGB on esophageal motility, most of the findings have been based upon radiological studies alone or conventional manometry. Both of these techniques used alone have their limitations. With barium alone esophageal dilatation can be seen, as well as any hold up or aspiration of barium, but esophageal function, Lower Esophageal Sphincter (LES) attenuation or band pressure cannot be measured. As for conventional manometry alone, because these measurements produce a rudimentary line tracing it can be very difficult to distinguish the high pressure zone of the gastric band from the pressure zone of the LES. Also incomplete relaxation at the EGJ can be missed with standard manometry.

HRM results for this patient prior to band removal showed a dual high pressure zone. (Fig 2) The position of the gastric band in this case is distal to the EGJ and shows a prominent gap between the EGJ and the band. This sub-diaphragmatic enlargement of a gastric pouch between these two high pressure zones has been identified before in studies by Barton et al., [9]. The patient's barium study also confirmed this pouch formation. The tightness of the band would significantly affect the ability of this pouch to empty and also affect the flow across the EGJ. This was reflected in the high IRP and IBP values obtained in this study. Provocation studies using saline soaked bread, multiple rapid swallows and free drinking techniques all supported the diagnosis of hold up of bolus in the pouch area. The patient still had reasonably good esophageal function with only 40% of her swallows showing a DCI <450mmHg. The HRM trace after removal of the gastric band (Figure 3) shows a vast improvement to the patient's esophageal function with complete relaxation of EGJ, normal intra-bolus pressures and an improvement to esophageal body function with now only one swallow with DCI <450mmHg. A table of HRM results pre and post removal is supplied in the appendices (Table 1).

With this case study I wanted to highlight the importance of High Resolution Manometry in the investigation of patients who have had previous gastric banding. In this case HRM was only considered as an afterthought to the barium. Studies have shown that conventional contrast studies alone had missed abnormalities that manometry identified [9], therefore a combination of both should always be used to assess these patients [8].

Pre-operative assessment of esophageal function prior to placement of a gastric band has long been argued as essential and I would agree with this analysis [10]. Though gastric banding has fallen out of favor, some centers still provide this service and a preoperative assessment using HRM and if possible 24 hour pH studies, will help to ascertain if a patient has any

Table 1: High Resolution Manometry results pre and post band removal.

HRM Metrics	Pre LAGB Removal	Post LAGB Removal	Normal Ranges for the Manoscan™ HRM system
IRP (mmHg)	22.5	12.4	N < 15mmHg
IBP (mmHg)	27.8	19.9	N <17mmHg
% Contractions DCI<450mmHg-cm-s	40	20	DCI <450 ineffective <100 failed
Mean DCI mmHg-cm-s	722.3	1177.8	450-8000
% Incomplete Bolus Transit	100	0	n/a

Abbreviations: **IRP**: Integrated Relaxation Pressure, **IBP**: Intra-Bolus Pressure, **DCI**: Distal Contractile Integral.

underlying motility disturbance or GERD. Studies have shown a correlation between obesity and the presence of GERD and motility disturbances, generally ineffective motility. Obesity is also associated with an increase in separation between the crural diaphragm and the LES i.e. Hiatus Hernia, making these patients more susceptible to reflux [11,12]. As with any esophageal surgery whether for anti-reflux purposes, Heller's Myotomy or Peroral Endoscopic Myotomy (POEM), pre-operative High Resolution Manometry is an essential requirement for any procedure with a direct impact on esophageal motility. Though it is essential that HRM is carried out pre-operatively a limitation with the technique is that it is invasive and not available in all centers so access may be difficult, though I think every effort should be made to avail of the test.

Studies have shown the negative long term effects of LAGB on esophageal function, therefore I feel, we will over time be presented with more and more complicated cases [10]. HRM has an important role to play and every effort should be made to offer the patient an esophageal motility assessment as part of their work up.

There is a paucity of studies on this group of patients using HRM so with this case I hope to add to the growing appreciation for the diagnostic utility of High Resolution Manometry in these interesting cases.

It has long been demonstrated in other work that obesity is associated with upper GI disease therefore HRM should be considered for pre and post gastric band placement and when patients present with complications arising with the gastric band. This is even more essential if this patient is being considered for further surgical options. It ensures that any upper GI morbidities are ruled out before the patient even considers further bariatric surgery.

ACKNOWLEDGEMENTS

Thank you to Ms P Lawlor, Chief II GI Physiologist at St James's Hospital and Prof. N Ravi, Esophageal Surgeon, Surgical Department, St James's Hospital, Dublin for their ongoing support.

REFERENCES

1. Dargent J. Laparoscopic Gastric Banding: Game Over? Obes Surg. 2017; 27: 1914-1916.
2. Khan A, Ren-Fielding C, Traube M. Potentially Reversible Pseudoachalasia after Laparoscopic Adjustable Gastric Banding. J Clin Gastroenterol. 2011; 45: 775-779.
3. Naef M, Mouton WG, Naef U, van der Weg B, Maddern GJ, Wagner HE. Esophageal Dysmotility Disorders After Laparoscopic Gastric Banding-An Underestimated Complication. Ann Surg. 2011; 253: 285-290.
4. Korenkov M, Kohler L, Yucel N, Grass G, Sauerland S, Lempa M, et al. Esophageal motility and reflux symptoms before and after bariatric surgery. Obes Surg. 2002; 12: 72-76.
5. Tolone S, Limongelli P, del Genio G, Brusciano L, Rossetti G, Amoroso V, et al. Gastroesophageal reflux disease and obesity: Do we need to perform reflux testing in all candidates to bariatric surgery? Int J Surg. 2014; 12: S173-S177.
6. Olefson S, Moss SF. Obesity and related risk factors in gastric cardia adenocarcinoma. Gastric Cancer. 2015; 18: 23-32.
7. Fox M, Kahrilas PJ, Pandolfino JE, Zerbib F. Manual of High Resolution Esophageal Manometry. Ist Edition-Bremen; UNI-MED. 2014 edn: SCIENCE U-M. Editor. Europe: International Medical publishers. 2014. 1-171.
8. Cruiziat C, Roman S, Robert M, Espalieu P, Laville M, Poncet G, et al. High resolution esophageal manometry evaluation in symptomatic patients after gastric banding for morbid obesity. Dig Liver Dis. 2011; 43: 116-20.
9. Burton PR, Brown WA, Laurie C, Korin A, Yap K, Richards M, et al. Pathophysiology of Laparoscopic Adjustable Gastric Bands: Analysis and Classification Using High-Resolution Video Manometry and a Stress Barium Protocol. Obes Surg. 2010; 20: 19-29.
10. Tchokouani L, Jayaram A, Alenazi N, Ranvier GF, Sam G, Kini S. The Long-Term Effects of the Adjustable Gastric Band on Esophageal Motility in Patients Who Present for Band Removal. Obes Surg. 2018; 28: 333-7.
11. Pandolfino JE, El-Serag HB, Zhang Q, Shah N, Ghosh SK, Kahrilas PJ. Obesity: A challenge to esophagogastric junction integrity. Gastroenterology. 2006; 130: 639-49.
12. Tolone S, Savarino E, de Bortoli N, Frazzoni M, Furnari M, d'Alessandro A, et al. Esophagogastric junction morphology assessment by high resolution manometry in obese patients candidate to bariatric surgery. Int J Surg. 2016; 28: S109-S13.

Cite this article

Brennan TM (2022) The Use of High Resolution Manometry in the Management of a Patient with Dysphagia Secondary to Laparoscopic Adjustable Gastric Band - A Case Study. JSM Gastroenterol Hepatol 9(1): 1107.