

## Review Article

# Management of Rectal Prolapse – The State of the Art

Ortega AE\*, Cologne KG, and Lee SW

Division of Colorectal Surgery, Keck School of Medicine at the University of Southern California, USA

## \*Corresponding author

Adrian E. Ortega, Division of Colorectal Surgery, Keck School of Medicine at the University of Southern California, Los Angeles Clinic Tower, Room 6A231-A, LAC+USC Medical Center, 1200 N. State Street, Los Angeles, CA 90033, USA, Email: sccowboy78@gmail.com

Submitted: 22 November 2016

Accepted: 20 December 2016

Published: 04 January 2017

## Copyright

© 2017 Ortega et al.

## OPEN ACCESS

## Abstract

This manuscript reviews the current understanding of the condition known as rectal prolapse. It highlights the underlying patho physiology, anatomic pathology and clinical evaluation. Past and present treatment options are discussed including important surgical anatomic concepts. Complications and outcomes are addressed.

## INTRODUCTION

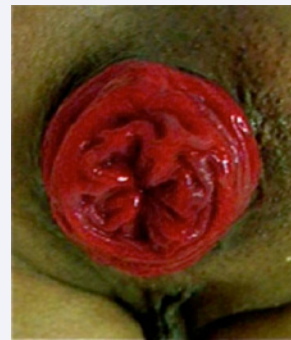Rectal prolapse has existed in the human experience since the time of antiquities. References to falling down of the rectum are known to appear in the Ebers Papyrus as early as 1500 B.C., as well as in the Bible and in the writings of Hippocrates (Figure 1) [1].

### Etiology

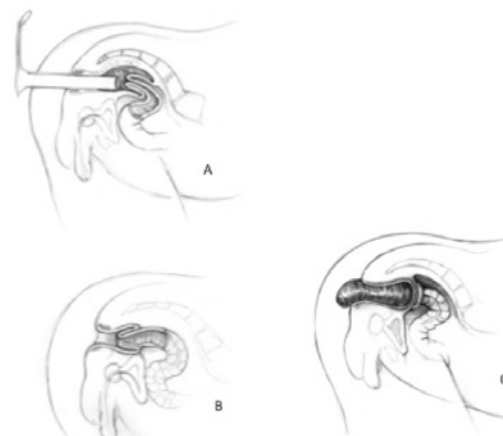
- The precise causation of rectal prolapse is ill defined. Clearly, five anatomic pathologic elements may be observed in association with this condition: Diastasis of the levator ani
- A deep cul-de-sac
- Ano-recto-colonic redundancy
- A patulous anus
- Loss of fixation of the rectum to its sacral attachments.

It is impossible to know which observations are causative versus secondary to the phenomenon of rectal prolapse proper.

The fundamental underlying mechanism of rectal prolapse has been speculated upon since the eighteenth century. Early surgical authors including Hunter, Von Hall and Morgagni proposed the intuitive assumption that prolapses was the result of ano-rectal-colonic intussusceptions [1]. Moschcowitz at the turn of the twentieth century proposed that rectal prolapse was a sliding hernia in the setting of a deep cul-de-sac [2]. Gant clearly describes the phenomena of anorectal and sigmoid-rectal intussusceptions in 1923 [3] (Figure 2). A no-rectal-colonic telescoping or intussusception was objectively proven as the underlying mechanism of rectal prolapse using cine-defecography by Broden and Snellman [4] in 1968. But perhaps Ripstein offered the most useful pathophysiologic construct in 1972: "A long mesorectum, congenital or acquired, results in straightening of the rectum and allows abdominal forces to be transmitted directly to the rectum." [5].



**Figure 1** A classic full-thickness rectal prolapse with the central "rosette" surrounded by circular folds of rectal mucosa.



**Figure 2** One of the earliest twentieth century American authors clearly depicted this understanding of rectal prolapse. It begins as an internal recto-rectal intussusception (a) and results in either anorectal prolapse (b) or colorectal prolapse through the anal canal (c). [Adapted figures from Samuel E. Gant, 1923].

Early writers commented on the propensity of rectal prolapse in nulliparous, older females. In the contemporary era, prolapse is theorized to be more common with hysterectomy, multiparity, aging, or other conditions that result in a relaxation or severing of the cardinal-uterosacral ligaments that provide support to the rectovaginal fascia [6]. Psychiatric illness is a well-known predisposing condition. Parasitosis has also been implicated with the initiation of prolapse in endemic regions of the world [7].

Associated symptoms may include

- Bleeding
- Mucorrhea
- Soilage
- Incontinence
- Tenesmus
- Pain

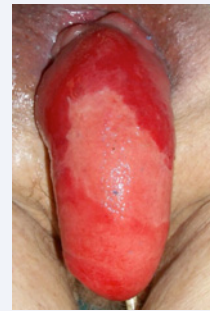Fecal incontinence is seen in three quarters of patients with rectal prolapse. Generally, three fourths of patients with incontinence improve following surgical correction of the prolapse. The same corollary does not apply to constipation. Surgery correcting rectal prolapse may in fact worsen constipation. Additional history related factors that should be noted include previous obstetric, gynecologic and surgical history--especially any prior prolapse repairs. Urologic complaints should be confirmed or excluded. Medication history is important as well. Systemic and psychiatric disease may be harbingers of a generalized degenerative constitution and may be risk factors for poorer outcomes following surgery [8].

### Physical examination

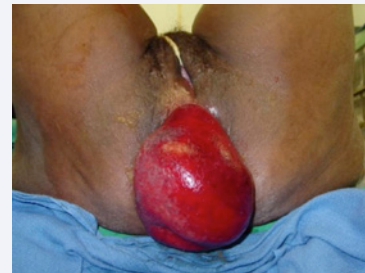All patients are generally examined in both the prone jack-knife and physiologic sitting positions (Figure 6). Important features worth noting on physical examination include the

- general perianal topography (appearance)
- presence of associated pathologies
- sphincteric integrity
- a patulous anus
- mucosal versus full-thickness prolapse
- length & diameter of the prolapse
- spontaneous versus manual reduction
- complete vs. incomplete reduction
- alterations in the mucosal surface
- resting and squeeze tone
- anocutaneous reflex
- spontaneous evacuation of feces (commode)

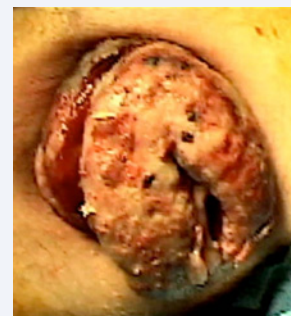Multiple pelvic organ prolapse in females is common and most likely under-reported [10]. The spectrum of pelvic floor abnormalities associated with rectal prolapse particularly in females includes:



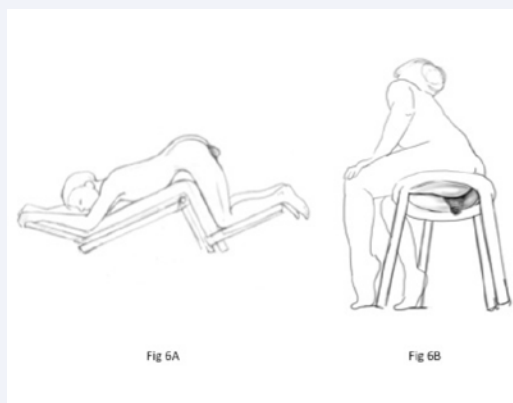
**Figure 3** A profoundly edematous incarcerated rectal prolapse is depicted.



**Figure 4** Incarcerated rectal prolapse with incipient ischemic changes i.e., a strangulated prolapse.



**Figure 5** An obviously necrotic rectal prolapse is evident.



**Figure 6** Physical examination in the prone-jackknife position (a) is complimented by evaluation in the physiologic sitting position preferably on a commode (b).

- Rectocele
- Cystocele
- Enterocele
- Sigmoidocele
- Uterine procidentia
- Vaginal procidentia
- Levator hernias
- Perineal descent

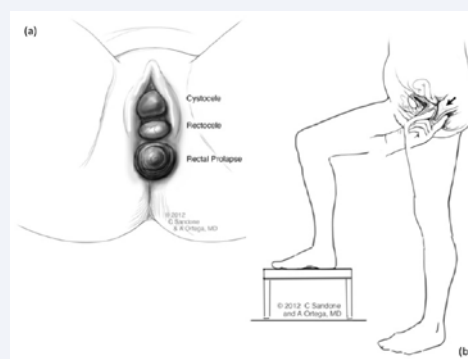
A complete assessment for pelvic organ prolapse in females requires examination in multiple positions including jack-knife, lithotomy, sitting on a commode, and step-standing rectovaginal bidigital examination. This is important, for example, because a cystocele not apparent in prone jackknife position may become quite pronounced in the lithotomy position especially with a full bladder as gravity allows the latter to fall forward. Moreover, the bi-digital rectovaginal exam in the “step-standing” position is best suited for detection of small bowel (enterocele) or large bowel (sigmoidocele) within the cul-de-sac (Figure 7).

Rectal prolapse may be described as mucosal or full-thickness. Mucosal prolapse may be eccentric or concentric. (Figure 8) There is no established classification of full thickness rectal prolapse. However, it is reasonable to consider that the human rectum measures 12 to 15 centimeters. Therefore, prolapses measuring greater than half the average length of the rectum probably include a colonic component. Total or near total loss of mesorectal to sacral fixation must be underlying this advanced presentation. At the other extreme are prolapses measuring 2 to 3 centimeters from the anal verge. These small prolapses may be entirely extra-pelvic with no significant loss of mesorectal to sacral fixation.

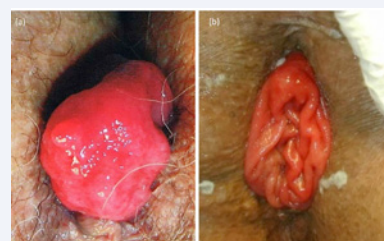
Moderate size prolapses lie in between the two extremes with highly varying degrees of mesorectal to sacral disassociation. These may be arbitrarily classified as such because they are clearly greater than a few centimeters, but do not possess an obvious colonic component present in large or massive rectal prolapses. Large and small prolapses have distinct therapeutic implications. Small prolapses are well managed from a perineal approach. Large prolapses are best handled from an abdominal approach. Intermediate or moderate size prolapses require considerable clinical judgment vis-à-vis surgical approach (Figure 9).

### Adjunctive studies

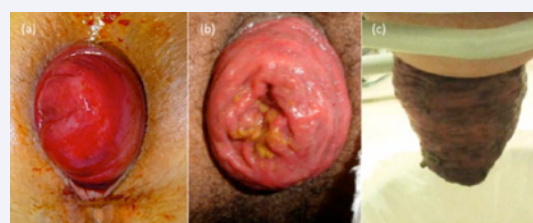
The authors' recommend using selective adjunctive imaging with either dynamic defecography and/or dynamic pelvic MRI, especially with moderate sized prolapse to fully define the extent of disease. Dynamic defecography has the principal advantage of being performed in the physiologic sitting position. It is an excellent test for paradoxical puborectalis dysfunction (anismus). The latter condition is one of many causes of the obstructed defecation syndrome (ODS). One surgically correctable cause of ODS is the presence of a rectocele with an occult or internal rectal intussusceptions. In this setting, defecography demonstrates internal rectal intussusceptions with a rectocele creating a distal recto vaginal valve effect (Figure 10). The combination



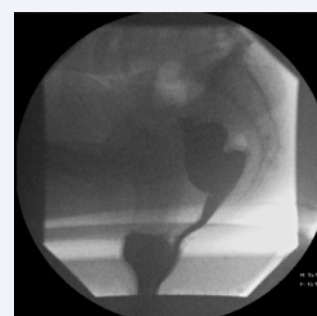
**Figure 7** Examination of the female patient is particularly enhanced if placed in the lithotomy position where gravity facilitates the detection of multiple organ prolapse (a). Bi-digital recto-vaginal examination in the step-standing position facilitates the detection of potential enterocele or sigmoidocele (b).



**Figure 8** (a) Demonstrates an eccentric mucosal prolapse. (b) Is a typical concentric mucosal (partial) prolapse.



**Figure 9** Full thickness rectal prolapse may present as small (a), moderate sized (b) or massive external intussusceptions of the rectum and colon through the anal canal (c).



**Figure 10** A classic depiction of obstructed defecation syndrome following an anterior resection and rectopexy for rectal prolapse. The distal rectum forms a recto-rectal intussusceptum and a secondary rectocele with a “flap valve” obstruction at the interface of the rectum and vagina.

of full thickness or overt rectal prolapse with rectocele may be under-appreciated in female patients. It may also account for an important contributing factor to their complaint of constipation.

Defecography also demonstrates the mesorectal to sacral disassociation (absent fixation) objectively (Figure 11). Patients with full-thickness rectal prolapse may demonstrate varying degrees of mesorectal to sacral disassociation in which recto-sacral fixation is well preserved and prolapse is a distal anorectal extrapelvic phenomenon (Figure 12). Alternatively, other individuals demonstrate global or high mesorectal-sacral disassociation in which the entire rectum slides off the sacrum. These contrasting findings may be useful in selection of the operative approach in individual patients.

Dynamic pelvic MRI has advantages in demonstrating global pelvic floor disorders including multiple pelvic organ prolapse and perineal descent (Figure 13). Its principal disadvantage is that most facilities only have “closed” MR scanners in which the study is done in the supine position. Dynamic Pelvic MRI performed in the recumbent position may grossly underestimate mesorectal sacral disassociation. Newer technologies include open MR scanning in which the patient is studied in the sitting position [11]. Bertschinger suggests several advantages of open MRI over the traditional closed technology. Another interesting and promising technology is three-dimensional dynamic CT of the pelvis [12].

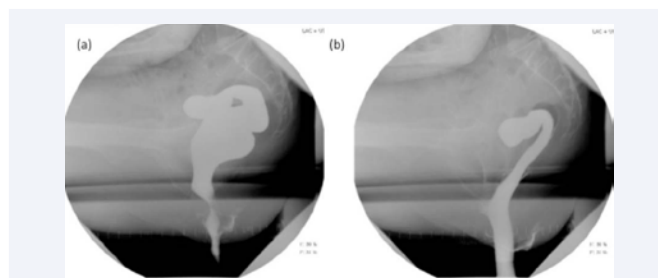
Endoscopic visualization of the recto sigmoid is essential in excluding a mass as a lead point to the intussusceptum. The decision to perform flexible sigmoidoscopy versus colonoscopy should be elected based on patient age and associated symptoms.

## MEDICAL TREATMENT OF ACUTE INCARCERATED PROLAPSE

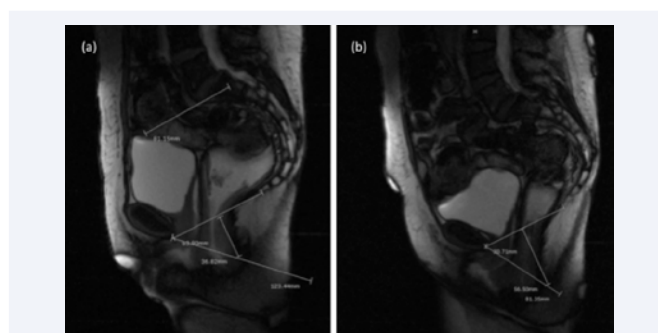
Reduction of an acutely incarcerated full thickness rectal prolapse is feasible and desirable in most cases. Failure to reduce an incarcerated rectum may proceed to strangulation, obstruction of venous outflow, ischemia and necrosis. The use of topical granulated sugar to assist in the reduction of an incarcerated rectal prolapse was borrowed from the veterinary experience. Particularly young horses are prone to colic, which results occasionally in equine rectal prolapse. The application of granulated sugar acts as an osmotic agent, which reduces the swelling of the exteriorized rectum. Empirically, the rectal mucosa is generously covered with sugar. As the swelling diminishes, the rectum may be gently reduced through the anal canal (Figure 14). An alternative approach to decompression of an incarcerated rectal prolapse consists placing a large elastic compressive bandage around the prolapse to achieve the same result [13]. Definitive treatment should be considered in situations where the prolapse is a chronic or relapsing condition. In cases where mucosal blood supply is compromised, rectal amputation (perineal procto-sigmoidectomy) with an anorectal or colo-anal anastomosis is the only viable option (Figure 15).

## Surgical treatment in historical perspective

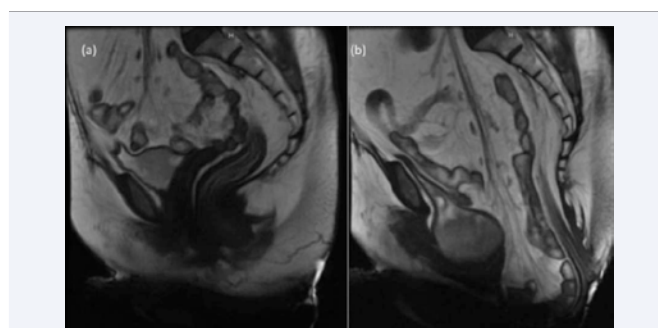
Surgery for rectal prolapse has focused historically on either the elimination of the end-organ effect (i.e., the prolapse) versus the presumptive mechanism (i.e., colo-rectal-anal



**Figure 11** (a) demonstrates defecography of a patient with rectal prolapse in the resting state. Straining clearly shows the absence of mesorectal to sacral fixation (b).



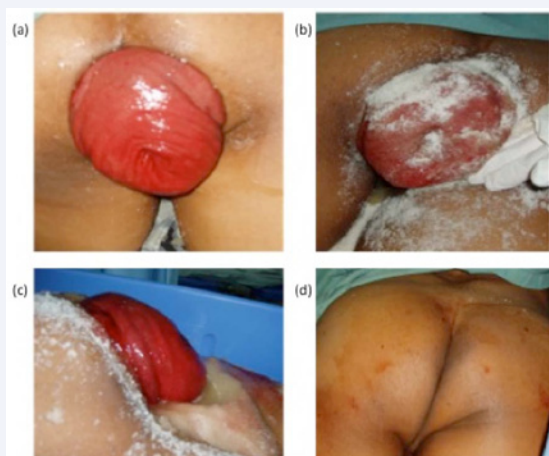**Figure 12** Dynamic MRI in a patient with full-thickness rectal prolapse in the resting phase is demonstrated (a). Upon straining (b) the intra-pelvic rectum remains well associated to the sacrum. However, the extra-pelvic rectum descends to form the prolapse.



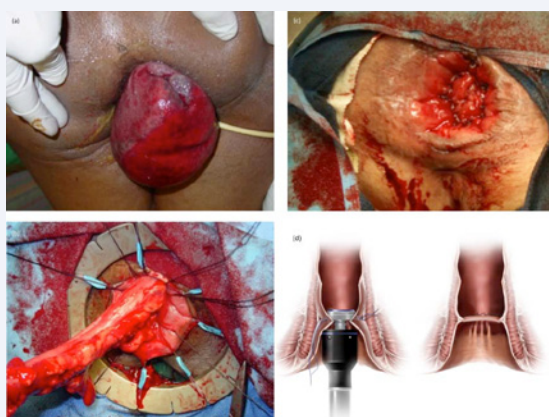
**Figure 13** Dynamic MRI in a female with suspected multiple pelvic organ prolapse. The resting image (a) is in bold contrast to the straining image (b) which shows a prominent pelvic floor descent, cystocele and enterocele in combination with a clinically obvious full-thickness rectal prolapse.

intussusception). No single pathology in surgery has been the focus of as much technical innovation and variety of proposed surgical approaches as rectal prolapse. Approaches can be divided into two broad categories: abdominal and perineal approaches. The earliest technique is credited to Theirsch who described a circum-anal circlage with silver wire [14]. This technique closes the anal outlet sufficiently to prevent prolapse of the rectum through the anal canal. Since the nineteenth century when this procedure was introduced, every conceivable modification has been suggested. Most recently Saenz describes suture narrowing of the distal rectum [15]. The principal advantage of circum-anal circlage and similar concepts is that they constitute a diminutive





**Figure 14** The successful treatment of an incarcerated rectal prolapse with granulated sugar in a young male adult is depicted. (Photos courtesy of Dr. Martin Arroyo).



**Figure 15** An incarcerated incipiently ischemic prolapse is in evidence (a). It is managed with a perineal proctosigmoidectomy (b) with either a hand-sewn (c) or stapled colo-anal anastomosis (d) aka the Altemeir procedure. Note: the stapled anastomosis is usually performed between two purse-string sutures placed in the colon and remaining rectal stump.

procedure well suited in otherwise poor-risk, debilitated patients. Erosions and extrusions of the encircling material are common, thus limiting the use of the procedure.

Delorme proposed a unique approach circa 1900 [17]. This procedure consists of mucosal stripping of the prolapsed rectum. A series of plication sutures on the remaining muscular tube invert the remaining prolapse back into rectum. While the recurrence rates are highly variable, it remains a popular repair in many centers throughout the world especially for the smaller for small to moderate sized full thickness rectal prolapses in poor risk surgical patients (Figure 16).

Moschcowitz described the first twentieth century repair in 1912 [2]. A series of purse-string sutures were placed in the pelvis via laparotomy incision obliterating the pouch of Douglas. Gant described no less than twelve techniques he considered useful in the treatment of rectal prolapse by 1923 [3]. Gant wrote and illustrated perineal and abdominal approaches as

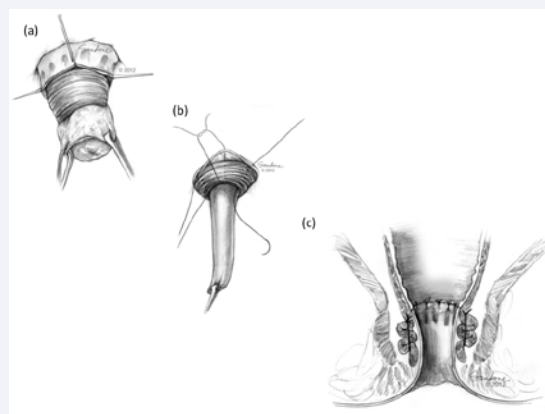
well as combined approaches. His treatise clearly describes the technique of rectal amputation with colo anal anastomosis. This technique later received the acronym of the Altemeir procedure [18] in 1965 and is still particularly useful in the setting of ischemic or necrotic prolapse. Lockhart-Mummery described both a perineal recto-levatoroplasty as well as a sigmoidopexy in his textbook in 1937 [19].

Since these times, the world's surgeons have produced a prolific list of ingenious alternatives and variations on previous themes. The plethora of surgical solutions to the problem of full thickness rectal prolapse is ample evidence that there is no single best solution.

### Contemporary surgical options

The closing of the twentieth century brought about unprecedented changes in surgery with the introduction of minimally invasive or laparoscopic techniques. Berman was the first to report his technique of a laparoscopic rectopexy in 1992 [20]. Since this time, multiple studies have demonstrated that the use of laparoscopy is associated with shorter hospital length of stay and fewer postoperative complications [21-24], making it the preferred approach for most procedures done today. Recurrence rates appear to be equivalent between minimally invasive and conventional surgery [23]. Kaiwa demonstrated that laparoscopic surgery is feasible and safe in the elderly frail patient with rectal prolapse [25], suggesting that a perineal approach is not always required for these patients. Relegating this subgroup of patients to perineal approaches with higher recurrence rates may no longer be a valid paradigm. Clearly, traditional laparotomic surgery offers no advantages other than perhaps safety in the setting of previous abdominal or pelvic surgery where normal anatomic landmarks are obscured by adhesions or scarring.

Perineal approaches for the treatment of rectal prolapse continue to have a place in the twenty-first century surgical armamentarium. However, surgeons must balance the physiologic condition of the patient, the success rate of the surgical approach and the functional outcome. Rectal prolapse is a pleomorphic condition vis-à-vis gender, size and clinical



**Figure 16** The Delorme procedure entails a circumferential mucosectomy (a). Eight imbricating sutures are placed in the remaining muscular rectal wall (b) restoring mucosal anodermal continuity and reduction of the rectal prolapse (c).

presentation as well as associated symptoms and anatomic pathology. Therefore, the surgical armamentarium in the 21<sup>st</sup> century needs to remain diverse. Three variations on previous themes seem most appropriate in current day practice:

1. posterior rectopexy +/- prosthetic mesh
2. posterior rectopexy +/- anterior resection
3. ventral rectopexy

Posterior rectopexy with or without prosthetic mesh is the workhorse for most surgeons dealing with rectal prolapse. It is simple to perform, has good results, and has been validated with long-term follow up. The biggest downside is its association with postoperative constipation, which is present in up to 50% of patients. The exact mechanism for this remains a mystery, but proposed theories include pelvic floor and nerve dysfunction after denervation, dysmotility caused by scarring and prosthetic material, and a redundant sigmoid that causes a functional obstruction [26]. Various methods for mesh placement or suture fixation have been described and are discussed later in this chapter, though none have proven superior and all have similar complication and recurrence rates [21].

Posterior rectopexy and anterior resection combines the use of a sigmoid resection to the rectopexy with the goal of eliminating the troublesome constipation that occurs following rectopexy alone. By removing a segment of colon, the surgeon hopes to circumvent this complication. One of the theories behind why constipation occurs following rectopexy is that a redundant sigmoid kinks over the rectal fixation and delays transit. The addition of a resection makes most authors wary of using mesh for fear of infectious complications, so only suture rectopexy is performed. Resection rectopexy resulted in a slight increase in operative time and length of stay compared with rectopexy alone, but was associated with less constipation and similar recurrence risk [27].

Otto reported a small series of patients undergoing anterior resection combined with rectopexy using an absorbable mesh. The report only has 21 patients with an average follow up of 15 months. However, prolapse was eliminated in all subjects. The technique improved rectal evacuation as well as continence. Despite the inherent limitations of this study, the concept clearly merits further investigation [40].

Ventral Rectopexy is the newest addition to the mainstream laparoscopic procedures. Although only evaluated in several small series, it appears to be associated with lower rates of postoperative constipation, with only 10-15% of patients experiencing this complication [26,28]. Particularly in females, it has theoretic advantages of avoiding a posterior or lateral rectal dissection (and thus any risk of parasympathetic denervation of the rectum), prevention or correction of anterior rectocele by reinforcing the rectovaginal septum, and prevention of associated enterocele or uterine prolapse by elevating the pouch of Douglas by re-peritonealizing over the mesh. The selection of a particular surgical approach should be tailored to each patient based on expectations, the surgeons experience and familiarity with a given procedure, and any comorbid or associated conditions.

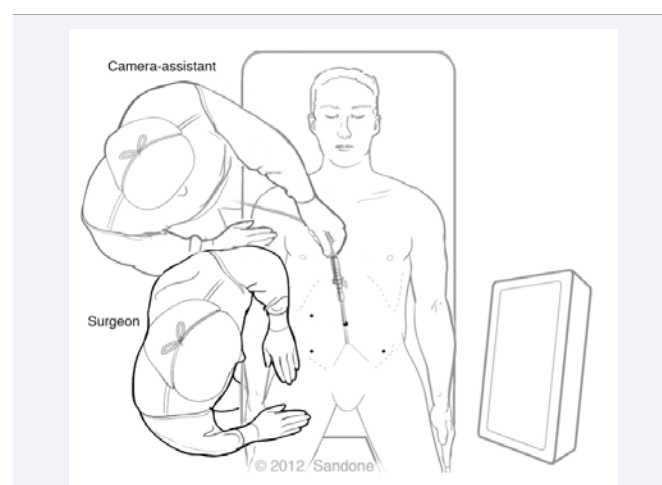
## Technical aspects of prolapse surgery

The goal of surgery for full thickness rectal prolapse is removal or fixation of the rectum to prevent ongoing intussusception. Coloproctectomy with coloanal anastomosis defines perineal approaches, while recto-sacral fixation after anterior or posterior complete mobilization is the cornerstone of abdominal approaches.

The Altemeier and Delorme procedures are the two most commonly performed via the perineal approach. The Altemeier procedure involves a full thickness excision of a segment of rectosigmoid starting 1-2cm above the dentate line. The rectum is pulled out until no further prolapsed is possible and transected, performing a hand sewn coloanal anastomosis between the fully exteriorized rectum or sigmoid and the anus. This approach may require division of some segment of mesentery to allow complete excision (Figure 15). The Delorme procedure involves only a mucosectomy, with preservation of the muscular layer. The surgeon divides the mucosa of the fully prolapsed rectum again starting just above the dentate line and continues down until the muscularis propria is encountered. A sleeve mucosectomy is carried to the apex of the prolapsed tissue and then back around to the most proximal aspect of the prolapse opposite the dentate line. The muscle layers are reduced and the mucosal edges from proximal and distal ends are joined, with an accordion-like sleeve of muscle reinforcing the anastomosis (Figure 16).

Laparotomic and laparoscopic approaches to rectal prolapse follow very similar principles. A very suitable set up and trocar configuration is illustrated in (Figure 17).

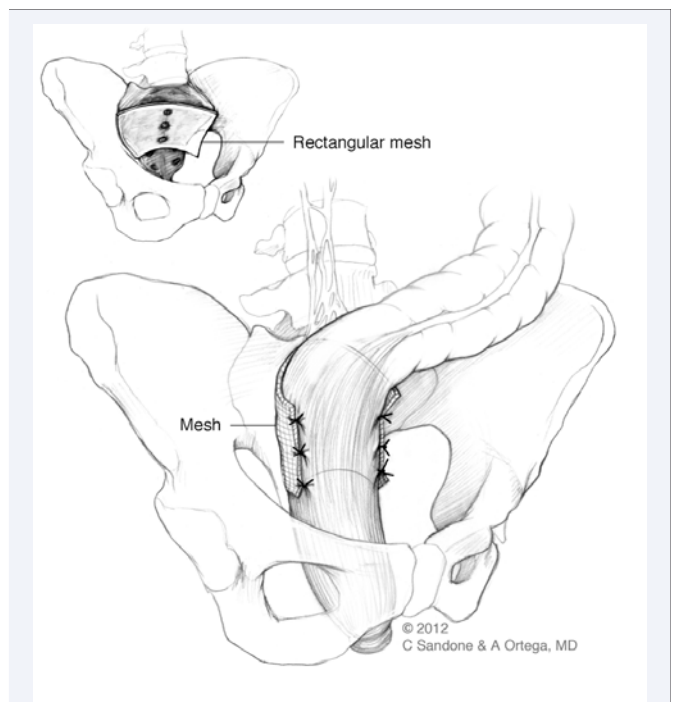
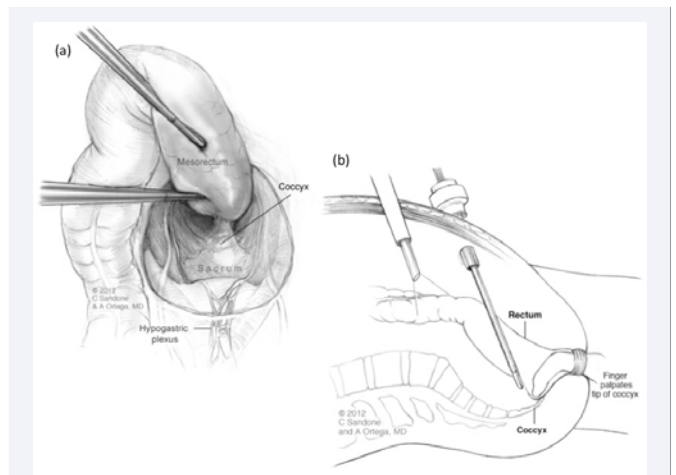
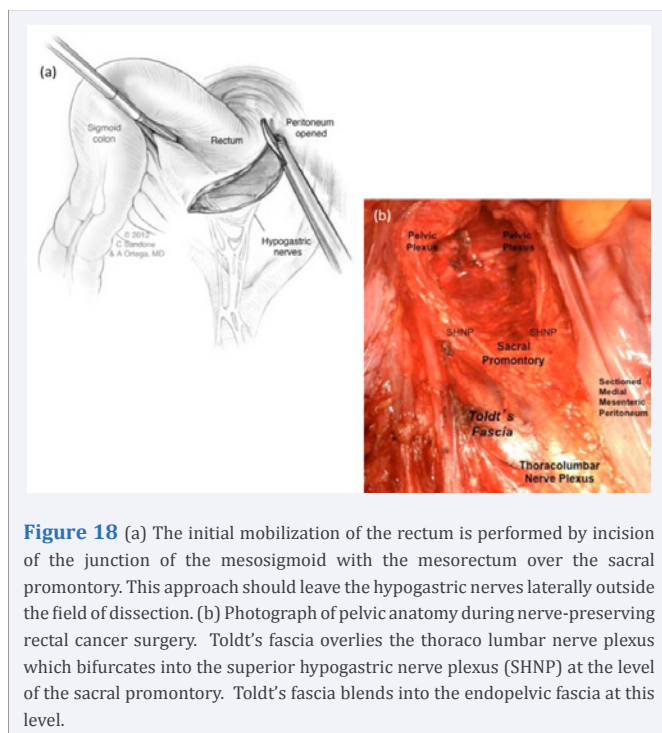
For an abdominal approach via posterior mobilization, the first important point is to enter the retrorectal space incising the peritoneal surface at the base of the junction of the mesosigmoid-mesorectal junction just anterior to the sacral promontory in the midline (Figure 18a). This is done after reducing the bowel out of the pelvis as much as possible as prolapse causes the relevant anatomic structures to be pulled caudally. Careful blunt dissection under the superior rectal artery allows entry into the retrorectal areolar plane where pneumo dissection opens the appropriate



**Figure 17** Laparoscopic recto sigmoid mobilization can be approached with a standard four-port configuration as depicted above.

pathway between the fascia propria of the rectum and the endopelvic (or presacral fascia). The surgeon can appreciate a transparent “cellophane-like” layer of fascia overlying the aorta, iliacs, ureters and superior hypogastric nerve plexus known as Toldt’s fascia—the continuation of the retroperitoneal Treitz fascia (Figure 18b). As the retrorectal dissection proceeds, the superior hypogastric plexus will bifurcate laterally on the wall of the endopelvic fascia and rectum. The dissection proceeds posterior to the rectum through the fibro areolar planes until reaching Waldeyer’s fascia—i.e., the posterior confluence of the fascia propria and pre-sacral fascia. Sectioning of Waldeyer’s fascia allows direct visualization of the pelvic floor with the pubococcygeus and ileococcygeus muscle often in full frontal view. An examining finger introduced through the anal canal may corroborate that the tip of the coccyx has been reached and that the posterior rectal dissection is complete (Figure 19). This dissection should encompass the posterior 60% of the mesorectum to leave lateral stalks that contain parasympathetic nerve supply to the rectum undisturbed.

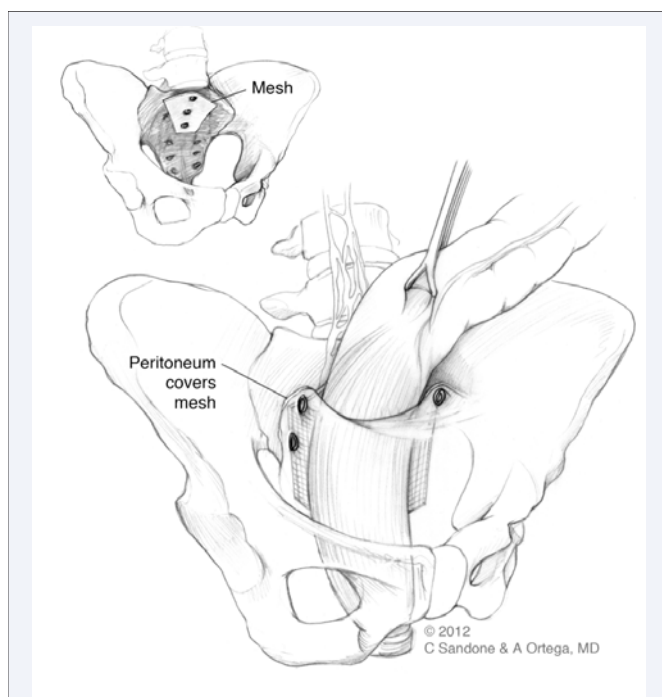
Mesh placement after posterior dissection was described by Wells [29] (Figure 20). This approach involves placing an appropriately sized piece of polypropylene mesh with large apertures to minimize the risk of infection just below the sacral promontory. Permanent suture or a tracking device is used to fixate this to the bone. Mesh should be secured in the midline just below the promontory to prevent inadvertent injury to the hypogastric nerves or presacral veins. The mesh is then wrapped around the rectum and secured to the lateral “wings” created by previous dissection while placing the rectum on tension in a cephalad direction, thereby reducing the prolapse as much as possible. One to two sutures or tacks are required per side. An alternative approach was described by Ripstein, whereby the mesh was placed anterior to the colon and secured posteriorly [30]. This approach has largely been supplanted



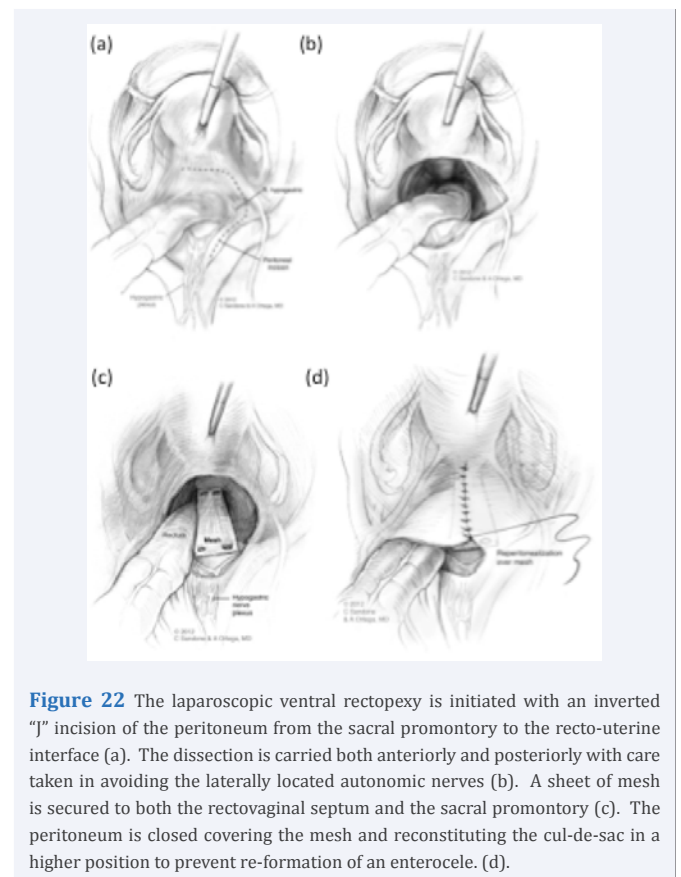
by the Wells rectopexy due to effects of rectal entrapment and constipation. The authors prefer using a smaller three by three centimeter square or rhomboidal sheet of mesh that is tacked to the sacrum just below the promontory. The peritoneal leaves remaining on the rectum are then tacked to the mesh accomplishing posterior fixation and re-peritonealization in the same maneuver (Figure 21).



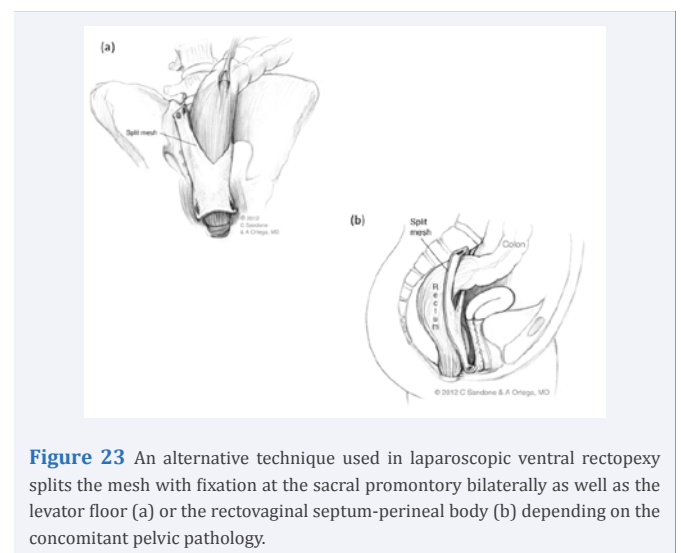
For anterior mobilization via abdominal approach, similar principles apply. Dissection begins on the patient's right side with the rectum retracted to the left. An incision is again made in the peritoneal surface at the base of the junction of the mesosigmoid-meso rectal junction just anterior to the sacral promontory near the midline. Care is taken to identify the right ureter as an "inverted J" incision in the peritoneal surface is created by extending dissection caudally toward the recto vaginal septum and around to the patient's left side (Figure 22). Some authors then incise Dennoivillier's fascia and the recto vaginal septum is dissected to the level of the pelvic floor. Alternatively, the pouch of Douglas dissection can be carried in between the anterior aspect of the fascia propria of the rectum and the posterior aspect of Dennoivillier's fascia. This approach leaves the nervi erigentes on the posterior vaginal wall undisturbed. Moreover, it provides a more hemostatic plane for dissection. A retractor inserted in the vagina and anterior suspension of the uterus assists with this mobilization. One should leave enough peritoneum on the vaginal surface to allow re-peritonealization over the mesh, which results in elevation of the pouch of Douglas. A sheet of polypropylene mesh is then sutured to the anterior surface of the rectum and the sacral promontory to promote cephalad displacement of the redundant rectum out of the pelvis. The mesh can be brought medial to the rectum for sacral fixation. Some authors split the mesh into an inverted "Y" configuration, which is secured on both the lateral and medial sides of the rectum to the sacrum (Figure 23). The posterior surface of the vagina is also secured to the mesh, which serves to elevate it out of the pelvis. Some authors prefer to secure the mesh distally to the levator muscles. Finally the peritoneal surface is closed over the mesh to prevent adhesion of the small bowel to its surface.



**Figure 21** An alternative to the traditional laparoscopic Wells procedure entails placement of a smaller rhomboid shaped mesh tacked to the sacrum and to the lateral leaves of the rectal peritoneum accomplishing the rectopexy and coverage of the mesh with peritoneum in the same maneuver.



**Figure 22** The laparoscopic ventral rectopexy is initiated with an inverted "J" incision of the peritoneum from the sacral promontory to the recto-uterine interface (a). The dissection is carried both anteriorly and posteriorly with care taken in avoiding the laterally located autonomic nerves (b). A sheet of mesh is secured to both the rectovaginal septum and the sacral promontory (c). The peritoneum is closed covering the mesh and reconstituting the cul-de-sac in a higher position to prevent re-formation of an enterocele. (d).



**Figure 23** An alternative technique used in laparoscopic ventral rectopexy splits the mesh with fixation at the sacral promontory bilaterally as well as the levator floor (a) or the rectovaginal septum-perineal body (b) depending on the concomitant pelvic pathology.

### Clinical focus on pelvic nerve preservation

The common objective in both anterior and posterior mobilization is the restoration of proper fixation to the sacrum. This objective needs to be accomplished with minimal collateral damage to the surrounding neuroanatomic structures. While the surgical literature historically for rectal prolapse has been robust, emphasis on the importance of autonomic nerve preservation has been under-appreciated. Speculation on the role of nerve damage in the course of surgery for the correction of rectal prolapse with



respect to postoperative functional outcomes is increasing [31]. Lessons learned in the treatment of rectal cancer and pelvic nerve preservation may be helpful. Mobilization of the rectum for both benign and malignant disease portends five opportunities for nerve damage:

1. proximally with dissection or division of the IMA or superior rectal artery (sympathetic injury)
2. anterior to the aorto-iliac bifurcation upon entering the pre-sacral space (sympathetic injury)
3. Distal and laterally during the dissection of the rectum where pelvic plexi are formed joining the hypogastric nerves with the nervi erigentes (S2, S3 & S4) i.e., during division of the "lateral stalks." (parasympathetic injury)
4. Distal and anterior to the rectum in front of Dennoivillier's fascia which separates the hindgut from the genitourinary compartment. (parasympathetic injury)
5. Posterior to the rectum, the sacral nerves may be compromised if the "pre-sacral fascia" is inadvertently entered where the parasympathetic S2-S3-S4 nerves emanate. (sympathetic and parasympathetic injury)

Historically, most surgeons have elected to ignore pelvic neuroanatomy in the context of rectal prolapse repair. However, pelvic nerve preservation is an intuitively attractive and feasible goal in rectal mobilization for the treatment of rectal prolapse. The authors' practice involves several principles in the preservation of nerve function. First is entry into the presacral space very medially, near the midline at the level of the sacral promontory and immediately adjacent to the superior rectal artery. Second is maintenance of the dissection in the loose areolar plane with preservation of any small nerve fibers encountered in the course of dissection to the level of the levator hiatus. Third, care should be taken to avoid division of the "lateral stalks" of the rectum. For this reason, any mobilization is limited to only the anterior or posterior 60% of the total mesorectal circumference. Multiple studies have suggested that division of the lateral stalks results in higher rates of postoperative constipation [31,32]. Finally, the number of fixating sutures or tacks is limited. Two points of fixation to the sacrum in the midline and 1-2 additional points of attachment to each side of the mesorectum are usually sufficient. When performing a resection rectopexy, it is the authors' practice to keep the IMA vascular pedicle in situ when resecting anteriorly, as this creates less denervation and vascular compromise. In general, the effect of nerve physiology on postoperative bowel function is complex and poorly understood.

### Options for multiple pelvic organ prolapse

The problem of multiple organ prolapsed provides a dilemma for the surgeon. Multiple theories exist on the most appropriate procedure to fix all underlying problems. A discussion with the patient is very insightful to understand what the most bothersome symptom is or organ prolapsed. One option is to just fix the rectal prolapsed through an anterior approach with the hope that all other organs are drawn cephalad. This presumes that the rectum is the lead point for multi-organ prolapsed and cessation of its posterior descent will halt similar descent of other associated organs. A ventral repair may be most suited for this. However, a

sacrocolpopexy, bladder sling, or perineal suspension procedure may also be used. At present, because of the small numbers in the published literature, there is little consensus on the most appropriate way to approach these complex problems.

### Complications and functional outcomes

The twentieth century literature attests to higher recurrence rates for the perineal approaches (4-23% for perineal approaches vs 0-9% for abdominal approaches) [33]. Techniques that focus on restoration of rectal-to-sacral fixation tends to provide the lowest recurrence rates. Rectopexy, whether sutured, suture less, or with prosthetic materials is arguably the gold standard vis-à-vis longevity and surgical success. In a relatively recent Cochrane Review, twelve randomized controlled trials including 380 participants were studied for approach, fixation method, and use of laparoscopy. No detectable differences were found in type of fixation method, and there was insufficient data to conclude whether an abdominal or perineal approach provided a better outcome [21]. The literature is profoundly disparate in terms of functional outcomes, and there is no correlation to objective measures of outcome (e.g. manometry, postoperative defecography) and symptomatic results [12].

There exist conflicting data on the postoperative functional results of patients even within the same methodology used for repair [34]. This suggests that postoperative nerve function may depend more the individual patient rather than the technical approach to the repair. For example, a patient with long-standing or chronic prolapsed may have destroyed his or her nerve function such that even with preservation of all relevant structures and restoration of normal anatomy, the rectum remains denervated. In any case, this is likely an area that warrants further study, as we are just beginning to understand the complex nature of this field.

### Postoperative bowel function

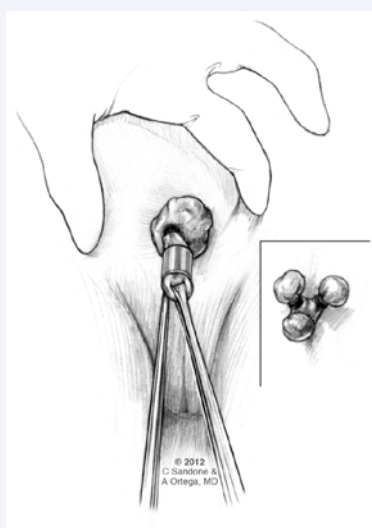
Multiple theories for exist for reasons in change in bowel habits following surgical repair of rectal prolapsed. Some are anatomic and others related to nerve function. Following a Delorme mucosectomy, a reduction in the maximal rectal volume and rectal compliance occurs, possibly creating more chance for incontinence. Some have suggested adding a levatoroplasty with anterior and posterior suture of the levator hiatus prior to resection via a perineal approach [26]. In patients with incontinence preoperatively, rectopexy improves continence is most patients. Theories for why include that sphincter function is restored by reducing the prolapse, anorectal sensation and or compliance is improved, and finally that postoperative constipation protects against incontinence even with an otherwise patulous anus [23]. In patients with constipation preoperatively, results are less predictable. Many remain constipated and some even deteriorate, though the reasons may be different. Preoperative constipation may be caused by difficulty evacuating beyond the obstructing segment of prolapsed bowel. Postoperative constipation may be due to denervation, thickening or scar tissue causing decreased motility after fixation to the sacrum. Anywhere between 30-84% of patients who are constipated preoperatively remain so postoperatively [22]. Since the ventral rectopexy is perhaps less constipating, this approach

may be better suited for preoperatively constipated patients. Another alternative is resection rectopexy. Again, no consensus exists in the literature and there are no randomized controlled trials comparing these newer approaches.

## RECURRENCE

Wide variances are reported in the surgical literature, but usually range from 0-23% with most reported rates less than 10%. This perhaps has to do with the fact that recurrence rates largely depend on length of follow up. Most reported studies have inadequate follow up and therefore probably underestimate recurrence data. Typical recurrences occur at a mean of 4 years postoperatively, based on a meta-analysis of pooled data, although can range from 0.05 to 15 years [36].

An additional factor may be the definition of recurrence. A full thickness recurrent prolapse, especially early, likely represents a technical failure. The most common reason in anterior repair is detachment of the mesh or suture from the sacral point of attachment. A more common occurrence is likely residual mucosal prolapsed despite reduction of the full thickness prolapsed. A study of patients who self reported recurrent prolapsed found that the vast majority of them in fact had residual mucosal prolapsed rather than a recurrence of their original disease process [37]. Options for fixing a recurrence include a repeat of the same procedure for technical failures or a change of technique via the same approach (e.g. anterior or posterior mobilization). Options for mucosal prolapsed include mucosal banding, mucosal resection with a PPH stapling device, or watchful waiting (Figure 24). Caution should be given when undertaking any form of resection as part of a previous repair, for fear of creating a segment of devascularized rectum. A low anterior resection after a perineal procedure could create an anastomosis to a distal segment with no vascular supply.



**Figure 24** Small mucosal prolapses occurring de-novo or as a residual of a formal prolapse procedure may be corrected by serial placement of hemorrhoidal rubber bands over several sessions. This procedure requires the Reis Neto macro version rubber band ligator. Conventional banders are not effective.

Long term satisfaction surveys show that around 75% of patients are satisfied with the results of laparoscopic procedures [23,38] despite the fact a number of these patients may have some residual prolapsed tissue.

## FINAL COMMENT

Rectal prolapse is a highly pleomorphic condition. Its treatment continues evolving. Careful clinical evaluation is still the cornerstone in its management. Minimally invasive surgical approaches appear to very appropriate for this condition in both the good and poor surgical risk patients. Optimal outcomes can only be obtained by careful selection of surgical approaches individualized to each patient.

## REFERENCES

1. Ballantyne GH. The Historical Evolution of Anatomic Concepts of Rectal Prolapse. *Seminars in Colon and Rectal Surgery*. 1991; 2: 170-179.
2. Moschocowitz AV. The pathogenesis, anatomy, and cure of prolapse of the rectum. *Surg Gynecol Obstet*. 1912; 15: 7.
3. Gant SG. *Diseases of the Rectum, Anus and Colon Volume II* Philadelphia; W.B. Saunders Company, 1923; 22-57.
4. Broden B, Snellman B. Procidencia of the rectum studied with cineradiography: a contribution to the discussion of causative mechanism. *Dis Colon Rectum*. 1968; 11: 330.
5. Ripstein CB. Procidencia: definitive corrective surgery. *Dis Colon Rectum*. 1972; 15: 334-336.
6. Slawik S, Soulsby R, Carter H, Payne H, Dixon AR. Laparoscopic ventral rectopexy, posterior colporrhaphy and vaginal sacrocolpopexy for the treatment of recto-genital prolapse and mechanical outlet obstruction. *Colorectal Dis*. 2008; 10: 138-143.
7. Aboul-Enein A. Prolapse of the rectum in young men: Treatment with a modified Roscoe Graham operation. *Dis Colon Rectum*. 1979; 22: 117-199.
8. Marceau C, Parc Y, Debroux E, Tiret E, Parc R. Complete rectal prolapse in young patients: psychiatric disease a risk factor of poor outcome. *Colorectal Dis*. 2005; 7: 360-365.
9. Brown AJ, Nicol L, Anderson JH, McKee RF, Finlay IG. Prospective study of the effect of rectopexy on colonic motility in patients with rectal prolapse. *Br J Surg*. 2005; 92: 1417-1422.
10. Ayav A, Bresler L, Brunaud L, Zarnegar R, Boissel P. Surgical management of combined rectal and genital prolapse in young patients: transabdominal approach. *Int J Colorectal Dis*. 2005; 20: 173-179.
11. Bertschinger KM, Hetzer FH, Roos JE, Trelber K, Marincek B, Hilfker PR. Dynamic MR Imaging of the Pelvic Floor Performed with Patient Sitting in an Open-Magnet Unit versus Patient Supine in a Closed-Magnet Unit. *Radiology*. 2002; 223: 501-508.
12. Okamoto N, Koutarou M, Kato R, Senga S, Sato H, Hosono R. Dynamic pelvic three-dimensional computed tomography for investigation of pelvic abnormalities in patients with rectocele and rectal prolapsed. *J Gastroenterol*. 2006; 41: 802-806.
13. Scarpel U, Jacob BP, Steinhagen RM. Reduction of a large incarcerated rectal prolapse by use of an elastic compression wrap. *Dis Colon Rectum*. 2005; 48: 1320-1322.
14. Keighley MRB, Williams NS. *Surgery of the Anus, Rectum and Colon* (London: W.B. Saunders Company Ltd.). 1993; 675-719.

15. Villanueva Sáenz E, Martínez Hernández-Magro P, Alvarez-Tostado Fernández JF. Helicoidal suture: alternative treatment for complete rectal prolapse in high-risk patients. *Int J Colorectal Dis.* 2003; 18: 45-49.
16. Hachiro Y, Kunimoto M, Abe T, Kitada M, Ebisawa Y. Aluminum potassium sulfate and tannic acid injection in the treatment of local rectal prolapsed: early outcomes. *Dis Colon Rectum.* 2007; 50: 1996-2000.
17. Delorme E. Communication sur le traitement des prolapsus du rectum totaux, par l'excision de la muqueuse rectale ou rectocolique. *Bulletins et Memoires de la Societe des Chiurgiens de Paris.* 1900; 26: 499-518.
18. Altemeier WA, Culbertson WR, Schowengerdt C, Hunt J. Nineteen years' experience with the one-stage perineal repair of rectal prolapse. *Ann Surg.* 1971; 173: 993-1006.
19. Lockhart-Mummery JP. *Disease of the Rectum and Colon*, 2nd edition (Baltimore: William Wood and Company. 1934; 110-129.
20. Berman IR. Sutureless laparoscopic rectopexy for procidentia. Technique and implications. *Dis Colon Rectum.* 1992; 35: 689-693.
21. Ton A, Brown SR, Malik AI, Nelson RL. Surgery for complete rectal prolapse in adults (Review): The Cochrane Library. 2009.
22. Demirbas S, Akin ML, Kalemoglu M, Ogün I, Celenk T. Comparison of laparoscopic and open surgery for total rectal prolapse. *Surg Today.* 2005; 35: 446-452.
23. Kariv Y, Delaney CP, Casillas S, Hammel J, Nocero J, Bast J, et al. Long-term outcome after laparoscopic and open surgery for rectal prolapse: a case-control study. *Surg Endosc.* 2006; 20: 35-42.
24. Byrne CM, Smith SR, Solomon MJ, Young JM, Eysers AA, Young CJ. Long-term functional outcomes after laparoscopic and open rectopexy for the treatment of rectal prolapse. *Dis Colon Rectum.* 2008; 51: 1597-1604.
25. Kaiwa Y, Kurokawa Y, Namiki K, Myojin T, Ansai M, Satomi S. Outcome of laparoscopic rectopexy for complete rectal prolapsed in patients older than 70 years versus younger patients. *Surg Today.* 2004; 34: 742-746.
26. D'Hoore A, Cadoni R, Penninckx F. Long-term outcome of laparoscopic ventral rectopexy for total rectal prolapse. *Br J Surg.* 2004; 91: 1500-1505.
27. Madbouly KM, Senagore AJ, Delaney CP, Duepre HJ, Brady KM, Fazio VW. Clinically based management of rectal prolapse. Comparison of the laparoscopic Wells procedure and laparoscopic resection with rectopexy. *Surg Endosc.* 2003; 17: 99-103.
28. D'Hoore A, Penninckx F. Laparoscopic ventral recto (colpo)pepy for rectal prolapse: surgical technique and outcome for 109 patients. *Surg Endosc.* 2006; 20: 1919-1923.
29. Wells C. New operation for rectal prolapse. *Proc R Soc Med.* 1959; 52: 602-603.
30. Ripstein CB. Treatment of massive rectal prolapse. *Am J Surg.* 1952; 83: 69-71.
31. Boons, Collinson R, Curnningham C, Lindsay I. Laparoscopic ventral rectopexy for external recta prolapse improves constipation and avoids de novo constipation. *Colorectal Dis.* 2010; 12: 526-532.
32. Speakman CTM, Madden MV, Nicholls RJ, Kamm MA. Lateral ligament division during rectopexy causes constipation but prevents recurrence: results of a prospective randomized study. *Br J Surg.* 1991; 78: 1431-1433.
33. Scaglia M, Fasth S, Hallgren T, Nordgren S, Oresland T, Hulten L. Abdominal rectopexy for rectal prolapsed. Influence of surgical technique on functional outcome. *Dis Colon Rectum.* 1994; 37: 805-813.
34. Marchal F, Bresler L, Ayav A, Zarnegar R, Brunaud L, Duchamp C, et al. Long-term results of Delorme's procedure and Orr-Loygue rectopexy to treat complete rectal prolapse. *Dis Colon Rectum.* 2005; 48: 1785-1790.
35. Brown AJ, Nicol L, Anderson JH, McKee RF, Finlay IG. Prospective study on the effect of rectopexy on colonic motility in patients with rectal prolapse. *Br J Surg.* 2005; 92: 1417-1422.
36. Chun SW, Pikarsky AJ, You SY, Gervaz P, Efron J, Weiss E, et al. Perineal rectosigmoidectomy for rectal prolapse: role of levatorplasty. *Tech Coloproctol.* 2004; 8: 3-8.
37. DiGiuro G, Ignjatovic D, Brogger J, Bergamaschi R. How accurate are published recurrence rates after rectal prolapse surgery? A meta-analysis of individual patient data. *Am J Surg.* 2006; 101: 773-778.
38. Byrne CM, Smith SR, Solomon MJ, Young JM, Eysers AA, Young CJ. Long-term functional outcomes after laparoscopic and open rectopexy for the treatment of rectal prolapse. *Dis Colon Rectum.* 2008; 51: 1597-1604.
39. Zittel TT, Manncke K, Haug S, Schäfer JF, Kreis ME, Becker HD, et al. Functional results after laparoscopic rectopexy for rectal prolapse. *J Gastrointest Surg.* 2000; 4: 632-641.
40. Otto SD, Ritz JP, Grone J, Buhr AJ. Abdominal resection rectopexy and an absorbable polyglactin mesh: prospective evaluation of morphological and function changes with consecutive improvement of patient's symptoms. *World J Surgery.* 2010; 34: 2710-2716.

## Cite this article

Ortega AE, Cologne KG, Lee SW (2017) Management of Rectal Prolapse –The State of the Art. *JSM Gen Surg Cases Images* 2(1): 1018.