

## Case Report

# Giant Retroperitoneal Myxoid Liposarcomas, Survival in Chromosomal Fragility

Ramiro Gálvez-Valdovinos<sup>2\*</sup>, Felipe Cruz-Vigo, M<sup>1</sup>, José Ignacio Martínez-Pueyo<sup>1</sup>, and ErnestoMarín y Santillan<sup>2</sup>

<sup>1</sup>Department of Surgery, Complutense University, Spain

<sup>2</sup>Division of Surgery, Hospital Angeles León, Mexico

**\*Corresponding author**

Ramiro Gálvez Valdovinos, División of Surgery, Complutense University, Av. Cerro Gordo #311- 830, Lomas del Campestre, CP 37150, León, Guanajuato, México, Tel: 477-7885683; Email: vgalvez@angelesleon.com

**Submitted:** 04 February 2017

**Accepted:** 12 February 2017

**Published:** 26 February 2017

**Copyright**

© 2017 Gálvez-Valdovinos et al.

**OPEN ACCESS****Keywords**

- Myxoid liposarcoma
- Giant tumor
- Chromosome 16q breakage

**Abstract**

**Background:** Primary retroperitoneal sarcomas are rare, corresponds 0.1 to 0.2 percent of all malignant lesions in adults and represents 10-15% of all soft tissue sarcomas.

**Objective:** To describe the survival in two patients with giant retroperitoneal tumor when complete resection is carried out and the association with chromosome 16q breakage observed in karyotype obtained from peripheral blood.

**Clinical cases:** We report two similar clinical cases of large retroperitoneal myxoid liposarcoma in female patients. Physical examination revealed a globular abdomen due to a large mass in both cases. The diagnostic test were; abdominal X-ray, ultrasound, abdominal computed tomography (CT-scan), pyelography, arteriography and cavography, CT-scan guided fine needle aspiration biopsy and the peripheral blood was cultured and processed for G and C banding. Any of them did not receive chemotherapy or radiotherapy. Survival time free disease reaches 12 and 19 months respectively.

**Conclusions:** Both patients with increased 16q ruptures in peripheral blood and a large retroperitoneal myxoid retroperitoneal liposarcoma resected without chemotherapy and radiotherapy showed a short survival.

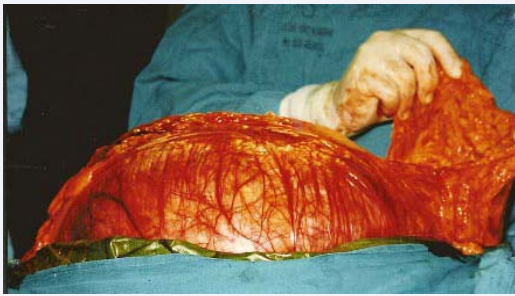
## INTRODUCTION

Primary retroperitoneal sarcomas are rare, accounting for only 0.1 to 0.2 percent of all malignant lesions in adults and represent 10-15% of all soft tissue sarcomas [1-3]. Resection of giant myxoid liposarcoma retroperitoneal must be well planned by the surgical team especially at the tumor anatomical location. Surgery of retroperitoneal myxoid liposarcoma is performed with curative intent, the survival time free of disease expected for these patients is 3 to 5 years in 60-73% of cases [1,2]. Is exceptional and anecdotal to see a live patient many months free of disease.

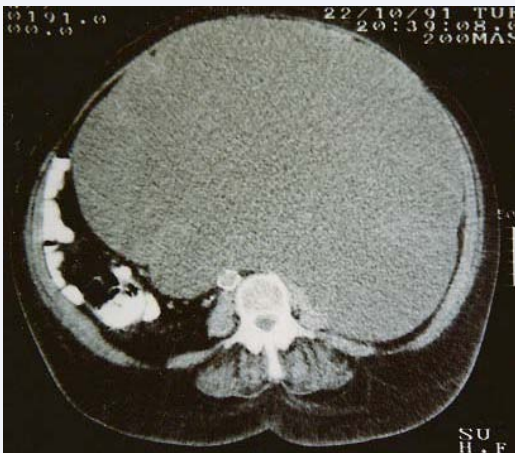
## CASE REPORT 1

A 65-years-old woman, with an enlarged abdominal perimeter of five months duration, presenting postprandial plenitude, constipation, asthenia, adynamia, lower limb edema and dyspnea. Physical examination revealed a distended abdomen, firm and rigid, with generalized dullness and a palpable mass filling the abdomen completely (Figure 1). Chest x-ray showed

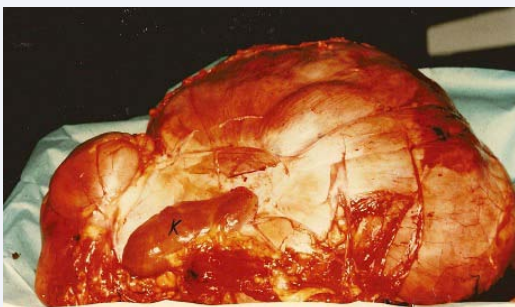
diaphragmatic dome elevation and gastric chamber dilation. Abdominal x-ray showed general opacity and faded left renal-psoas line. Abdominal ultrasound (US), abdominal computed tomography (CT-scan), intravenous pyelography, arteriography and cavography led to the conclusion of a large mass, scarcely vascularized, occupying the entire abdominal cavity, As it found in the retroperitoneum, a renal origin or primitive retroperitoneal tumor were discarded (Figure 2). The fine needle aspiration biopsy guided by CT-scan did not provide a definitive cytological diagnosis. A chromosomal study of peripheral blood lymphocytes preoperatively was performed. An exploratory laparotomy performed revealed a tumor of retroperitoneal with dimensions of 50 X 40 X 25 cm. complete removal of all gross tumors was performed involving the right kidney and adrenal gland. The tumor weighed 17 kg (37.4 Lbs), the pathological diagnosis was myxoid liposarcoma with normal histologically adrenal and kidney (Figure 3). There were no postoperative complications. Later the patient remained asymptomatic, without recurrence signs in the CT-scan during 12 months. The patient died of myocardial infarction.



**Figure 1** Laparotomy shows a enormous abdominal mass. The surgeon shows the greater omentum, the colon frame is elongated by the large tumor.



**Figure 2** CT-scan (case 1) which shows a complete filling of the abdominal cavity. CT-scan (case 1) which shows a complete filling of the abdominal cavity.



**Figure 3** Tumor measured 50 X 40 X 25 cm and weighted 17 kg in the patient (case one). Complete removal of all gross tumors was done in both cases. The tumor involved the adrenal gland and left kidney (K).

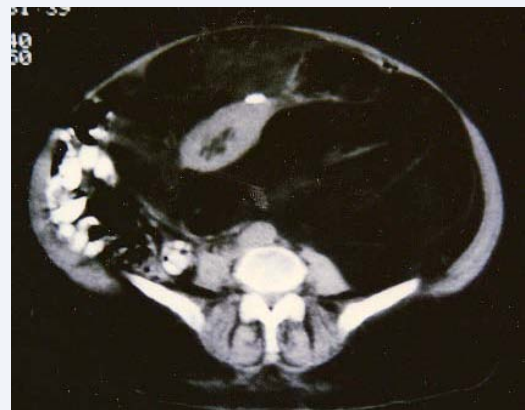## CASE REPORT 2

A 64-years-old woman was admitted to the surgical emergency department with abdominal pain, enlarged abdominal perimeter and postprandial plenitude of five months duration. Physical examination revealed a globular abdomen due to a large mass that completely filled it up. The emergency US showed a homogeneous mass from upper left flank, filling the entire abdominal cavity and displacement of digestive tract to the right. CT-scan, intravenous pyelography, arteriography

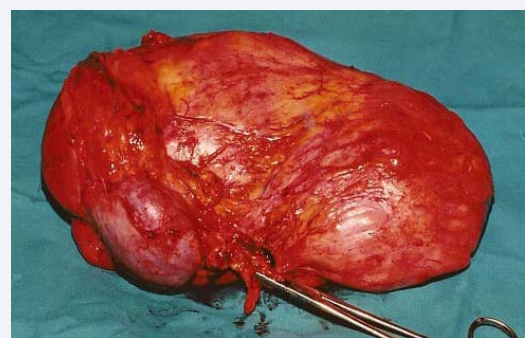
and cavography confirmed the retroperitoneal origin, with modified left kidney position, no involvement of large vessels was found and the tumor showed little vascularization (Figure 4). Fine needle aspiration biopsy guided by CT-scan disclosed a myxoid liposarcoma. Chromosomal study of peripheral blood lymphocytes was performed preoperatively. The patient was operated, finding a large tumor of 35 X 33 X 20 cm in the left retroperitoneum. The tumor caused an important pancreas and right colon displacement, the left kidney and adrenal gland were lumped together within the tumor. The tumor weighed 13 kg (28.6 Lbs), the histopathological diagnosis was confirmed, adrenal gland and kidney was normal. There were no postoperative complications, nineteen months later the patient remained asymptomatic without recurrence in the CT-scan. The patient died by chronic renal failure.

## Processing and study of peripheral blood

Five centimeters of peripheral blood was extracted under sterile conditions and collected in heparin-lithium tubes. Four lymphocyte cultures were performed for each sample. 1. Culture of 72 hours in RPMI-1640 medium; to determine the constitutional karyotype of both patients. 2. Culture of 96 hours in medium 199 poor in folic acid, searching chromosome fragility. 3. Culture of 72 hours of synchronization with methotrexate and thymidine. 4. Culture of 72 hours with ethidium bromide to obtain high resolution bands. Colchicine was added to the cultures. Hypotonic shock and fixation of the material were done



**Figure 4** CT-scan shows a large retroperitoneal tumor involving the kidney.



**Figure 5** Case two; Tumor of 35 X 33 X 20 cm and weighed 13 kg (28.6 Lbs).

according to the standard protocols for modified amniotic fluid. The metaphases were analyzed according to the pattern of G bands and polymorphisms were checked in C.

### Karyotype results

**Case 1:** A total of 90 metaphases were studied, the karyotype was 46XX. In 21 cells (19%) 16qbreakagewas observed

**Case 2:** A total of 30 metaphases were studied, the karyotype was 46XX. In 3 cells (10%) 16 qbreakagewas observed.

### DISCUSSION

Liposarcomas are malignant tumors originating from adipose tissue [3,4]. They have a high incidence among sarcomas and represent the second most frequent soft tissue sarcoma of adult life. It is difficult to make an early diagnosis of retroperitoneal tumors, due to their anatomic location and none explicitly orientated clinical symptoms, being the reason they reach large proportions before the diagnosis [5]. Symptomatology of these tumors includes abdominal pain associated with a palpable abdominal mass and weight loss. Because of these clinical symptoms, a retroperitoneal tumor can be suspected, which can be confirmed by complementary studies. However, the final confirmation can only be made on the surgery and through a pathological study [6]. A new diagnostic parameter is a chromosomal analysis of the tumor cells. The specific cytogenetic findings in the myxoid liposarcoma are a reciprocal translocation  $t(12; 16)(q13.3; p11.2)$  [7]. Descriptions of primary (specific) alterations in peripheral blood (lymphocytes) in patients with giant retroperitoneal myxoid liposarcoma have not been reported in the literature. In these two patients, an increase in 16q breaks was found. The presence of fragility and chromosome rupture invites to translocations and chromosome recombination. CT-scan is the most reliable and cost effective diagnostic test in this type of tumors, it has the highest reliability about tumor size, consistency and relationship with the retroperitoneal organs. Periodic postoperative CT-scan is useful to detect early recurrences. An intravenous pyelography should be carried out routinely prior the surgery of patients with retroperitoneal tumors, in order to determine the position of the ureter and renal function, since the associated nephrectomy is of 71% when a radical exeresis is performed [1]. Angiography is useful in providing a panoramic view of the upper mesenteric, the renal and celiac trunk arteries; the origin of the vessels that irrigate the tumor and its relationship with the great vessels and retroperitoneal organs. This test can be conclusive even in those cases where the CT-scan is not definitive for its location [8]. The cavography discloses involvement of both inferior vena cava and renal veins [9]. The fine needle aspiration biopsy guided by US or CT-scan can be oriented on the mesenchymal origin of the lesion [3,10]. The retroperitoneal tumors are an important surgical challenge. Total tumors surgical extirpation is not possible in 25% to 65% of cases [1,3,8,9]. The retroperitoneal sarcomas resection is determined by the tumor size and its anatomic relationships, making necessary to extirpate also the adjacent organs [9]. There is no doubt on the role of surgery in the treatment of retroperitoneal liposarcomas, nowadays in literature are reported some studies about a save of adjacent organs, especially the kidney in the well differentiated liposarcoma.

Laparotomy is the only positive way to determine the need for resection of a retroperitoneal tumor, and to make the histological diagnosis. From a technical point of view the two cases are similar. The approach was performance through supra-umbilical incision along the midline, which is the ideal for these types of lesions. Since the tumor enclosed the kidney it was necessary to control the renal vascular pedicle once the left colon and its meso had been mobilized. Other abdominal and retroperitoneal organs were only displaced. Vascular detachment constitutes the greatest risk during the dissection due to the considerable tumors weight. It is therefore necessary to ensure adequate support of the growth while it is being resected. It was not deemed necessary or convenient to effect drainage or to peritonize. The only effective and successful therapy is the complete removal of all gross tumors, so as to ensure a rate survival up of 5 years in 40% to 70% of cases. If surgical removal is not carried out, the survival rate up of 5 years is only of 5%. Even when surgical removal has been accomplished, death, in most patients, is caused by high recurrence rate in order of 43% to 82% [9]. It was not considered necessary radiotherapy or chemotherapy for both patients. At any rate there does not seem to be enough evidence to substantiate their efficacy, based on the literature that the role of adjuvant chemotherapy or radiotherapy in myxoid liposarcoma is not well defined [11]. Surgery is the main treatment of non-metastatic retroperitoneal liposarcomas, when it is possible, the macroscopically complete resection should be the goal of the surgeon. Often required resection of the adjacent block, such as the colon, psoas muscle, small intestine and kidney. In both patients pretreatment biopsy was performed, either received radical surgery (block resection) without leaving any tissue that was attached to the tumor (not flay), this could be the main factor for the high survival of these patients. The histologic exam of kidney and adrenal gland were free of disease. Therefore in in both cases was necessary to perform an R0 resection. The patients died for other causes not strictly related to the progression of the liposarcoma, but especially the second patient presented a late complication due to the extended surgery: the chronic renal failure. In a recent article Jun Yang et al. [12], discussed about the possibility to a R0 resection of a well differentiated liposarcoma with right kidney preserving, just like "peel off" the tumor from the kidney. The idea to preserve the organs may be bear in mind with the possibility of a more conservative treatment on the nearby organs in the treatment of low-grade retroperitoneal liposarcoma (well-differentiated) reducing related morbidity and mortality.

About the chromosome 16q breakage, may be this is the first study about alterations in peripheral blood cells attributable to giant retroperitoneal myxoid liposarcoma, and it could be interesting for further studies, unfortunately, this type of exam could not be routinely applicable in this way: first relatively costly and laborious, second the identifications of chromosome 16q breakage is not only specific for myxoid liposarcoma, so it cannot be justified on large scales of patients as diagnostic routine exam because the rupture of chromosome 16q can be found in other human neoplasia as: Ewing sarcoma, peripheral primitive neuroepithelial tumor (PNET), myxoid liposarcoma, rhabdomyosarcoma, acute lymphoblastic leukemias (ALL), acute mixed leukemia, breast cancer, endometrial adenocarcinoma,



myelodysplastic syndromes, acute myeloid leukemia, retinoblastoma, and Wilms' tumor. However, PCR-based methods or fluorescence in situ hybridization techniques may be used to examine a specific region of chromosome 16q.

## CONCLUSION

Retroperitoneal liposarcoma is a un common disease with a high rate of recurrence. Apparently may be associated with the chromosome 16breakage. Complete resection is the predominant treatment; however, combined resection of adjacent organs must be considered.

## REFERENCES

1. Singer S, Antonescu CR, Riedel E, Brennan MF. Histologic subtype and margin of resection predict pattern of recurrence and survival for retroperitoneal liposarcoma. *Ann. Surg.* 2003; 238: 358-371.
2. de Vreeze RS, de Jong D, Koops W, Nederlof PM, Ariaens A, Haas RL, et al. Oncogenesis and classification of mixed-type liposarcoma: a radiological, histopathological and molecular biological analysis. *Int J Cancer.* 2011; 128: 778-786.
3. Antinori A, Antonacci V, Magistrelli P. Giant retroperitoneal liposarcoma. *Am J Surg.* 2002; 184: 56-57.
4. Lewis JJ, Leung D, Woodruff JM, Brennan MF. Retroperitoneal soft-tissue sarcoma: analysis of 500 patients treated and followed at a single institution. *Ann Surg.* 1998; 228: 355-365.
5. Caizzone A, Saladino E, Fleres F, Paviglianiti C, Iaropoli F, Mazzeo C, et al. Giant retroperitoneal liposarcoma: Case report and review of the literature. *Int J Surg Case Rep.* 2015; 9: 23-26.
6. Tseng WW, Madewell JE, Wei W, Somaiah N, Lazar AJ, Ghadimi MP, et al. Locoregional disease patterns in well-differentiated and dedifferentiated retroperitoneal liposarcoma: implications for the extent of resection? *Ann. Surg. Oncol.* 2014; 21: 2136-2143.
7. Rachel Conyers, Sophie Young, David M Thomas. Liposarcoma: Molecular Genetics and Therapeutics. *Sarcoma.* 2011; 2011: 13.
8. Gemici K, Buldu I, Acar T, Alptekin H, Kaynar M, Tekinarslan E, et al. Management of patients with retroperitoneal tumors and a review of the literature. *World J Surg Oncol.* 2015; 13: 143-147.
9. Lucas E, Matthyssens, David Creyten, Wim P. Ceelen. Retroperitoneal Liposarcoma: Current Insights in Diagnosis and Treatment. *Front Surg.* 2015; 2: 4-8.
10. ESMO/European Sarcoma Network WG. Soft tissue and visceral sarcomas: ESMO clinical practice guidelines for diagnosis, treatment and follow-up. *Ann Oncol.* 2012; 23: 92-99.
11. Mc Callum OJ, Burke JJ, Childs AJ. Retroperitoneal liposarcoma weighing over one hundred pound with review of the literature. *Gynecol Oncol.* 2006; 103: 1152-1154.
12. Yang J, Zhao Y, Zheng CH, Wang Q, Pang XY, Wang T, et al. Huge retroperitoneal liposarcoma with renal involvement requires nephrectomy: A case report and literature review. *Mol Clin Oncol.* 2016; 5: 607-609.

### Cite this article

Gálvez-Valdovinos R, Felipe Cruz-Vigo M, Martínez-Pueyo JI, Santillan E (2017) Giant Retroperitoneal Myxoid Liposarcomas, Survival in Chromosomal Fragility. *JSM Gen Surg Cases Images* 2(1): 1019.