

Research Article

Testicular Haematoma in Haemophilia. The Importance of Evaluation through Magnetic Resonance (MR)

Caviglia Horacio^{1,2}, Lescano Sebastián³, Bacigalupo Roberto⁴, Pérez Ballester Gustavo⁵, Landro María Eulalia^{1*}, Douglas Price Ana Laura¹, Neme Daniela², and Ghissi Pablo³

¹Department of Orthopaedic Surgery and Traumatology, Fernández General Hospital, Argentina

²Haemophilia Foundation, Argentina

³Department of Magnetic Resonance, Fernández General Hospital, Argentina

⁴Department of Urology, Fernández General Hospital, Argentina

⁵Department of Ultrasound, Fernández General Hospital, Argentina

***Corresponding author**

Landro ME, Department of Orthopaedic Surgery and Traumatology, Fernández General Hospital, Cerviño 3356, 3rd floor (C1425APF), Buenos Aires-Argentina, Email: mlandro@gmail.com; traumatoyortopedi Fernandez@gmail.com

Submitted: 11 October 2017

Accepted: 06 November 2017

Published: 17 November 2017

ISSN: 2333-6684

Copyright

© 2017 Eulalia et al.

OPEN ACCESS

Keywords

- Testicular haematoma
- Ultrasound
- Magnetic resonance
- Haemophilia

Abstract

Introduction: Differential diagnosis of testicular haematoma is a challenge. Testicular haematoma in patients with haemophilia is still more complicated. In PWH with testicular enlargement without previous trauma, an underlying condition such as an abscess, cyst, tumours, and peri-testicular pathologies can be suspected. Testicular sonography has become the imaging technique of choice, not only for differential diagnosis of a variety of pathologic processes with similar clinical manifestations, but also for diagnosis and monitoring of testicular trauma.

The aim of this work was to evaluate the clinic usefulness of magnetic resonance (MR) imaging for correct diagnosis of testicular haematoma.

Patients and methods: Two haemophilia type A severe patients were evaluated. Both patients presented pain and enlargement of testicles after micro trauma. The first one was a 24 year-old patient, who referred a micro trauma during sexual intercourse in the right testicle. The second was a 43 year-old patient, who referred a micro trauma during horse riding in the left testicle. A well-circumscribed mass was visible in the testicles and β -chain chorionic gonadotropin and α -fetoprotein blood tests were negative in both patients. MRI study confirmed the diagnosis of testicular hematoma.

Results: Both patients responded positively to conservative treatment with factor VIII replacement therapy. Pain and testicle size were reduced and hemosiderine reabsorption improved.

Discussion: Intratesticular haematoma caused by micro trauma is difficult to diagnose. We now report two patients who were correctly diagnosed by ultrasound and MRI and conservatively treated and monitored until their testicular haematomas disappeared. We suggest that MRI is a useful and essential tool in the diagnosis of scrotal and testicular abnormalities, and their evolution and response to treatment.

Conclusion: This work shows that with correct diagnostics and suitable images like MRI and ultrasound, haematoma of the testicle can be diagnosed, resolved and followed-up with conservative treatment.

INTRODUCTION

Differential diagnosis of testicular haematoma is a challenge in daily clinical practice. Testicular haematoma in patients with haemophilia (PWH) is still more complicated. Acute hematoma of the testis is easy to diagnose, because there is a traumatic antecedent and testicular enlargement due to intraparenchymatous haematoma. On the other hand, intratesticular hematoma caused by micro trauma is difficult to diagnose because there is no previous acute trauma and the growth of the testis is slow and may be mistakenly attributed to another testicular intraparenchymal process.

In patients with haemophilia with testicular enlargement

without previous trauma, an underlying condition such as an abscess, cyst, tumours, and peri-testicular pathologies can be suspected. Abscesses, cysts and peri-testic pathologies are easily diagnosed by ultrasonography [1,2]. It is difficult to differentiate tumours from chronic growth testicular hematomas.

A negative β -chain chorionic gonadotropin and α -fetoprotein blood test, reduces the possibility of tumour existence, but does not rule it out.

Testicular sonography has become the imaging technique of choice, not only for differential diagnosis of a variety of pathologic processes with similar clinical manifestations, but also for diagnosis and monitoring of testicular trauma.

When ultrasound of the testis is performed to differentiate tumours from haematomas, the presence of evident circulation in the parenchymal mass facilitates the diagnosis of tumour, but its absence does not discard it. In this situation many urologists perform testicular puncture to define the diagnosis. If a tumour cannot be ruled out, an orchiectomy is performed.

The aim of this work was to evaluate the clinic usefulness of magnetic resonance (MR) imaging for correct diagnosis of testicular haematoma.

PATIENTS AND METHOD

Two patients were evaluated. Both patients were haemophilia type A severe without inhibitors with pain and enlargement of testicles after micro trauma.

The first one was a 24 year-old patient, who referred a micro trauma during sexual intercourse in the right testicle. The second was a 43 year-old patient, who referred a micro trauma during horse riding in the left testicle.

In both patients the diagnosis was by testicular ultrasound (Philips® HD 15) with a 5- to 12-MHz linear transducer.

A well-circumscribed mass was visible in the testicles of both patients. The mass was surrounded by a hypo echoic halo measuring 1.5 to 2.0 mm and it contained debris with multiple small septa (Figure 1).

β -chain chorionic gonadotropin and α -fetoprotein blood tests were negative (α -fetoprotein < 15 mg/ml) in both patients. β -chain chorionic gonadotropin levels are never found in normal men. When the presence is detected in serum it always indicates a malignancy.

MRIs (MR General Electric® HDXT 1.5 Tesla) were also performed in both patients. The MRIs showed an intratesticular mass, with low signal intensity on T2-weighted images, and high signal intensity hypointense on the T1-weighted image, and a low-signal-intensity with gradient-echo T2, loss of signal intensity caused by the presence of haemosiderin. MRI study confirmed the diagnosis of testicular hematoma (Figure 2).

We also performed a retrospective study of our database and we found three patients with testicular enlargement. Ultrasounds performed in these patients showed a well-circumscribed mass in the testicle surrounded by a hypo echoic halo. β -chain chorionic gonadotropin and α -fetoprotein blood tests were negative in all patients.

When a tumour is suspected, after ultrasonography, blood is extracted to study of markers, and without waiting the result, surgical exploration is performed through the inguinal route. Prior to clamping the cord, a frozen section biopsy was done, if it cannot be definitively ruled out that there is a tumor; orcheoctomy is performed [3].

RESULTS

Both patients responded positively to conservative treatment with factor VIII replacement therapy (2,000 Units 3 times a week for 8 weeks). Pain and testicle size were reduced and haemosiderine reabsorption improved.

After a positive ultrasound, an organized intratesticular hematoma was strongly suspected. Ultrasound and MRI were performed to rule out other possibilities, and to monitor the haematoma it disappeared (Figure 3).

The follow-up MRIs showed decrease in size of the lesion.

In both cases of testicular haematoma after micro trauma MRIs detected the haemosiderin in the haematoma, confirming the diagnosis.

The three patients in the data base were orchiectomized because diagnoses are not definitive. The definitive biopsy revealed a haematoma.

DISCUSSION

Acute haematoma of the testis is easy to diagnose, because there is a traumatic antecedent and testicular enlargement. Intratesticular haematoma caused by micro trauma is difficult to diagnose.

Differential diagnosis for intratesticular haematomas included: intratesticular retention cysts, epidermoid cysts, lymphomas, and testicular neoplasms.

We report two cases of well-circumscribed intratesticular hematoma after a micro trauma which appears to be a testicular mass on sonography. Because of their location, intratesticular haematomas and contusions may mimic a testicular tumour.

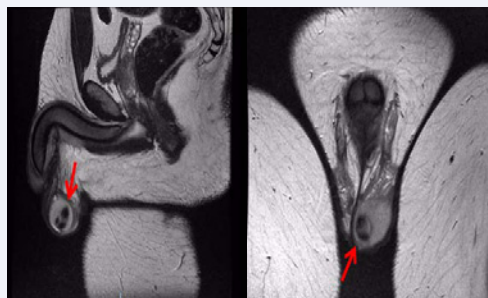


Figure 1 Testicular haematoma.

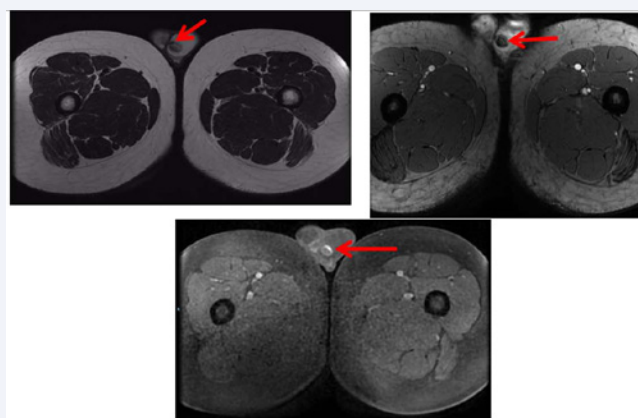


Figure 2 A 24-year-old man with left-sided haematoma, correctly localized and characterized with MR. Coronal T2-weighted (left), GRE sequence (center), and T1-weighted fat-suppressed (right).

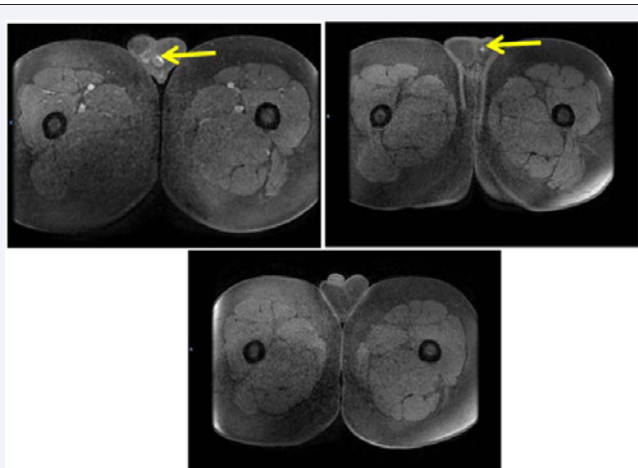


Figure 3 A follow-up. MR study has been obtained in 1 to 8 months. Axial and T1-weighted fat-suppressed show progressive reduction in size and signal of de lesions.

A hematoma is avascular, and its appearance changes rapidly [4,5]. Tumors and inflammation are vascular, with a tendency to remain stationary in size or to enlarge [4]. There is no evidence of predisposition to malignancy after trauma, but a previously unidentified abnormality may be detected [6].

Singh et al., showed intratesticular hematomas usually develop immediately after orchiectomy is done for testicular tumours and may last for 3 to 6 weeks or longer. They may be confused with local recurrence on clinical examination and imaging. However, on color Doppler ultrasonography of the scrotum, the mass is confirmed to be a hematoma [4]. Seidenwurm et al., performed MRIs of the scrotum on 13 patients with intrascrotal pathologic conditions and seven healthy subjects. The MRI signals obtained on T1- and T2-weighted images allowed differentiation of testis from epididymis and spermatic cord. Masses were differentiated from normal testicular parenchyma in all cases. Atrophic or ischemic testes had lower signal intensity than normal testes on T2-weighted images. Hematoma displayed a characteristic high intensity on both T1- and T2-weighted images. Intratesticular and extra testicular pathologic conditions were readily differentiated [7]. In addition, our own experience showed three patients with similar characteristics of testicular injury, diagnosed only

by ultrasound whose testicles were needlessly removed as their biopsy results were not definitive. Pathology reports later confirmed a haematoma.

We now report two patients who were correctly diagnosed by ultrasound and MRI and conservatively treated and monitored until their testicular haematomas disappeared.

We suggest that MRI is a useful and essential tool in the diagnosis of scrotal and testicular abnormalities, and their evolution and response to treatment [8]. To our knowledge, little has been written in the literature on the subject of well-circumscribed traumatic intratesticular haematomas because of their rarity. Even less has been written about these haematomas in patients with haemophilia even in reviews of scrotal trauma.

CONCLUSION

This work shows that with correct diagnostics and suitable images like MRI and ultrasound, haematoma of the testicle can be diagnosed, resolved and followed-up with conservative treatment.

REFERENCES

1. Pavlica P, Barozzi L. Imaging of the acute scrotum. *Eur Radiol.* 2001; 11: 220-228.
2. Oyen RH. Scrotal ultrasound. *Eur Radiol.* 2002; 12: 19-34.
3. Cáncer de testículo. Algoritmo diagnóstico y terapéutico. Federación Argentina de Urología. Secretaría Científica. Capítulo de Urooncología. 2002
4. Singh H, Sharma P, Suman KCS, Reddy RM, Bal C, Malhotra A, et al. Postorchiectomy intrascrotal hematoma mimicking local recurrence on 18F-FDG PET/CT: a diagnostic dilemma. *Clin Nucl Med.* 2012; 37: 102-103.
5. Bhatt S, Ghazale H, Dogra VS. Sonographic evaluation of scrotal and penile trauma. *Ultrasound Clin.* 2007; 2: 45-56.
6. Stenos J, Karanastasis D, Antoniou N. Intratesticular hemorrhage mimicking a tumor. *Acta Urol Belg.* 1990; 58: 193-196.
7. Seidenwurm D, Smathers R, Lo R, Carrol C, Bassett J, Hoffman R. Testes and scrotum: MR imaging at 1.5 T. *Radiology.* 1987; 164: 393-398.
8. Megremis S, Michalakou M, Mattheakis M, Agianniotakis E, Sfakianaki E. Unusual Well-Circumscribed Intratesticular Traumatic Hematoma Diagnosis and Follow-up by Sonography. *J Ultrasound Med.* 2005; 24: 547-550.

Cite this article

Horacio C, Sebastián L, Roberto B, Gustavo PB, Eulalia LM, et al. (2017) Testicular Haematoma in Haemophilia. The Importance of Evaluation through Magnetic Resonance (MR). *J Hematol Transfus* 5(4): 1071.