

## Case Report

# Ehlers Danlos Syndrome and Polymicrogyria: An Uncommon Association

Salma Sakka, Rafik Machraoui\*, Nouha Bouzidi, Mariem Damak, and Chokri Mhiri

Department of Neurology, Habib Bourguiba University Hospital, Tunisia

## \*Corresponding author

Rafik Machraoui, Department of Neurology, Habib Bourguiba University Hospital, Tunisia, Tel: 0021-6229-397-25; Email: rafikmachraoui@LIVE.COM

Submitted: 07 February 2017

Accepted: 12 April 2017

Published: 14 April 2017

## Copyright

© 2017 Machraoui et al.

## OPEN ACCESS

## Keywords

- Ehlers-Danlos syndrome
- Polymicrogyria
- Nervous system complications

## Abstract

Ehlers–Danlos syndrome (EDS), vascular type is characterized by thin, translucent skin, easy bruising characteristic of facial appearance and arterial, intestinal and / or uterine fragility. Neurological manifestations such as epilepsy are rare. It is due especially to structural abnormalities. Polymicrogyria is one of the rare causes of epilepsy that had been reported in few cases in the literature. We reported the case of a 20-year-old man with the familial history of vascular type of Ehlers Danlos syndrome (EDS). He was admitted to our medical unit at the age of 19 years for generalized tonic- seizure lasting about 3 minutes starting with staring and altered consciousness. Brain magnetic resonance imaging showed bilateral fronto-parietal polymicrogyria. EDS is rarely associated with polymicrogyria. Only five cases were reported in the literature.

## ABBREVIATIONS

EDS: Ehlers Danlos Syndrome; PH: Periventricular Heterotopia; EEG: Electroencephalography

## INTRODUCTION

Ehlers-Danlos syndrome (EDS) is a group of heterogeneous genetic disease having in common connective skin hyper extensibility, a joint hyper mobility and tissue fragility. Different types have been individualized [1]. All forms of the syndrome cause clinical problems, such as skin fragility, unsightly bruising, and scarring, musculoskeletal.

Discomfort and susceptibility to osteoarthritis. With the exception of type IV, the EDS are associated with normal life expectancy. The main features of EDS are recognized by specialists. However neurological complications are not well known. Although in some cases these complications threaten the patient's prognosis. Cerebrovascular complications are common and include intracranial aneurysms, subarachnoid hemorrhage, spontaneous arterial dissection and cavernous sinus fistula. Other neurological manifestations are less well known [2-4].

Epilepsy in Ehlers-Danlos syndrome (EDS) has been reported in the literature, due especially to structural anomalies often with periventricular heterotopia (PH) [5-13]. Abnormal anatomic circuitries (including heterotopic nodules) could generate epilepsy in patients with PH. Polymicrogyria has been reported as a rare cause of epilepsy in Ehler Danlos syndrome [14,15]. Among the principal neurological manifestations, epilepsy

and polymicrogyria have a considerable importance and can influence the long-term evolution of these patients. Until now the neurological symptoms have not been studied in detail; therefore, the aim of this review is to analyze the possible association between EDS and polymicrogyria.

Few cases have been reported in the literature.

## CASE PRESENTATION

We reported the case of 20-year-old man who was born from a second-degree consanguineous parentage. He had hyper elastic skin (Figure 1), without hyper extensible joints with positive thumb and wrist sign, hematomas result of repeated minor trauma (Current trauma during sports, minimal contusions during domestic activities). There was a history of similar case in his elder brother and his father. Diagnosis of EDS was considered and genetically confirmed. His father was died from rupture of abdominal aortic aneurysm and his brother had an ischemic stroke caused by dissection of carotid artery.

He was admitted to our medical unit at the age of 19 years for generalized tonic- activity lasting about 3 minutes starting with staring and altered consciousness. He developed two similar generalized seizures after admission of which the durations were about 2 minutes each. There was no fever. Neurological examination after the seizures was normal.

Routine lab tests were normal such as blood glucose, serum sodium, renal function tests and serum calcium. Post actual Electroencephalography (EEG) showed right focal fronto-parietal

spikes. Brain magnetic resonance imaging showed bilateral frontoparietal polymicrogyria (Figure 2). This seizure was resistant to valproate treatment and requires the addition of clobazam.

## DISCUSSION

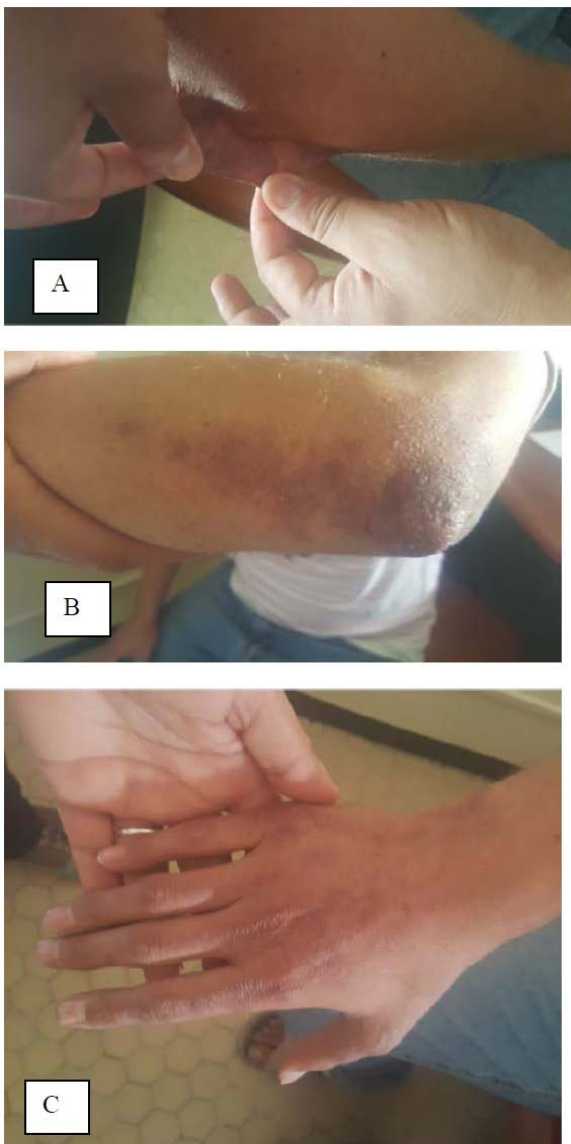EDS is a group of heritable connective tissue due to abnormalities in secretion and synthesis of fibrillar collagens. This rare disease that affects 1/5000 with variability between the different types [16]. Six different EDS subtypes were recognized according to the actual classification underlying biochemical and molecular insights: classical, hypermobility, vascular type, kyphoscoliosis, arthrochalasia, and dermatosparaxis [1]. The most commonly seen of these type were Vascular manifestations or EDS type IV. Vascular Ehlers-Danlos syndrome is a rare and severe connective tissue disorder caused by mutations in the collagen type III alpha 1 chain (COL3A1) gene. It is an autosomal-

dominant disorder caused which leads to ruptures of arteries and hollow organs and characterized by thin, skin fragility, unsightly bruising, vascular dissection or rupture of aneurysm, arteriovenous fistulae or dissection [1,17,18]. COL3A1, encoding type III collagen, is situated on the long arm of chromosome 2 in position 2q24.3-q31. The clinical and genetic diagnoses of the prob and suggest the possibility of familial vascular EDS and was confirmed by genetic testing of COL3A1 [17]. This Family has many vascular complications. In fact, the father had an abdominal aortic aneurysm, the rupture of which was the cause of death in the latter. His brother was admitted in our department for vertebral dissection causing stroke.

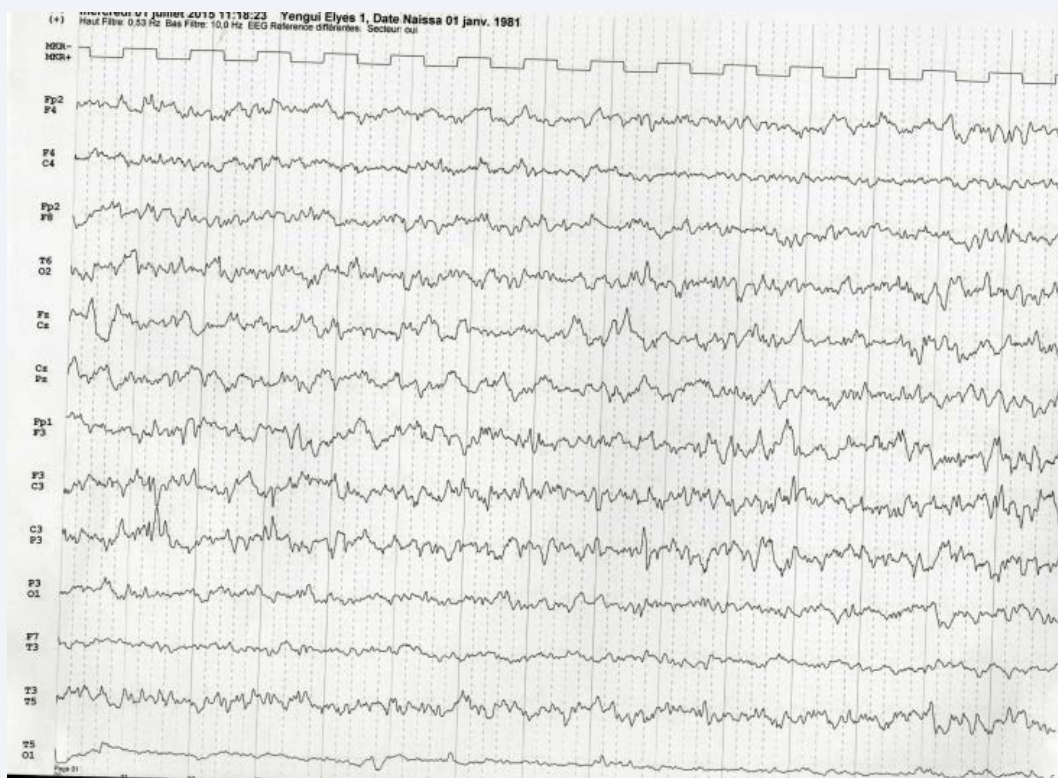
Unlike these vascular complications, Neurological manifestations were rare and were characterized by recurrent headache with increased prevalence of migraine, cerebrovascular disorders. chronic pain syndrome, peripheral neuropathy, plexopathy, periventricular heterotopia, spontaneous intracranial hypotension, idiopathic intracranial hypertension and epilepsy [2,6,16].

Epilepsy was reported in people with Ehlers-Danlos syndrome [11,18] with or without brain lesions. The physiopathology of epilepsy in this case is not well known. The first case had been reported in 1981 by Cupo and al [19] due to cerebral heterotopias. Then, other cases have been reported due to possible nervous system determinants for seizures include basilar artery hypoplasia, hemispheric atrophy, previous intracranial bleed, previous stroke venous, parietal angioma and agenesis of the corpus callosum [20,21]. However, most often it is associated with a structural anomaly especially periventricular heterotopia but also some cases of polymicrogyria were reported [12]. Polymicrogyria is one of the most common malformations of cortical development. It is characterized by the appearance of an excessive number of small cortical folds, often fused together, with disordered cortical lamination. The perisylvian regions were the most common location of polymicrogyria across the cortex. Many other regions have been reported such as frontal or temporal cortex. It is due to interruption of the late step of neuronal migration or early post migrational development period [22].

The first two cases that have been reported in 2000 redof two children and whose epilepsy was symptomatic of polymicrogyria. In one case seizures were drug resistant. In 2005 Ezzeddine and al [20] described an uncommon association between EDS and bilateral frontal polymicrogyria in a 3-years girl in which neuropsychological assessment highlighted an overall delay of acquisitions with many arguments of a frontal syndrome (hyperkinetic, attention deficit, unpredictable mood swings, imitative behavior, perseveration). In 2014 Verroti and al [12] studied 42 patients with EDS, in this cases epilepsy was frequently associated with periventricular heterotopias (PH) and only two patients have polymicrogyria (Table 1) [6,23]. These reports suggest a likely increased rate of epilepsy in EDS. The association of EDS type IV with a disorder of cortical organization such as Polymicrogyria was due to abnormalities of the synthesis of various extracellular matrix (ECM) [18]. Collagen seem to have an important role for neurological growth, migration, metabolism and differentiation [24]. Some authors suggest that the interaction between epidermal growth factors and ECM are



**Figure 1** [A] hyper elasticity of the skin; [B and C] hematomas in the elbow and the hand resulting of repeated minor traumas.



**Figure 2** EEG showing right frontoparietalspikes.

**Table 1:** Clinical features of patients with polymicrogyria in EDS.

Authors		Sex	Age of onset (Years)	Clinical manifestation	MRI	EEG	Treatment
Laguna and al-2000	Case 1	M	10	Focal epilepsy	Bilateral Frontocentral polymicrogyria	Left frontotemporal Sharp wave discharges	carbamazepine
	Case 2	F	1	Epilepsy: Spasm Generalized seizure	Bilateral sylvianpolymicrogyria	-	Multiple Antiepileptic drug
Ezzeddine and al 2005		F	3	Frontal syndrome	Bilateral frontal polymicrogyria	-	-
Verrotti and al 2014	Case 1	F	4.3	Epilepsy: Generalized tonic clonic seizure	Temporal polymicrogyria	Right centroparietal spike and wave	Valproate oxcarbamazepine
	Case 2	F	7.3	Epilepsy: Focal motor seizure	polymicrogyria	Left focal seizure	Topiramate valproate

necessary for the differentiation of cortical neurons and it was proved in experimental researches [16]. A mutation in the gene of tenascin proteins or collagen implicated in EDS caused a cortical malformation such as bilateral focal polymicrogyria.

In case of brain abnormality epilepsy is characterized by previous onset of seizure, even focal epilepsy and drug resistance. The poor seizure control in patients with structural central nervous system is associated with a poor outcome [12]. Ictal and inter-ictal EEG showed focal abnormalities in most cases. These abnormalities disappear under antiepileptic treatment and could persist in the case of structural abnormalities.

## CONCLUSION

EDS may cause neurological disorders such as pain, peripheral neuropathy, and neuromuscular involvement. Epilepsy is a rare neurological feature that may be associated with EDS. The cases reported in literature showed frequently PH. Through this case, were ported a particular and rare association of EDS and polymicrogyria with epilepsy which began at a late age. It is important to understand the pathological mechanisms that lead to epilepsy in these patients to have better long term outcome.



## REFERENCES

1. Beighton P, De Paepe A, Steinmann B, Tsipouras P, Wenstrup RJ. Ehlers-Danlos syndromes: revised nosology, Villefranche, 1997. Ehlers-Danlos National Foundation (USA) and Ehlers-Danlos Support Group (UK). *Am J Med Genet.* 1998; 77: 31-37.
2. Mathew T, Sinha S, Taly AB, Arunodaya GR, Srikanth SG. Neurological manifestations of Ehlers-Danlos syndrome. *Neurol India.* 2005; 53: 339-341.
3. Debette S, Germain DP. Neurologic manifestations of inherited disorders of connective tissue. *Handb Clin Neurol.* 2014; 119: 565-576.
4. Henderson FC Sr, Austin C, Benzel E, Bolognese P, Ellenbogen R, Francomano CA, et al. Neurological and spinal manifestations of the Ehlers-Danlos syndromes. *Am J Med Genet C Semin Med Genet.* 2017; 175: 195-211.
5. Sheen VL, Jansen A, Chen MH, Parrini E, Morgan T, Ravenscroft R, et al. Filamin A mutations cause periventricular heterotopia with Ehlers-Danlos syndrome. *Neurology.* 2005; 64: 254-262.
6. Savasta S, Merli P, Ruggieri M, Bianchi L, Spartà MV. Ehlers-Danlos syndrome and neurological features: a review. *Childs Nerv Syst.* 2011; 27: 365-371.
7. Jacome DE. Epilepsy in Ehlers-Danlos syndrome. *Epilepsia.* 1999; 40: 467-473.
8. Gómez-Garre P, Seijo M, Gutiérrez-Delgado E, Castro del Río M, de la Torre C, Gómez-Abad C, et al. Ehlers-Danlos syndrome and periventricular nodular heterotopia in a Spanish family with a single FLNA mutation. *J Med Genet.* 2006; 43: 232-237.
9. Cupo LN, Pyeritz RE, Olson JL, McPhee SJ, Hutchins GM, McKusick VA. Ehlers-Danlos syndrome with abnormal collagen fibrils, sinus of Valsalva aneurysms, myocardial infarction, panacinar emphysema and cerebral heterotopias. *Am J Med.* 1981; 71: 1051-1058.
10. Pretorius ME, Butler IJ. Neurologic manifestations of Ehlers-Danlos syndrome. *Neurology.* 1983; 33: 1087-1089.
11. Thomas P, Bossan A, Lacour JP, Chanalet S, Ortonne JP, Chatel M. Ehlers-Danlos syndrome with subependymal periventricular heterotopias. *Neurology.* 1996; 46: 1165-1167.
12. Verrotti A, Spartà MV, Monacelli D, Porto R, Castagnino M, Russo Raucci A, et al. Long-term prognosis of patients with Ehlers-Danlos syndrome and epilepsy. *Epilepsia.* 2014; 55: 1213-1219.
13. Savasta S, Verrotti A, Spartà MV, Foadelli T, Villa MP, Parisi P. Unilateral periventricular heterotopia and epilepsy in a girl with Ehlers-Danlos syndrome. *Epilepsy Behav Case Rep.* 2015; 4: 27-29.
14. Ezzeddine H, Sabouraud P, Eschard C, El Tourjuman O, Bednarek N, Motte J. [Bilateral frontal polymicrogyria and Ehlers-Danlos syndrome]. *Arch Pediatr.* 2005; 12: 173-175.
15. Echaniz-Laguna A, de Saint-Martin A, Lafontaine AL, Tasch E, Thomas P, Hirsh E, et al. Bilateral focal polymicrogyria in Ehlers-Danlos syndrome. *Arch Neurol.* 2000; 57: 123-127.
16. Kim ST, Brinjkji W, Lanzino G, Kallmes DF. Neurovascular manifestations of connective-tissue diseases: A review. *Interv Neuroradiol.* 2016; 22: 624-637.
17. Pepin MG, Byers PH. Ehlers-Danlos syndrome type IV. 2011.
18. De Paepe A, Malfait F. The Ehlers-Danlos syndrome, a disorder with many faces. *Clin Genet.* 2012; 82: 1-11.
19. Herrero F. Ehlers-Danlos Syndrome and Epilepsy- A Case-Study, in *Epilepsia.* 1995; 36: 240.
20. Ezzeddine H, Sabouraud P, Eschard C, El Tourjuman O, Bednarek N, Motte J. [Bilateral frontal polymicrogyria and Ehlers-Danlos syndrome]. *Arch Pediatr.* 2005; 12: 173-175.
21. Castori M, Voermans NC. Neurological manifestations of Ehlers-Danlos syndrome(s): A review. *Iran J Neurol.* 2014; 13: 190-208.
22. Barkovich AJ, Guerrini R, Kuzniecky RI, Jackson GD, Dobyns WB. A developmental and genetic classification for malformations of cortical development: update 2012. *Brain.* 2012; 135: 1348-1369.
23. Verrotti A, Monacelli D, Castagnino M, Villa MP, Parisi P. Ehlers-Danlos syndrome: a cause of epilepsy and periventricular heterotopia. *Seizure.* 2014; 23: 819-824.
24. Beighton P, De Paepe A, Hall JG, Hollister DW, Pope FM, Pyeritz RE, et al. Molecular nosology of heritable disorders of connective tissue. *Am J Med Genet.* 1992; 42: 431-448.

### Cite this article

Sakka S, Machraoui R, Bouzidi N, Damak M, Mhiri C (2017) Ehlers Danlos Syndrome and Polymicrogyria: An Uncommon Association. *J Neurol Disord Stroke* 5(1): 1119.