

## CASE REPORT

# A Case Report of Varicella Zoster Virus Angiitis in a Patient Treated with Combination of Acyclovir and Steroids

Ilyas Kamran<sup>1\*</sup>, Ahmad Qistas Malik<sup>2</sup>, Yasir Muhammad<sup>3</sup>, and Khan Nasir<sup>4</sup>

<sup>1</sup>Department of Internal Medicine, Mercy Health Saint Mary's Campus, USA

<sup>2</sup>Department of Internal Medicine, King Edward Medical University, Pakistan

<sup>3</sup>Department of Internal Medicine, King Edward Medical University, Pakistan

<sup>4</sup>Department of Internal Medicine, Mercy Health Saint Mary's Campus, USA

**\*Corresponding author**

Ilyas Kamran, Department of Internal Medicine, Mercy Health Saint Mary's Campus, Grand Rapids, Michigan, USA, Tel: 616-685-6919; Fax: 616-685-3063; Email: kamran.ilyas@mercyhealth.com

Submitted: 14 May 2018

Accepted: 28 May 2018

Published: 10 June 2018

**Copyright**

© 2018 Kamran et al.

**OPEN ACCESS****Keywords**

- VZV
- Immunocompetent
- Acyclovir
- Steroids
- Angiitis
- CNS
- Recovery
- Vasculopathy

**Abstract**

VZV angiitis is a rare manifestation of latent VZV activation. A 68-year-old immunocompetent adult who developed VZV angiitis of CNS was treated with high dose intravenous steroids in addition to the standard acyclovir treatment, this modality of treatment showed rapid improvement in symptoms. VZV angiitis of CNS being very rare has not been studied well; high dose steroids in addition to standard acyclovir treatment can give better clinical outcomes.

**ABBREVIATIONS**

VZV: Varicella Zoster Virus; CNS: Central Nervous System; ESRD: End Stage Renal Disease; IV: Intravenous; CT: Computed Tomography; EF: Ejection Fraction; PVD: Peripheral Vascular Disease; MRSA: Methicillin-Resistant Staphylococcus Aureus; NG: Nasogastric; ICA: Internal Carotid Artery; IM: Intramuscular; PCR: Polymerase Chain Reaction; MRI: Magnetic Resonance Imaging

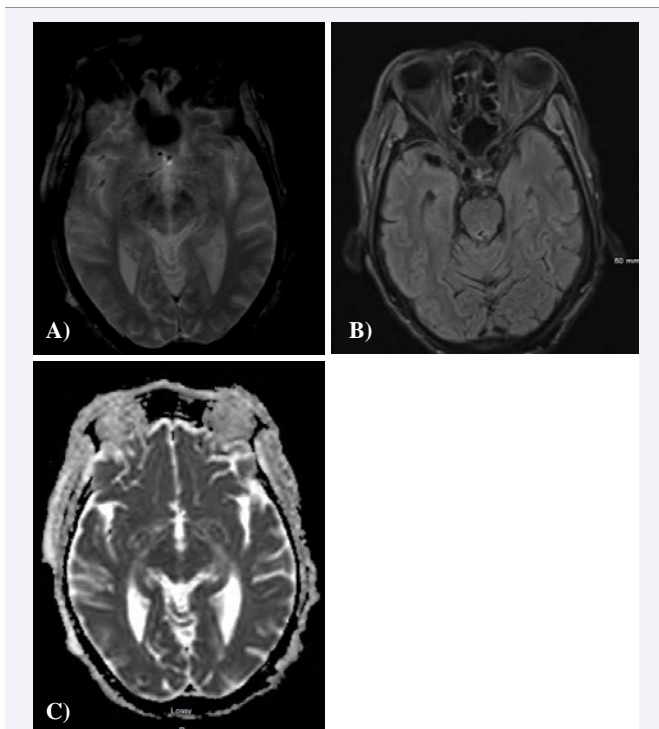
**INTRODUCTION**

VZV-related vasculopathy is extremely rare in immunocompetent patients. To the best of our knowledge there are a very few case reports of VZV-angiitis in immunocompetent adults [1]. We report a case of VZV-angiitis in CNS blood vessels. The presentation of VZV-angiitis can vary depending on the vessels involved, there is no specified treatment protocol for VZV-angiitis as the disease is very rare and much larger prospective studies are still needed. In this case we treated the patient with concurrent high dose steroids in addition to standard antiviral therapy with significant improvement of symptoms.

**CASE PRESENTATION**

We describe the case of a 68-year-old male with a past medical history of combined systolic and diastolic heart failure with EF 40%, cardiac arrest in the past with successful resuscitation, ESRD on hemodialysis, PVD s/p interventions, and restless leg syndrome. He presented to us with shingles in

the right V1 distribution which progressed to preseptal cellulitis and ophthalmitis with marked swelling of the eyelid and non-reactive pupil on the right side with blurred vision. Culture grew MRSA and he was started on IV acyclovir, vancomycin and oral prednisone. A day later he became acutely encephalopathic receiving IM haloperidol for agitation. He failed swallow test and NG tube was placed. His oral prednisone was switched to IV methylprednisolone 40 mg. Next day he developed seizures which were aborted with IV Lorazepam and he was started on IV Levetiracetam. Lumbar puncture was done and came positive for VZV PCR. CTA performed showed calcifications in ICA and no inflammatory changes. He became more encephalopathic the next day and a repeat CT head was negative again, MRI brain was performed due to suspicion for VZV-angiitis which showed areas consistent with possible acute infarction versus vascular inflammation in right centrum semiovale and posterior parietal cortex (Figure 1). Risks/benefits of using IV methylprednisolone 1gram for 3 days were weighed after extensive discussion with neurology and patient's health care power of attorney as very little evidence is present for the optimal dosage due to rarity of VZV-angiitis. First dose of this high strength Steroid regimen was given and the next day he was awake, alert and oriented and passed a swallow test which he previously failed. After 3 days of methylprednisolone he was transitioned to 60 mg Prednisone daily. During hospitalization his mentation waxed and waned but he was discharged from the hospital to LTACH in a stable condition.



**Figure 1** MRI T2 view showing areas consistent with possible acute infarction versus vascular inflammation in right centrum semiovale and posterior parietal cortex.

## DISCUSSION

VZV- related common CNS disorders include meningo-encephalitis, myelitis, myelopathies and poly neuropathies and most of them have a favorable prognosis [2]. VZV related CNS vasculopathy is more common in immunocompromised individuals [3]. A few cases of VZV- related CNS vasculopathy have been described for the primary VZV infection in immunocompetent adults [4]. VZV vasculopathy of CNS can occur in any age group following either the primary infection or reactivation of VZV [5]. VZV vasculopathy of CNS involves a spectrum of pathological changes in arteries with thrombosis, necrosis, dissection, and aneurysm formation [6]. The classic clinical presentation of VZV vasculopathy is ophthalmic-distribution zoster followed by neurologic deficits and/or encephalitis with altered mental status and neurological deficits [7,8]. Irrespective of the primary infection or reactivation, treatment with antiviral is considered a gold standard of care for treatment of VZV infection, the role of steroids has not been well studied [9]. In the case described above we treated the patient, presented initially with ophthalmic-distribution zoster followed by encephalopathy with waxing and waning mental status, with acyclovir and we also added high dose steroids which rapidly

improved the clinical condition of the patient. Though the role of steroids in the treatment of VZV vasculopathy is unclear and needs more research but the rapid improvement in clinical condition of this patient can be attributed to anti-inflammatory properties of steroids.

## Learning Points

VZV angitis of CNS can occur at any age following either primary infection or reactivation of virus.

- VZV angitis is comparatively more common in immunocompromised patients.
- Treatment with IV acyclovir is recommended.
- High dose steroids can be of potential benefit due to their anti-inflammatory properties.

## ACKNOWLEDGEMENTS

We would like to thank the staff of Neurology Department of Mercy Health Saint Mary's Grand Rapids, MI, USA.

## REFERENCES

1. Verma R, Lalla R, Patil TB. Extensive extracranial and intracranial varicella zoster vasculopathy. *BMJ Case Rep.* 2012; 2012: bcr2012006845.
2. Mathiesen T, Linde A, Olding-Stenkvis E, Wahren B. Antiviral IgM and IgG subclasses in varicella zoster associated neurological syndromes. *J Neurol Neurosurg Psychiatry.* 1989; 52: 578-582.
3. Picard O, Brunereau L, Pelosse B, Kerob D, Cabane J, Imbert JC. Cerebral infarction associated with vasculitis due to varicella zoster virus in patients infected with the human immunodeficiency virus. *Biomed Pharmacother.* 1997; 51: 449-454.
4. Molloy A, Forde D, De Gascun C, Fanning N, Wyse G, O'Toole O. A virulent vasculopathy. *BMJ Case Rep.* 2011; 2011: bcr1120103481.
5. Gilden D, Cohrs RJ, Mahalingam R, Nagel MA. Varicella zoster virus vasculopathies: diverse clinical manifestations, laboratory features, pathogenesis, and treatment. *Lancet Neurol.* 2009; 8: 731-740.
6. Kleinschmidt-DeMasters BK, Gilden DH. Varicella-Zoster virus infections of the nervous system: clinical and pathologic correlates. *Arch Pathol Lab Med.* 2001; 125: 770-780.
7. Gilden DH, Kleinschmidt-DeMasters BK, Wellish M, Hedley-Whyte ET, Rentier B, Mahalingam R. Varicella zoster virus, a cause of waxing and waning vasculitis *The New England Journal of Medicine* case 5-1995 revisited. *Neurology.* 1996; 47: 1441-1446.
8. Gilden DH, Lipton HL, Wolf JS, Akenbrandt W, Smith JE, Mahalingam R, et al. Two patients with unusual forms of Varicella-Zoster Virus Vasculopathy. *N Engl J Med.* 2002; 347: 1500-1503.
9. Nagel MA, Cohrs RJ, Mahalingam R, Wellish MC, Forghani B, Schiller A, et al. The varicella zoster virus vasculopathies Clinical, CSF, imaging, and virologic features. *Neurology.* 2008; 70: 853-860.

## Cite this article

Kamran I, Malik AQ, Muhammad Y, Nasir K (2018) A Case Report of Varicella Zoster Virus Angiitis in a Patient Treated with Combination of Acyclovir and Steroids. *J Neurol Disord Stroke* 6(1): 1138.