

Case Report

Posterior Reversible Encephalopathy Syndrome with Rituximab in Hodgkin's Lymphoma and Idiopathic Thrombocytopenic Purpura

Alejandro Vargas* and Lawrence A. Zeidman

Department of Neurology and Rehabilitation, University of Illinois at Chicago, USA

Corresponding author

Lawrence A. Zeidman, University of Illinois at Chicago, Department of Neurology and Rehabilitation (M/C 796), Neuropsychiatric Institute, 912 S. Wood Street, Room 855N, Chicago, IL, USA 60612-7330, Tel: 312-996-6496, Fax: 312-996-4169, Email: lzeidm1@uic.edu

Submitted: 17 July 2013

Accepted: 13 September 2013

Published: 15 September 2013

Copyright

© 2013 Vargas and Zeidman

OPEN ACCESS

Keywords

- Encephalopathy
- Hodgkin's lymphoma
- Leukemia
- Rituximab

Abstract

Posterior reversible encephalopathy syndrome (PRES) was first identified in 1996, and is typically caused by acute hypertension, renal decompensation, fluid retention, and treatment with immunosuppressants. Predisposing conditions include hypertension, eclampsia, autoimmune disease, leukemia, non-Hodgkin lymphoma (NHL), Idiopathic Thrombocytopenic Purpura (ITP), and Thrombotic Thrombocytopenic Purpura (TTP). Rituximab has been reported in association with PRES in neuromyelitis optica (NMO), hepatitis C, and NHL but not to our knowledge in a patient with Hodgkin's Lymphoma (HL) or ITP. We present a case of PRES in a patient with HL in remission who received rituximab for suspected ITP.

CASE PRESENTATION

A 22-year-old male was diagnosed with HL at age 14 after an initial presentation of fever, night sweats, weight loss, and lymphadenopathy. The patient underwent 6 cycles of adriamycin, bleomycin, vinblastine, and dacarbazine as well as radiation therapy. There was no evidence of recurrence in 2009, and he did not have any clinical follow-up since then.

In June 2011, with a platelet count of 1000/microliter of blood, he was diagnosed with ITP after a bone marrow biopsy revealed no evidence of recurrent infiltrative disease. He underwent a laparoscopic splenectomy after proving refractory to methylprednisolone, prednisone, and three rituximab doses, and only modest improvement with intravenous immunoglobulin (IVIG) and Rho (d) immune globulin. In mid-July he was discharged with a platelet count of 6000/microliter, but returned two days later with hematuria and melena and a platelet count of 3000/microliter.

He was continued on intravenous methylprednisolone after transfer to our facility. His blood pressures ranged from 118/73 to 155/100 prior to his fourth overall dose of rituximab (375 mg/m²). Afterward, his blood pressures ranged from 140/86 to 177/118. The next morning, he had two witnessed generalized convulsions, each lasting two minutes, without tongue-biting or incontinence, and followed by transient dysarthria, fatigue, and

confusion. Rituximab was discontinued, and he was started on levetiracetam 500 mg every 12 hours and metoprolol 50 mg twice daily. MRI of the brain without contrast demonstrated bilaterally symmetric areas of abnormal T2/FLAIR (fluid-attenuated inversion recovery) signal intensity throughout the cerebral and cerebellar hemispheres, primarily involving the cortical and subcortical parenchyma, without evidence of hemorrhage or infarction, consistent with PRES (Figure 1). An EEG was normal, he remained seizure-free, and his blood pressure normalized.

DISCUSSION

PRES commonly presents with headache, vomiting, confusion, seizures, and visual abnormalities [1]. The presumed pathophysiology with hypertension seems to involve vasogenic edema predominantly in the posterior circulation, given the relative lack of sympathetic innervation there [2,3]. With

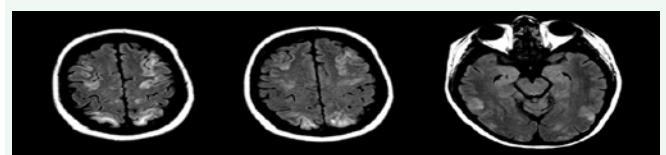


Figure 1 MRI brain, axial sections, with symmetric areas of abnormal T2/FLAIR signal intensity throughout the cerebral and cerebellar hemispheres, primarily involving the cortical and subcortical parenchyma.

immunosuppressants, the etiology is less clear but is likely related to blood-brain barrier disruption from damage to the vascular endothelium, [3] reversible vasospasm and ischemia from increased endothelin concentrations, direct axonal injury from white matter edema, or a combination of all three [4]. Rituximab is a CD20 B-lymphocyte monoclonal antibody that has been used successfully in lymphoproliferative disorders, systemic lupus erythematosus, NMO, [5] and sarcoidosis, [6] and because of the expression of CD20 in activated endothelial cells, it may cause direct cell damage [5].

Cranial MRI typically reveals white matter edema in the posterior hemispheres, but may appear in a gradient from posterior to anterior, and not all cases are reversible [3]. The presentation of our patient with two seizures but subsequent rapid clinical improvement, and the typical MRI findings [3] are consistent with the diagnosis of PRES, as clinical resolution alone may define reversibility [1,3]. Immunosuppressant administration without hypertension has been associated with PRES, especially with tacrolimus [1] or with rituximab [5]. Our patient had modest hypertension before and after his last rituximab dose, and preceding the onset of PRES. Modest hypertension is a non-specific finding in acute medical admissions, [6] and this phenomenon is similar to other PRES cases in which subacute hypertension preceded the immunosuppressant administration, but the hypertension was felt not to be as closely temporally related to PRES-onset as the medication administration [2]. Steroids and IVIG were associated with PRES in an ITP case [7], but not with ITP in an HL patient in remission. To what extent the steroids, IVIG, or Rho (d) contributed to the onset of PRES in our case is unclear, but the temporal relation of PRES with the last rituximab infusion suggests the latter was the etiology. Symptom resolution was observed with discontinuation of rituximab, further supporting the causal relationship. But perhaps the additive and combination effect of corticosteroids and immunoglobulin treatments with rituximab caused the PRES-inducing injury in this case, especially given that two other cases of rituximab-induced PRES occurred in patients who had recently received steroids and IVIG, [5,8] and another case occurred in a patient who received prednisolone as part of her NHL treatment regimen [6].

This case widens the differential diagnosis for conditions predisposing to PRES, and adds another case to the literature linking rituximab to PRES. All clinicians prescribing rituximab should be aware of the potential association with PRES, and should likely take caution especially when using it in combination with steroids and IVIG. Given the widely recognized treatment potential of rituximab, its use should not likely be restricted, but patients should likely be informed of the risk of PRES prior to rituximab administration, especially if other immunosuppressants have been used previously.

ACKNOWLEDGEMENT

We acknowledge the Research Open Access Publishing (ROAAP) Fund of the University of Illinois at Chicago for financial support towards the open access publishing fee for this article.

REFERENCES

1. Hinchey J, Chaves C, Appignani B, Breen J, Pao L, Wang A, et al. A reversible posterior leukoencephalopathy syndrome. *N Engl J Med.* 1996; 334: 494-500.
2. Morris EB, Laningham FH, Sandlund JT, Khan RB. Posterior reversible encephalopathy syndrome in children with cancer. *Pediatr Blood Cancer.* 2007; 48: 152-159.
3. McKinney AM, Short J, Truwit CL, McKinney ZJ, Kozak OS, SantaCruz KS, et al. Posterior reversible encephalopathy syndrome: incidence of atypical regions of involvement and imaging findings. *AJR Am J Roentgenol.* 2007; 189: 904-912.
4. Garg RK. Posterior leukoencephalopathy syndrome. *Postgrad Med J.* 2001; 77: 24-28.
5. Sánchez-Carteyron A, Alarcia R, Ara JR, Martín J. Posterior reversible encephalopathy syndrome after rituximab infusion in neuromyelitis optica. *Neurology.* 2010; 74: 1471-1473.
6. Siddiqi AI. Rituximab as a possible cause of posterior reversible encephalopathy syndrome. *Australas Med J.* 2011; 4: 513-515.
7. Ortega-Carnicer J, Ambrós A, Diarte JI. Reversible posterior leukoencephalopathy syndrome in a young trauma patient. *Resuscitation.* 2005; 64: 119-120.
8. Zito JA, Lee CC, Johnson S, Singer A, Vacirca J. Reversible posterior leukoencephalopathy syndrome after rituximab. *Am J Emerg Med.* 2010; 28: 537.

Cite this article

Vargas A, Zeidman LA (2013) Posterior Reversible Encephalopathy Syndrome with Rituximab in Hodgkin's Lymphoma and Idiopathic Thrombocytopenic Purpura. *J Neurol Transl Neurosci* 1(3): 1023.