

Review Article

Intercostal Neuralgia: A Review

Dureja GP*

Department of Pain Management, Delhi Pain Management Centre, India

Corresponding author

Dureja GP, Department of Pain Management, Delhi Pain Management Centre, Safdarjung Enclave, Gurgaon (Sec 45) Gurgaon, India, Email:

Submitted: 28 September 2016

Accepted: 17 January 2017

Published: 21 January 2017

ISSN: 2333-7087

Copyright

© 2017 Dureja

OPEN ACCESS

Keywords

- Neuropathic pain
- Intercostal neuralgia
- Treatment
- Intercostal nerve block

Abstract

Intercostal neuralgia is pain in the thoracic region emanating from an intercostal nerve. It occurs commonly after thoracotomy. It can also be seen in elderly debilitated patients without a known precipitating event, other causes include rib trauma, very rarely benign periosteal lipoma and pregnancy. Intercostal neuralgia due to surgical injury of the intercostal nerve has traditionally been difficult to treat. No single treatment modality has been curative. There are several treatment options available, including systemic medications, topical or invasive nerve blocks, cryoablation, and radio ablation. Despite numerous treatment advances, many patients remain refractory to the current therapies and continue to have pain, physical and psychological distress. In this review, we will discuss the pathophysiology of intercostal neuralgia, its clinical manifestations, diagnosis and various pharmacological, non-pharmacological and interventional treatment modalities, as also the insight into the potential complications of the disease and treatment modalities.

INTRODUCTION

Intercostal neuralgia refers to a neuropathic condition involving the intercostal nerves, manifesting as intense dysesthetic pain, e.g., sharp, shooting, or burning in quality.

The pain is constant and burning in nature and may involve any of the intercostal nerves and the sub costal nerve of the 12th rib. The pain usually begins at the posterior axillary line and radiates anteriorly into the distribution of the affected intercostal and sub costal nerves. Deep inspiration or movement of the chest wall may increase the pain of intercostal neuralgia slightly but much less compared with the pain

Associated with the musculoskeletal causes of chest wall pain (e.g., costosternal joint pain, Tietze's syndrome, or broken ribs) [1,2].

Intercostal Neuralgia occurs due to a number of reasons such as nerve entrapment, a traumatic or iatrogenic neuroma, persistent nerve irritation, or herpes zoster [1]. The pain of intercostal neuralgia is the result of damage or inflammation of the intercostal nerves and can be localized one or more of the intercostal space. Although it is most commonly seen and recognized in patients with chronic chest wall pain after thoracotomy [3-5], intercostal neuralgia has been reported in patients after breast and abdominal surgery, trauma, and infection [6-8]. Intercostal neuralgia due to surgical injury of the intercostal nerve has traditionally been difficult to treat. No single treatment modality has been curative [5,6]. There are several treatment options available, including systemic medications [1,5], topical or invasive nerve blocks [5,9,10], cryoablation [11-13], and radiofrequency ablation [14].

PATHOPHYSIOLOGY OF INTERCOSTAL NEURALGIA**Anatomy of Intercostal Nerves**

The twelve pairs of thoracic spinal nerves (T1-12) are divided into ventral and dorsal rami after they pass through

the inter vertebral foramina. The ventral rami of T1-T11 form the intercostal nerves that enter the inter costal spaces. The ventral ramus of T12 forms the subcostal nerve that is located inferior to the 12th rib. The dorsal rami of T1-T12 pass posteriorly to supply sensation to skin, muscles, and bones of the back [15].

Intercostal nerves are composed of dorsal horn sensory afferent fibers, ventral horn motor efferent fibers, and postganglionic sympathetic nerves. The major branches of intercostal nerves are anterior and lateral cutaneous branches (Figure 1). These branches divide and innervate the skin and intercostal muscles of an individual segment along with variable collateral innervation of the adjacent segments. Throughout its course, each inter costal nerve is associated with an artery and a vein. The intercostal nerve travels inferior to the vein and artery of the same segment [16].

The pathogenesis of acute intercostal neuralgia involves multiple etiologies, such as skin and muscle injury, costochondral dislocation, costovertebral ligament damage, post herpetic neuralgia, post thoracotomy pain, or intercostal neuritis. The pathophysiology of acute pain involves chemo sensitive ion channels in peripheral nociceptors that are activated by cytokines released from damaged tissue or inflammatory cells. Activation of these channels results in generation of action potentials that are conducted from the peripheral nociceptors in the chest area to the thoracic spinal cord via intercostal nerves.

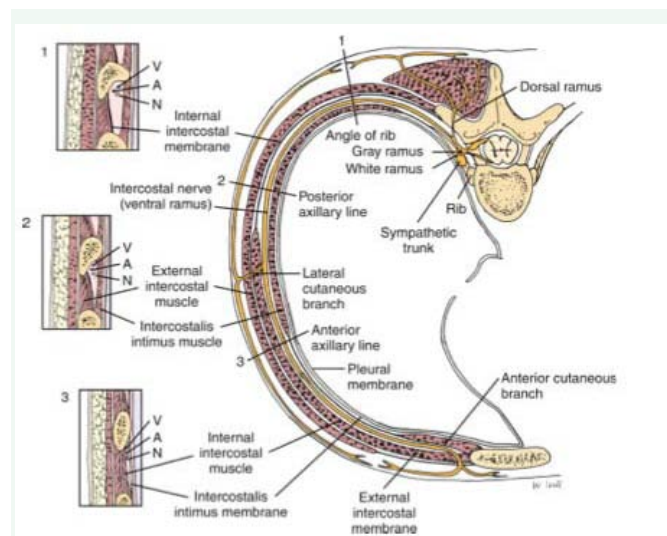


Figure 1 Intercostal nerve location. The inter costal nerve (N) runs along the inferior rib with the artery (A) and vein (V).

The pathophysiology of chronic intercostal neuralgia pain is complex and involves a combination of peripheral, central, and psychological mechanisms. In some patients, a structural or inflammatory source can be identified; however, most patients encountered in clinical practice have primary pain disorders in which the etiologies are uncertain [16].

Epidemiology

According to University Pain Centre Maastricht thoracic pain is relatively rare, and is only seen in an estimated 3-22% of patients referred to pain clinics. The prevalence of thoracic pain in the general population is about 15%. Chronic post-thoracotomy and post-thoracoscopy pain has a prevalence of 40%, and half of these cases are neuropathic in character. Intercostal neuralgia is the most frequent form.

The exact prevalence of abdominal wall pain is unknown. Abdominal wall pain has been diagnosed in 10 to 90 percent of patients with abdominal pain of unknown cause in various series based upon the patient cohort [17]. In one study, 5 to 10 percent of patients referred to specialist practices in gastroenterology had a diagnosis of chronic abdominal wall pain. In another study, 20 percent of patients admitted to a surgical department for abdominal pain had abdominal wall pain [18].

Women appear to be four times more likely to have chronic abdominal wall pain than men. The peak incidence is between the ages of 30 to 50 years, although cases have been reported in children and the elderly.

Clinical Manifestations

The first symptom of intercostal neuralgia may be considered pain in the ribs, which is due to irritation or compression of the intercostal nerves. According to the nature of the pain it can be different in feeling: burning, sharp, aching, or dull. According to the periodicity the pain can be both episodic and constant. The pain can be dramatically intensified if any, even minor physical activity, or simply an unexpected movement, for example, a sharp body movement, jump, cough or sneeze.

The symptoms of intercostal neuralgia can be recognized with a simple probing. During the palpation of the certain parts of the body (in the area between ribs along the spinal discs and thorax), the patient can feel a sharp pain. Also, patients often complain about the pain during the active inhalation and exhalation, there is a feeling of "intercepting" breathing. There is also a "reflection" of pain, which is usually localized in other parts of the body and can occur under the shoulder blade, in the back and loins. Also the "belting" pain is a characteristic. Intercostal neuralgia may be accompanied by not only the pain and tightness of the intercostal space, but also involuntary contraction and twitching of individual muscle groups. In the area of peripheral nerve injury the skin can change colour (turn red or pale), as well in these places the sensitivity can be lost due to numbness.

In intercostal neuralgia, there are no constitutional signs, such as fever, dyspnea, diaphoresis, or shortness of breath [19]. Physical examination generally reveals minimal findings unless the patient has a history of previous thoracic or sub costal surgery or cutaneous evidence of herpes zoster involving the thoracic dermatomes. Patient with intercostal neuralgia do not attempt to splint or protect the affected area, unlike patients with musculoskeletal causes of chest wall and sub costal pain. Careful sensory examination of the affected dermatomes may reveal decreased sensation or allodynia. When motor involvement of the sub costal nerve is significant, the patient may complain that his or her abdomen bulges outward [20].

Diagnosis

Physical Examination: Extensive general physical and neurological examinations are always indicated in thoracic pain, particularly when dorsal column disorders are present. The sensitivity of the thorax and stomach should also be examined. Loss of sensitivity indicates whether or not the pain is neuropathic pain. Examination of the thoracic spine is preferably performed with the patient in a sitting position and comprises inspection at rest and palpation of the vertebra and para vertebral structures, such as the costovertebral joints.

Provocation of pain by performing passive rotations, forward flexion, backward flexion and lateral flexions in particular, can indicate that the pain has a spinal aetiology. In upper thoracic and median and paramedian unilateral pain, shoulder function on the same side should also be examined. Pressure pain in the sternum, sternocostal and cost overtebral junctions is usually accompanied by a local pain pattern (e.g., Tietzes syndrome), but is sometimes associated with segmental pain. Pressure pain of the rib(s) can indicate which thoracic level(s) is involved. Segmental translation of the thoracic vertebra (Federung test) in the prone position can indicate the level of the affected segment.

Additional Somatic Diagnostics: Since thoracic pain is not a clinical entity and the cause cannot always be determined by anamnesis and physical examination, additional diagnostics are always necessary.

- In uncomplicated intercostal neuralgia, additional diagnostics are not necessary.
- In trauma with or without osteoporosis, X-ray is indicated in order to exclude an impression fracture.

- When there is suspicion of a malignancy, MRIs can and/or referral to a specialist is mandatory. Particularly in patients with a history of malignancy with acute thoracic pain, additional diagnostics are important. The same is true in the case of neurological deficits.
- When there is suspicion of pathology in the chestwall and/or there are pulmonary
- Complaints, X-ray can be useful, together with possible referral to a pulmonary specialist.
- When there is any doubt, or if visceral pathology is suspected, ultrasound, CT scan or
- Referral to a specialist should be considered.

Differential diagnosis [19]:

- Thoracic radiculopathy
- Malignant neoplasm (primary or metastatic)
- Rib fracture
- Vertebral compression fracture
- Chest wall contusion
- Acute Herpes Zoster and Postherpetic neuralgia
- Referred pain from cardiac, pulmonary, vascular, or GI systems
- Angina, Myocardial infarction
- Aortic dissection
- Esophageal disorders
- Cholecystitis
- Peptic ulcer disease
- Pancreatitis
- Pleurisy
- Pulmonary embolism
- Pneumothorax
- Costochondritis
- Tietze syndrome
- Nephrolithiasis
- Pyelonephritis
- Costovertebral or costochondral arthritis
- Spondylitis

Multidisciplinary Treatment

A definite treatment protocol is yet to be suggested for patients of intercostal neuralgia, as the efficacy of the proposed treatments is difficult to evaluate. Small sample sizes, difficulty in assigning control groups, and ambiguous outcome parameters are the main factors that affect the outcome. The initial choice of therapy should be guided by the patient's comorbidities, adverse effects of drugs, and patient preference. Whether or not somatic

treatment is indicated is based on the pain diagnosis. Based on the findings of the pain questionnaires, additional diagnostics and/or multidisciplinary treatment comprising various non-somatic treatments may be necessary (Figure 2).

Somatic Treatment

Pharmacological Treatment: Tricyclic anti depressants: Amitriptyline, Nortriptyline, Desipramine

Anticonvulsants: carbamazepine, oxcarbazepine, gabapentin, pregabalin

Non-somatic Treatment:

- Psychological Treatment
- Cognitive-Behavioural Treatment
- Rehabilitation Treatment

Interventional Pain Treatment

- Intercostal Nerve block
- Dorsal root ganglion test block
- Dorsal root ganglion PRF treatment

Pharmacological Treatment (Table 1)

Typically, drugs have not been specifically tested on populations of patients with intercostal neuralgia. Instead, physicians are left to extrapolate the data from treatment of other sources of neuropathic pain and to apply those principles in choosing medication to be used for this population. Often, neuropathic pain responds poorly to acetaminophen, non-steroidal anti-inflammatory drugs, and low-dose narcotics, in contrast to nociceptive pain [21, 22]. However, if the pain is mild to moderate, these agents are often tried first. Topical agents may

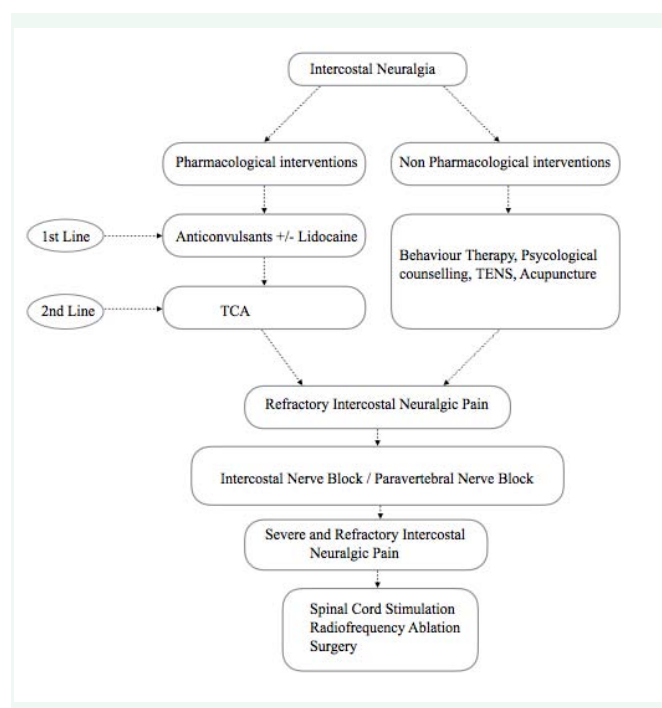


Figure 2 Treatment plan for Intercostal neuralgia.

Table 1: Treatment of options for Intercostal Neuralgia/

Medications	Dosage	Adverse effects
Antiepileptics		
Gabapentin	100 to 300 mg orally at bedside; increase dosage by 100 to 300 mg every 2 days until dosage is 300 to 800 mg three times daily or response is adequate	Mild peripheral edema, cognitive impairment, somnolence, fatigue, dizziness, ataxia, rash
Pregabalin	50mg at bedtime daily, increase to 150 mg bd daily within one week	Sleep disturbance, dizziness
Tricyclic antidepressants Amitriptyline Nortriptyline Imipramine Desipramine	10 to 25mg orally at bedtime; increase dosage by 25mg every two or four weeks until response is adequate, or to a maximal dosage of 150mg per day	Sedation, dry mouth, constipation, sweating, xerostomia, confusion, dysrhythmias, weight gain, dizziness
Topical agents Capsaicin cream 0.025% Capsaicin cream 0.075% Capsaicin cream 8%	Applied to affected area three to five times daily single- application placed on the skin for 60 minutes after pretreatment with lidocaine cream; Up to four patches may be applied at one time, and repeated as often as every three months	Localized erythema and comfortable burning, stinging or itching
5% Lidocaine gel	Apply to affected area every four to twelve hours, as needed	Localized skin irritation
Transdermal 5% lidocaine	One -to - three patches worn for 12 hour interval	
Eutectic mixture of local anesthetics (2.5% of lignocaine 2.5% prilocaine)	Apply to affected area every six to twelve hours as needed	

be effective when there is significant allodynia or dysesthesia. Capsaicin creams are available over-the-counter, and a newer capsaicin patch (Qutenza) is available by prescription (the actual indication is for postherpetic neuralgia). Capsaicin is derived from hot chilli peppers from the genus *Capsicum* and has a long history of use in medical practice. It interacts with sensory afferents via vanilloid receptors VR1, which are cation channels from transient receptor potential family. Chronic exposure to capsaicin stimulates and desensitizes these channels. Besides, capsaicin depletes substance P at nervous afferent endings and transiently decreases the density of nervous fibers on the skin. Capsaicin is available as 0.025% cream used 3-4 times/day or 8% patch for single dose [23]. Topical lidocaine applied as a gel, eutectic mixture of local anesthetics (EMLA), or patch (Lidoderm) is another alternative [9]. It was recognized that a lidocaine patch acted only on abnormal, intact hyperalgesic afferent receptors. Recently, patches proved to be effective also in skin devoid of nociceptors [24]. Topical lidocaine slows peripheral nociceptor sensitization and central hyper excitability.

Tricyclic antidepressants (e.g., amitriptyline, nortriptyline, desipramine) have been used for neuropathic pain for decades [25]. Unfortunately, this class of drugs is associated with significant anticholinergic side effects, including dry mouth, constipation, sedation, and urinary retention.

These drugs should be used with caution in patients suffering from glaucoma, cardiac arrhythmia, and prostatism. To minimize side effects and encourage compliance, the physician should start amitriptyline or nortriptyline at a 10-mg dose at bedtime; the dose can then be titrated upward to 25 mg at bedtime, as side effects allow. Subsequently, upward titration in 25-mg increments can be carried out each week, as side effects allow. Even at lower doses, patients generally report a rapid improvement in sleep disturbance and begin to experience

some pain relief in 10 to 14 days. The selective serotonin reuptake inhibitors such as fluoxetine have also been used to treat the pain of intercostal neuralgia, although these drugs are better tolerated but appear to be less efficacious than the tricyclic antidepressants [2]. If the antidepressant compounds are ineffective or contraindicated, gabapentin is a reasonable alternative. Gabapentin is started at a 300-mg dose at bedtime for 2 nights. The patient should be cautioned about potential side effects, including dizziness, sedation, confusion, and rash. The drug is then increased in 300-mg increments given in equally divided doses over 2 days, as side effects allow, until

Pain relief is obtained or a total dose of 2400 mg/day is reached. At this point, if the patient has experienced partial pain relief, blood values are measured, and the drug is carefully titrated upward using 100-mg tablets. Rarely is a dose greater than 3600 mg/day required [2]. Pregabalin can also be started at a low 50 mg bedtime dose and titrated to 300 mg twice daily, although it is uncommon to exceed 150 mg twice daily. Gabapentin and other anti convulsants should be tapered before discontinuance [19]. Like gabapentin and pregabalin, topiramate has also been used off-label for intercostal neuralgia [1].

Narcotics are often required for intercostal neuralgia. Adequate analgesia is needed to promote continued activity levels and to prevent deconditioning from disuse. Initial treatment should be with short-acting agents such as hydrocodone 5 mg with acetaminophen 325 mg every 4 hours as needed.

Treatment of intercostal neuralgia can be protracted, and patients are often switched to long-acting agents for maintenance. If the pain is progressive, one should reevaluate the diagnosis and reconsider the possibility of occult tumor. In refractory cases of neuropathic pain, clonidine, an adrenergic agonist, and ketamine, an N-methyl-D-aspartate (NMDA) receptor antagonist, may be prescribed by pain specialists [26].

REHABILITATION

Physical and occupational therapy can be instrumental in combating disused conditioning. Also, desensitization techniques may be employed. Psychological consultation, relaxation therapy and acupuncture have also been employed with anecdotal success [4].

If pain is severe, intercostal neuralgia may lead to avoidance of activity and deconditioning. It is important to keep patients physically active early in the habilitation process. The muscles of persons on strict bed rest lose 1.0% to 1.5% of their strength per day during a 2-week period. The loss is greatest during the first week of inactivity. The local application of heat and cold or the use of an elastic rib belt may also provide symptomatic relief.

Biofeedback uses instrumentation to provide feedback on a variety of physiologic responses, such as muscle tension. It is typically used to facilitate relaxation and to enhance self-regulation. Two common relaxation therapies are autogenic training and progressive muscle relaxation [19].

INTERVENTIONAL MANAGEMENT

Local infiltration of a neuroma with corticosteroids and local anesthetics, intercostal nerve blocks, in dwelling epidural catheters, and spinal nerve injections have all been used to control the pain associated with intercostal neuralgia when adequate relief is not achieved with oral and topical medications [27]. If symptoms are well controlled with intercostal nerve blocks but recur, neurolytic injection of phenol or alcohol has been used to denervate the peripheral nerve [28]. In dwelling epidural catheters have been used to provide regional anesthesia with minimal drug use. This technique was found to be safe and effective in pregnant patients who developed intercostal neuralgias [29].

In Intercostal nerve block the patient is placed in the prone position with the arms hanging loosely off the sides of the table. Alternatively, this block can be done in the sitting or lateral position. The Rib to be blocked is identified by palpating its path at the posterior axillary line. The index and middle fingers are then placed on the rib, thus bracketing the site of needle insertion, and the skin is prepared with antiseptic solution (Figure 3). A 11/2-inch, 22-gauge needle is attached to a 12-mL syringe and is advanced perpendicular to the skin while aiming for the middle of the rib between the operator's index and middle fingers. The needle should impinge on bone after being advanced approximately 3/4 inch. Once bony contact is made, the needle is withdrawn into the subcutaneous tissues, and the skin and subcutaneous tissues are retracted with the operator's palpating fingers inferiorly. This technique allows the needle to be walked off the inferior margin of the rib. As soon as bony contact is lost, the needle is slowly advanced approximately 2 mm deeper. This maneuver places the needle in proximity to the costal groove, which contains the intercostal nerve as well as the intercostal artery and vein (Figure 4). After careful aspiration reveals no blood or air, the operator injects 3 to 5 mL of 1% preservative-free lidocaine. If the pain has an inflammatory component, the local anesthetic is combined with 80 mg methyl prednisolone and injected in incremental doses. Subsequent daily nerve blocks are carried out in a similar

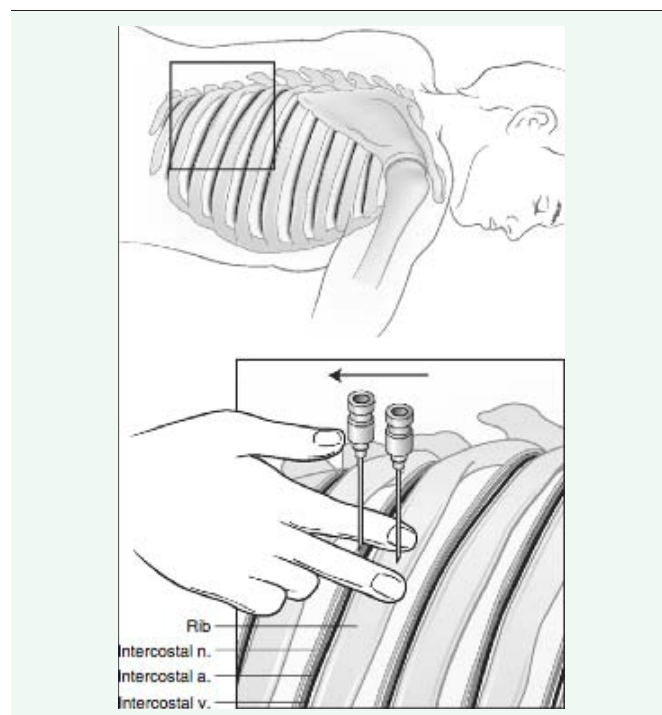


Figure 3 Intercostal nerve Block.

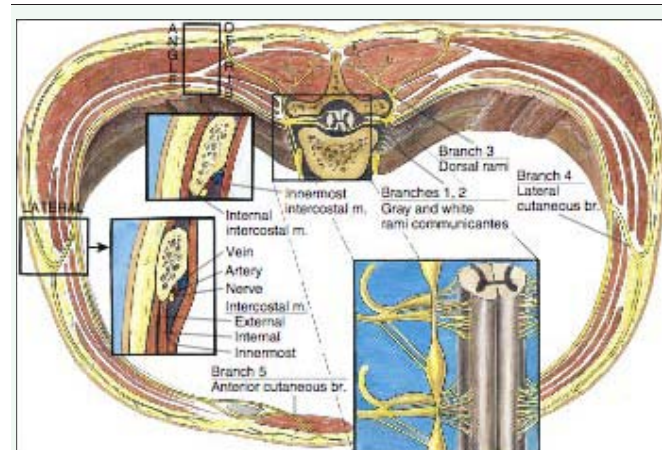


Figure 4 Intercostal nerve block: Cross-sectional anatomy.

manner, substituting 40 mg methylprednisolone for the initial 80-mg dose. Because of the overlapping innervation of the chest and upper abdominal wall, the intercostal nerves above and below the nerve suspected of causing the pain must also be blocked [20].

The standard of care for interventional pain management has shifted towards procedures performed under fluoroscopic guidance for accuracy and safety. For procedures not conducive to fluoroscopic guidance, nerve stimulation and ultrasound guidance may be used for accuracy and safety. Ultrasound guidance can greatly facilitate intercostal nerve blockade and improve patient comfort as ultrasound guidance offers a distinct advantage over the traditional anatomic landmark based approach. The landmark-based approach is performed at the posterior axillary line where the ribs can be

easily palpated. This is often lateral, however, to the division of the intercostal nerve into deep and lateral cutaneous branches and may therefore result in good anesthesia of the rib and thoracic musculature but poor anesthesia of the parietal pleura. With direct visualization of the ribs and pleura, ultrasound guidance allows the provider to perform an intercostal block medial to the scapula where the intercostal nerve can be blocked before its division, ensuring adequate anesthesia of the pleura. In addition, routine use of ultrasound guidance enables visualization of local anesthetic injection into the intercostal space, allowing the provider to adjust the needle trajectory and depth as needed to ensure adequate anesthetic spread [30].

Thoracic Para vertebral Nerve Block is useful for the management of pain in the upper abdominal wall, the chest wall, and the thoracic spine. It is used to control acute pain in conditions such as rib fractures, acute herpes zoster of the thoracic cage, and cancer pain. The block is performed with the patient in the prone position. The spinous process of the vertebra above the nerve to be blocked is identified (Figure 5). A 3.5-in. needle is used for the block and is inserted after appropriate antiseptic treatment of the skin immediately below and 1.5 in. lateral to the spinous process. The transverse process should be encountered at a depth approximately 1.5 in. at which point the needle is walked off the inferior aspect of the transverse process and inserted another 0.75 in. deeper until a paresthesia is obtained. After negative aspiration for blood or CSF a total of 5 cc of 1% preservative-free lidocaine solution is injected for pain relief. If there is an inflammatory component then 40 mg of methyl prednisolone can be added for the initial block [31].

Recently, the implementation of pulsed radiofrequency (RF) has generated intense interest in the medical community as a safe and potentially effective treatment for neuropathic pain. In Thoracic Nerve Radiofrequency Lesioning the junction of the posterior axillary line and the rib to be blocked is identified. A 22-gauge 54-mm radiofrequency needle usually equipped with a 4 mm active tip is advanced aiming for the middle of the rib. After encountering the bone the needle is walked off the inferior border of the rib and advanced about 2 mm deeper to be close to the costal groove. First a trial sensory stimulation with 2 V at 50 Hz is performed to ensure that there is a paraesthesia along

the distribution of the intercostal nerve to be lesioned. A pulsed radiofrequency lesion is then performed by heating at 40-45°C for 5 min or alternatively by heating at 49-60°C for 90s [31]. In one of the studies it was concluded that Pulsed RF of the dorsal root ganglia was a superior treatment to pharmacotherapy and pulsed RF of the intercostal nerves in patients with chronic post surgical thoracic pain [32]. Cryotherapy involves another way of interrupting the peripheral nerve's ability to transmit pain by freezing it. Cryotherapy has been used on neuromas and the involved intercostal nerve [33].

Spinal cord stimulators have been implanted for inter costal neuralgia but with less success than in neuropathic pain due to diabetic peripheral neuropathy and causalgia [34]. Botulinum toxin type A (BTX-A) has been widely used in many clinical disorders including migraine, cervical dystonia, etc. The use of BTX-A in neuropathic pain, however, is uncommon, and the application of the anti-nociceptive effect of botulinum toxin is emerging. The effectiveness of BTX-A in treating neuropathic pain implies a direct action on sensory neurons and possibly with an indirect central action [35].

POTENTIAL COMPLICATIONS OF INTERVENTIONS

The most prevalent complication of interventional treatment is post-procedural pain. Local pain occurs for a few days after almost all procedures. Twenty percent of the patients who received RF treatment reported that the post-procedural pain lasted for a few weeks [36]. The major complications of an intercostal nerve block are pneumothorax and intravascular injection of local anesthetics. Careful post-procedure monitoring is necessary to detect these complications. The incidence of clinical significant pneumothorax has been reported less than 0.1% [37,38]. Accidental intravascular injection of local anesthetics during intercostal block is uncommon but potentially serious. It is known that blood levels of local anesthetics after an inter costal nerve Block are significantly greater than those after other frequently performed regional anesthetic techniques [39]. Adding epinephrine to local anesthetics and aspirating for blood before administering anesthetics, as well as injection of nonionic contrast under continuous fluoroscopy, are important steps that can be taken to minimize intravascular injection of local anesthetics. Other rare complications associated with an intercostal nerve block include infection, hemothorax, hemoptysis, hematoma, tissue necrosis, neuritis, respiratory insufficiency,

Sub arachnoid block, failed block, and allergic reaction to local anesthetics [40]. If nonionic contrast is used, anaphylactoid reaction can occur, but are rare, and can be avoided by a pretreatment regimen of prednisone, diphenhydramine, and ranitidine [41].

SURGERY

Surgical resection of a neuroma can be effective but should be reserved for cases that have failed more conservative care and have demonstrated a temporary response to intercostal blocks. Dorsal root entry zone ablation involves surgical destruction of nociceptive secondary neurons in the spinal cord when pain is not adequately controlled with medical therapy [42,43]. The technique involves laminectomy with intradural exposure of

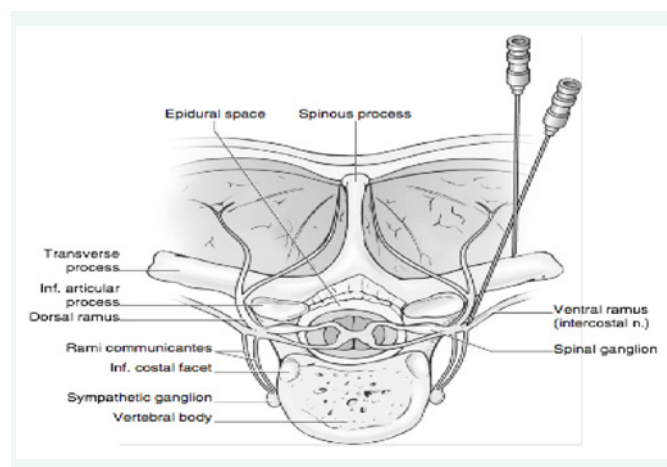


Figure 5 Thoracic paravertebral nerve block.

the spinal cord. With an operating microscope, a radiofrequency probe is used to heat the dorsal horn of the affected side with a series of lesions.

POTENTIAL DISEASE COMPLICATIONS

Untreated upper intercostal neuralgia can potentially lead to a frozen shoulder as patients limit their use of the arm in response to the pain. Intercostal neuralgia can also cause a chronic pain syndrome with its comorbidities. Psychosocial dysfunction associated with chronic neuropathic pain includes impaired sleep, decreased appetite, and diminished libido [19].

CONCLUSION

Intercostal neuralgia is a commonly encountered cause of chest wall and thoracic pain. Correct diagnosis is necessary to treat this painful condition properly and to avoid overlooking serious intra thoracic or intra abdominal disease. Pharmacologic agents generally provide adequate pain control. If necessary, intercostal nerve block is a simple technique that can produce dramatic pain relief, but the proximity of the intercostal nerve to the pleural space makes careful attention to technique mandatory.

Transcutaneous electrical nerve stimulation (TENS) is an option for the treatment of thoracic radicular pain. Results for this specific treatment are not known. Two publications report good results from RF treatment in thoracic radicular pain management. Stolker et al. evaluated 45 patients with thoracic radicular pain [41]. There was a significant reduction of pain in more than 70% of the patients 13 to 46 months after the treatment. A similar study was conducted by van Kleef and Spaans [44]. They found that 52% of the patients had significant pain reduction for 9 to 39 months. PRF of the DRG resulted in a higher percentage of success, and the duration of the pain relief was longer (5 months vs. 3 months). The effect of classic RF treatment is better and lasts longer, but it damages the ganglion spinale (DRG). In cases of chronic thoracic radicular pain, an intercostal block can be performed as part of the diagnostic blocks. In case of therapy resistant pain, RF treatment or PRF treatment of the ganglion spinale can be considered [36].

REFERENCES

- Bajwa ZH, Sami N, Warfield CA, Wootton J. Topiramate relieves refractory intercostal neuralgia. *Neurology*. 1999; 52: 1917.
- Waldman SD. Chest Wall Pain Syndromes. In: Waldman SD (editor). *Pain Management*. Elsevier Saunders, 2011; 632-645.
- Rogers ML, Duffy JP. Surgical aspects of chronic post-thoracotomy pain. *Eur J Cardiothorac Surg*. 2000; 18: 711-716.
- Dajczman E, Gordon A, Kreisman H, Wolkove N. Long-term postthoracotomy pain. *Chest*. 1991; 99: 270-274.
- Karmakar MK, Ho AM. Postthoracotomy pain syndrome. *Thorac Surg Clin*. 2004; 14: 345-352.
- Ducic I, Larson EE. Outcomes of surgical treatment for chronic postoperative breast and abdominal pain attributed to the intercostal nerve. *J Am Coll Surg*. 2006; 203: 304-310.
- Wong L. Intercostal neuromas: a treatable cause of postoperative breast surgery pain. *Ann Plast Surg*. 2001; 46: 481-484.
- Santos PS, Resende LA, Fonseca RG, Lemônica L, Ruiz RL Jr, Catâneo AJ, et al. Intercostal nerve mononeuropathy: study of 14 cases. *Arq Neuropsiquiatr*. 2005; 63: 776-778.
- Devers A, Galer BS. Topical lidocaine patch relieves a variety of neuropathic pain conditions: an open-label study. *Clin J Pain*. 2000; 16: 205-208.
- Doi K, Nikai T, Sakura S, Saito Y. Intercostal nerve block with 5% tetracaine for chronic pain syndromes. *J Clin Anesth*. 2002; 14: 39-41.
- Green CR, de Rosayro AM, Tait AR. The role of cryoanalgesia for chronic thoracic pain: results of a long-term follow up. *J Natl Med Assoc*. 2002; 94: 716-720.
- Moorjani N, Zhao F, Tian Y, Liang C, Kaluba J, Maiwand MO, et al. Effects of cryoanalgesia on post-thoracotomy pain and on the structure of intercostal nerves: a human prospective randomized trial and a histologic. *Eur J Cardiothorac Surg*. 2001; 20: 502-507.
- Byas-Smith MG, Gulati A. Ultrasound-guided intercostal nerve cryoablation. *Anesth Analg*. 2006; 103: 1033-1035.
- Stolker RJ, Vervest AC, Groen GJ. The treatment of chronic thoracic segmental pain by radiofrequency percutaneous partial rhizotomy. *J Neurosurg*. 1994; 80: 986-992.
- Moore KL, Agur AMR. *Essential Clinical Anatomy*. Philadelphia: Lippincott Williams & Wilkins; 2006.
- Zhang L, Singla AK. Intercostal Nerve Block. In: Lennard TA, Vivian DG, Walkowski SD, Singla AK, editors. *Pain Procedures in Clinical Practice Third Edition Saunders*. 2011; 289-292.
- Srinivasan R, Greenbaum DS. Chronic abdominal wall pain: a frequently overlooked problem. Practical approach to diagnosis and management. *Am J Gastroenterol*. 2002; 97: 824-830.
- Thomson H, Francis DM. Abdominal-wall tenderness: A useful sign in the acute abdomen. *Lancet*. 1977; 2: 1053-1054.
- Dreyer SJ, Beckworth WJ. Intercostal Neuralgia. In: Frontera WR, Silver JK, Rizzo Jr TD. *Essentials of Physical Medicine and Rehabilitation Elsevier*. 2015; 514-519.
- Waldman SD. *Atlas of Common Pain Syndromes Saunders*. 3rd edn. 2011; 197-199.
- Beydoun A. Neuropathic pain: from mechanisms to treatment strategies. *J Pain Symptom Manage*. 2003; 25: 1-3.
- Portenoy R.K., Forbes K., and Lussier D.: Difficult pain problems: an integrated approach. In Doyle D., Hanks G., and MacDonald N. (eds): *Oxford textbook of palliative medicine*, 2nd ed. New York: Oxford University Press, 1998; 438-458.
- Brunton LL, Lazo JS, Parker KL, editors. *Goodman and Gilman's The Pharmacological Basis of Therapeutics*. 11th ed. New York, NY: McGraw-Hill; 2006.
- Wasner G, Kleinert A, Binder A, Schattschneider J, Baron R. Postherpetic neuralgia: topical lidocaine is effective in nociceptor-deprived skin. *J Neurol*. 2005; 252: 677-686.
- Onghe P, Van Houdenhove B. Antidepressant-induced analgesia in chronic non-malignant pain: a meta-analysis of 39 placebo-controlled studies. *Pain*. 1992; 49: 205-219.
- Milch RA. Neuropathic pain: implications for the surgeon. *Surg Clin North Am*. 2005; 85:1-10.
- Keller SM, Carp NZ, Levy MN, Rosen SM. Chronic post thoracotomy pain. *J Cardiovasc Surg (Torino)*. 1994; 161-164.
- Kopacz DJ, Thompson GE. Intercostal nerve block. In Waldman S. (eds): *Interventional pain management*, 2nd ed. Philadelphia: WB Saunders, 2001; 401-408.

29. Sax TW, Rosenbaum RB. Neuromuscular disorders in pregnancy. *Muscle Nerve*. 2006; 34: 559-571.
30. Stone MB, Carnell J, Fischer JWJ, Herring AA, Nagdev A. Ultrasound-guided intercostal nerve block for traumatic pneumothorax requiring tube thoracostomy. *Am J Emerg Med*. 2011; 29: 697- 697.
31. Cosgrove, Michael A, et al. *Interventional Pain Management*. In: Vadivelu, Nalini, Urman, Richard D, Hines, Roberta L. (Eds.) *Essentials of Pain Management*. Springer 2011; 256.
32. Cohen SP1, Sireci A, Wu CL, Larkin TM, Williams KA, Hurley RW. Pulsed radiofrequency of the dorsal root ganglia is superior to pharmacotherapy or pulsed radiofrequency of the intercostal nerves in the treatment... *Pain Physician*. 2006; 9: 227-235.
33. Saberski LR. Cryoneurolysis in clinical practice. In Waldman S. (eds): *Interventional pain management*, 2nd ed. Philadelphia: WB Saunders, 2001; 226- 242.
34. Kumar K, Toth C, Nath RK. Spinal cord stimulation for chronic pain in peripheral neuropathy. *Surg Neurol*. 1996; 46: 363-369.
35. Liu HT, Tsai SK, Kao MC, Hu JS. Botulinum toxin A relieved neuropathic pain in a case of post-herpetic neuralgia. *Pain Med*. 2006; 7: 89-91.
36. Van Kleef MV, Stolker RJ, Lataster A, Geurts JW, Benzon HT, Mekhail N. Thoracic Pain. In Zundert JV, Patijn J, Hartrick C, Lataster A, Huygen FJPM, Mekhail N, van Kleef M., editors. *Evidence-based Interventional Pain Practice - According to Clinical Diagnoses*, John Wiley & Sons, Ltd. 2012; 62-70.
37. MOORE DC, BRIDENBAUGH LD. Intercostal nerve block in 4333 patients: indications, technique, and complications. *Anesth Analg*. 1962; 41: 1-11.
38. Moore DC. Intercostal nerve block for postoperative somatic pain following surgery of thorax and upper abdomen. *Br J Anaesth*. 1975; 47 suppl: 284-286.
39. Tucker GT, Moore DC, Bridenbaugh PO, Bridenbaugh LD, Thompson GE. Systemic absorption of mepivacaine in commonly used regional block procedures. *Anesthesiology*. 1972; 37: 277-287.
40. Hidalgo NRA, Ferrante FM. Complications of paravertebral, intercostal nerve blocks and interpleural analgesia. In: Finucane BT, ed. *Complications of Regional Anesthesia*. New York: Springer; 2007.
41. Maddox TG. Adverse reactions to contrast material: recognition, prevention, and treatment. *Am Fam Physician*. 2002; 66: 1229-1234.
42. Brewer R, Bedlack R, Massey E. Diabetic thoracic radiculopathy: an unusual cause of post-thoracotomy pain. *Pain*. 2003; 103: 221-223.
43. Spaić M, Ivanović S, Slavik E, Antić B. [DREZ (dorsal root entry zone) surgery for the treatment of the postherpetic intercostal neuralgia]. *Acta Chir Jugosl*. 2004; 51: 53-57.
44. Van Kleef M, Spaans F. The effects of producing a radiofrequency lesion adjacent to the dorsal root ganglion in patients with thoracic segmental pain by radiofrequency percutaneous partial rhizotomy. *Clin J Pain*. 1995; 11: 325-332.

Cite this article

Dureja GP (2017) Intercostal Neuralgia: A Review. *J Neurol Transl Neurosci* 5(1): 1076.