

Clinical Image

Clinically Observable Eye Manifestations of Axonal Transport

Don Minckler*, Michael Yang, and Ken Lin

Department of Ophthalmology, University of California Irvine, USA

Corresponding author

Don Minckler, Department of Ophthalmology, University of California Irvine, USA, Tel: 760 840 1389

Submitted: 23 April 2023

Accepted: 25 April 2023

Published: 26 April 2023

ISSN: 2333-7087

Copyright

© 2023 Minckler D, et al.

OPEN ACCESS

PURPOSE

Illustrate and explain clinically observable manifestations of axonal transport. To our knowledge suppression of axonal transport and thinning of the nerve fiber layer have not previously been correlated with fundus changes as indicated in Figure 2. Improvement in disc contours is well known especially following IOP reduction in pediatric glaucoma and visual field improvement after IOP lowering has been well documented in adults, Figure 1. These pre-OCT observations are incentives for early recognition and therapy of adult glaucoma and will

hopefully stimulate pre- and post-operative measurements of the nerve fiber layer in young glaucoma patients by OCT.

COMMENT

We believe the explanation for disc and visual field recovery in some patients after intraocular pressure (IOP) lowering by trabeculectomy is the result of axonal transport recovery from suppression by high IOP. To our knowledge this concept has not been previously expressed and represents a useful addition to the clinical care of glaucoma patients.

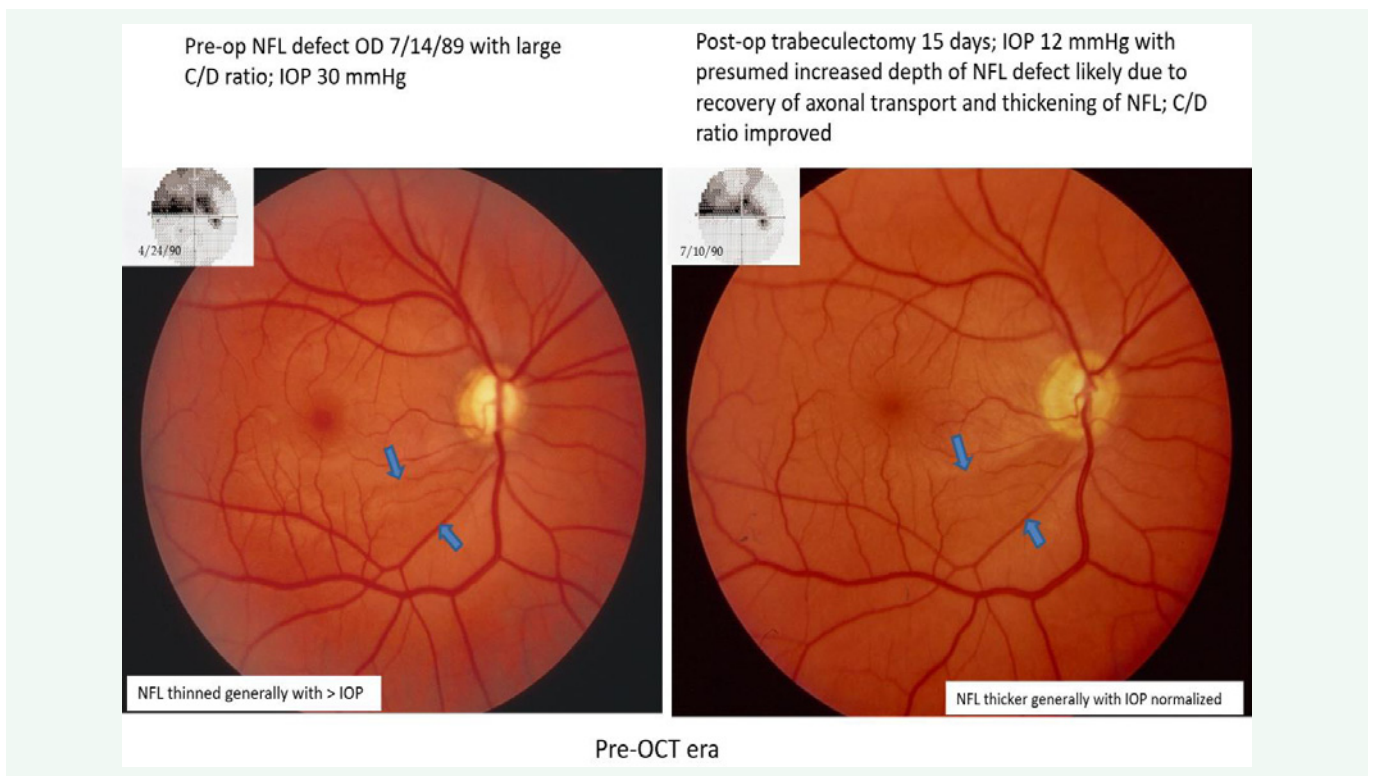


Figure 1 29-year-old male IOP 30 COAG.

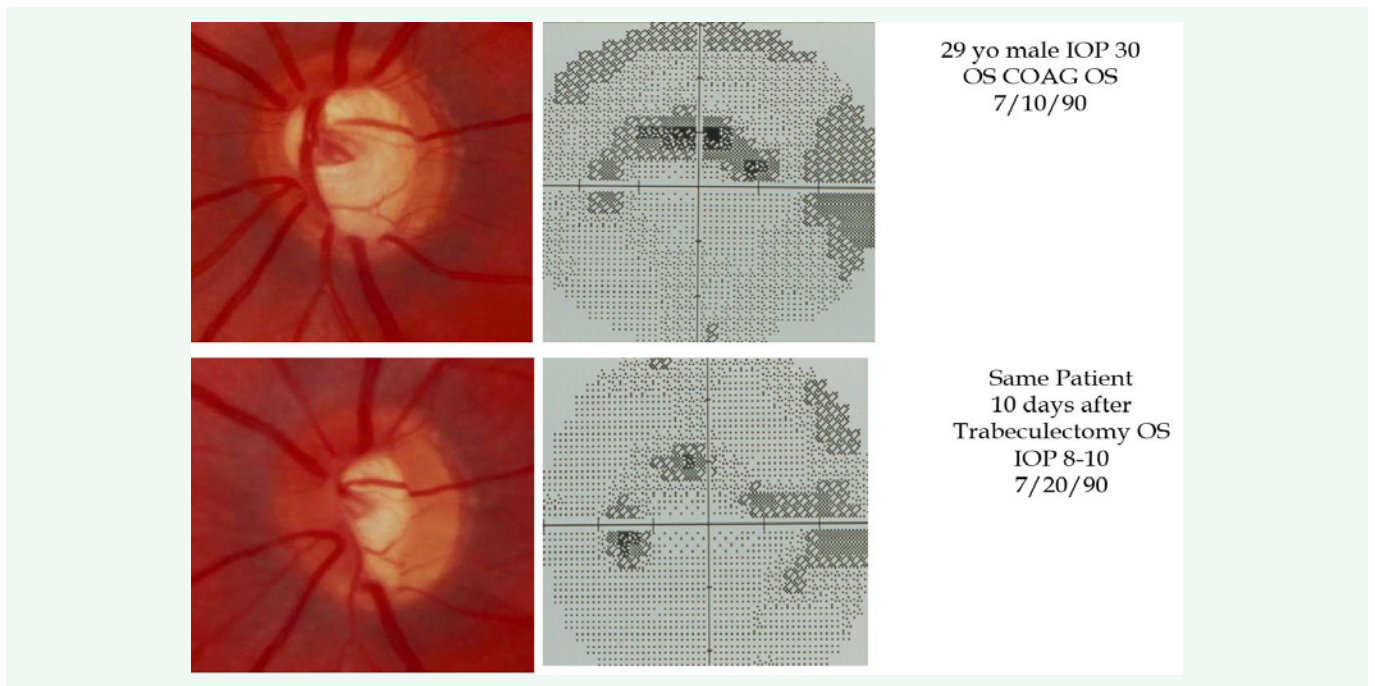


Figure 2 Disc & Visual Field Changes after IOP Lowering OS.