

Short Communication

Iris Transillumination Defect Spectrum in Pigment Dispersion Syndrome

Daniel K. Roberts^{1,4,5*}, Yongyi Yang^{2,3}, Ana S. Lukic^{2,3,4}, Jacob T. Wilensky⁴ and Miles N. Wernick^{2,3}

¹Department of Clinical Education, Illinois Eye Institute, Illinois College of Optometry, USA

²Department of Electrical and Computer Engineering, Illinois Institute of Technology, USA

³Predictek Inc., USA

⁴Department of Ophthalmology and Visual Sciences University of Illinois at Chicago, USA

⁵Division of Epidemiology and Biostatistics, University of Illinois at Chicago, USA

*Corresponding author

Daniel K. Roberts, Illinois Eye Institute, 3241 S. Michigan Avenue, Chicago, Illinois, USA 60616, Tel: 312-949-7318; Fax: 312-949-7379; Email: droberts@ico.edu

Submitted: 24 September 2013

Accepted: 15 October 2014

Published: 17 October 2014

Copyright

© 2014 Roberts et al.

OPEN ACCESS

Pigment dispersion syndrome (PDS), characterized by iris-zonule rubbing and pigment liberation, is important due to possible secondary glaucoma [1,2]. Signs include pigment dusting of the cornea, anterior iris stroma, iridocorneal angle, and equatorial lens region. Mid-peripheral iris transillumination defects (ITDs) can be pathognomonic for “classic” PDS and may help differentiate it from other causes of pigment dispersal, especially when other clinical signs are mild, absent, or atypical. Despite their importance, the spectrum of clinical variation of PDS-related ITDs has been minimally studied and is not well-understood, most likely resulting from limited access to sensitive means to detect and record iris transillumination (Figure 1) [3].

Using near infrared iris transillumination imaging [3] we examined PDS subjects within a single urban eye care facility in Chicago, Illinois, U.S.A., and with this group we briefly illustrate the potential variation of iris transillumination patterns because they may diverge from classical descriptions. These observations deserve emphasis as they may be helpful to clinical diagnosis, phenotypic classification, and research.

The examples shown are not intended to mirror the full spectrum of PDS and related iris transillumination from this institution or elsewhere (Table 1), but rather to simply help illustrate phenotypic variation. The eyes we show here were selected from a multiracial/ethnic group of subjects (14 African-Americans, 13 Whites, 3 Hispanics; 17 females/13 males; median age=46 years; range=25-68 years) who had classic PDS based on moderate-to-heavy trabecular pigment and a Krukenberg's spindle, both combined with equatorial lens pigment (Scheie line) and/or mid-peripheral ITDs. The rationale of using equatorial lens pigment as a potential hallmark sign in lieu of ITDs has been discussed elsewhere and is considered important to help “capture” those subjects who don't exhibit discernible ITDs with or without specialized methods [4]. All of the subjects had evaluation to rule out other disorders, which included ocular/medical history, refraction, slit lamp biomicroscopy, Goldmann tonometry, gonioscopy, and dilated fundus exam.

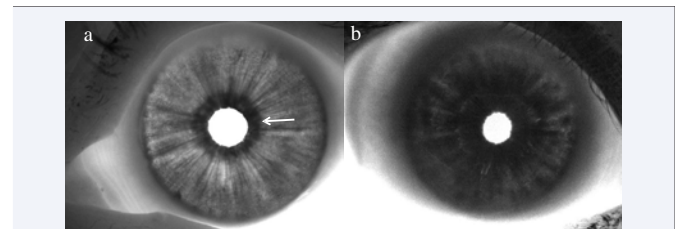


Figure 1 Near-infrared iris transillumination imaging of example normal eyes. (a): Hazel iris of a 64-year-old White female. The iris sphincter muscle is evident (arrow), and radial folds along the posterior iris are also visualized. (b): Dark-brown iris of a 41-year-old African-American female.

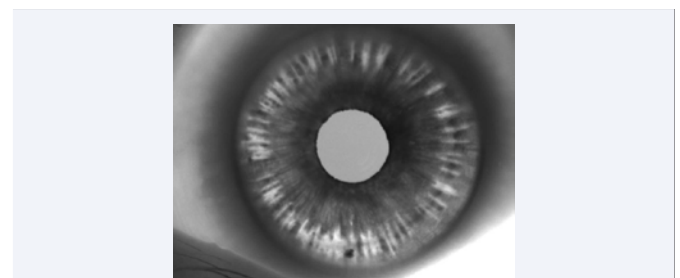


Figure 2 Typical spoke-like ITDs in hazel iris (left eye) of a 29-year-old White female (Subject 1) with PDS.

Based on our subjects alone, a quite variable ITD spectrum was evident, with some having mid-peripheral ITD patterns that were clearly “spoke-like” and similar to classical descriptions (Figure 2), but others having mid-peripheral defects that were not spoke-like. Non-spoke-like ITDs could appear as well-defined, focal patches (Figure 3), or they could be indistinct and rather amorphous in shape (Figure 4). Circumferential, mid-peripheral ITD rings could also occur, without hint of spokes in any clock hour (Figure 5). While it appeared that simple coalescence of multiple spoke-like ITDs accounted for amorphous ITDs in some eyes, this was not evident in others. Even with the increased

Table 1:

Subject	Age	Race	Sex	Iris Color	Eye	†Refractive Error	KS	††TM Pigment	§ITDs	Equatorial Lens Pigment	‡Elevated IOP	‡‡Glaucoma
1	29	W	F	Hazel	RE	-9.25	Y	Y	Y	Y	N	N
					LE	-7.25	Y	Y	Y	Y	N	N
2	67	AA	M	Dark Brown	RE	-0.5	Y	Y	Y	Y	Y	Y
					LE	-6.75	Y	Y	N	N	Y	N
3	63	H	M	Dark Brown	RE	-10.75	Y	Y	Y	Y	N	N
					LE	-8.25	Y	Y	Y	Y	N	N
4	68	AA	F	Dark Brown	RE	-0.5	Y	Y	Y	Y	Y	N
					LE	0.5	Y	Y	Y	Y	Y	N
5	56	AA	F	Dark Brown	RE	-2.25	Y	Y	N	Y	Y	N
					LE	-0.75	Y	Y	N	Y	Y	N
6	48	H	M	Dark Brown	RE	-1	Y	Y	?	Y	N	N
					LE	-1	Y	Y	?	Y	N	N

Abbreviations: AA: African-American; F/M: Female/Male; H: Hispanic; IOP: Intraocular Pressure; ITDs: Iris Transillumination Defects; KS: Krukenberg's Spindle; TM: Trabecular Meshwork; RE/LE: Right Eye/Left Eye; W: White;
†Subjective refraction, reported as spherical-equivalent
††Moderate-to-heavy trabecular meshwork/angle pigment
§ITDs detected via near infrared transillumination imaging
‡Intraocular pressure ≥ 22 mm Hg on at least one occasion.
‡‡Glaucoma diagnosis based on presence of characteristic optic nerve cupping and threshold visual field defects

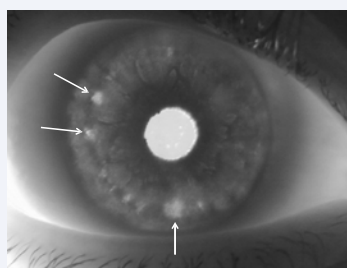


Figure 3 Focal and patch-like ITDs (arrows) in dark-brown iris (right eye) of a 67-year-old African-American male (Subject 2) with PDS and glaucoma.

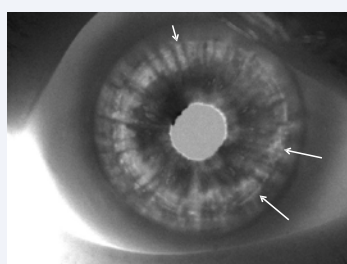


Figure 4 Indistinct spoke-like (short arrow) and amorphous ITDs (long arrows) in dark-brown iris (right eye) of a 63-year-old Hispanic male (Subject 3) with PDS.

sensitivity of near infrared imaging, some eyes with other prominent PDS signs still showed little or no evidence of clearly abnormal iris transillumination (Figure 6).

Of interest following our survey of collected images was that we did not detect well-defined ITD spokes in any of our African-American subjects. Thus, we conjecture that more darkly-pigmented eyes may not only be less likely to exhibit ITDs [5],

but they may also be less likely to have classic and spoke-like ITDs when ITDs do occur. Although study of more subjects will be needed to clarify a broader overview, these examples alone highlight that a "spectrum" of ITD patterns exists, which should

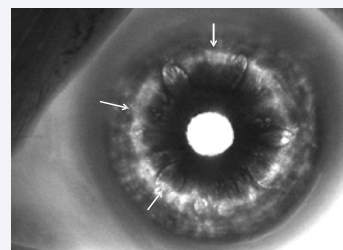


Figure 5 Ring-like ITD pattern (arrows), without hint of spoke-like ITDs, in left eye of a 68-year-old African-American female (Subject 4) with dark-brown irides, dense Krukenberg's spindles, moderate trabecular and equatorial lens pigment, and ocular hypertension. No ITDs were detectable with regular slit lamp exam.

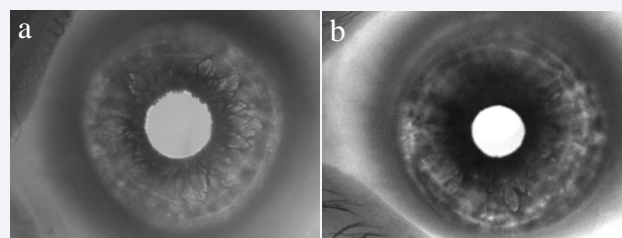


Figure 6 (a): 56-year-old African-American female (Subject 5) without overt ITDs, had dark-brown irides, dense Krukenberg's spindles and trabecular pigment, and mild equatorial lens pigment. She had elevated intraocular pressure without glaucoma. (b): A 48-year-old Hispanic male (Subject 6), with dark-brown irides, Krukenberg's spindles, moderate trabecular pigment, and equatorial lens pigment, showed possible mild amorphous ITDs.

be a consideration when establishing criteria to identify PDS phenotypes during clinical care and research.

ACKNOWLEDGEMENTS

Support: NIH grant EY015604 (ASL).

Disclosure: DKR, MNW, AL, and YY are patent holders related to infrared imaging.

REFERENCES

1. Farrar SM, Shields MB. Current concepts in pigmentary glaucoma. *Surv Ophthalmol*. 1993; 37: 233-252.
2. Karickhoff JR. Pigmentary dispersion syndrome and pigmentary glaucoma: a new mechanism concept, a new treatment, and a new technique. *Ophthalmic Surg*. 1992; 23: 269-277.
3. Roberts DK, Lukic AS, Yang Y, Moroi SE, Wilensky JT, Wernick MN. Novel observations and potential applications using digital infrared iris imaging. *Ophthalmic Surg Lasers Imaging*. 2009; 40: 207-216.
4. Roberts DK, Meetz RE, Chaglasian MA. The inheritance of the pigment dispersion syndrome in blacks. *J Glaucoma*. 1999; 8: 250-256.
5. Qing G, Wang N, Lu Q, Zhang S. Different transillumination property in Chinese and White irides. *J Glaucoma*. 2012; 2: 107-111.

Cite this article

Roberts DK, Yang Y, Lukic AS, Wilensky JT, Wernick MN (2014) Iris Transillumination Defect Spectrum in Pigment Dispersion Syndrome. *JSM Ophthalmol* 2(1): 1010.