

## Short Communication

# Corneal Epithelial Cyst with Inclusion: About One Case

Laayoun J, Elmellaoui M, Iferkhas S, Zaoui K, Bouzidi A, Laktawi A, and Douhal A

3rd hospital - service ophtalmologie- Guelmim- MOROCCO

**\*Corresponding author**

Jaouad Laayoun, 3rd hospital-service ophtalmologie- Guelmim- MOROCCO, Email : jaouad@hotmail.com

Submitted: 09 February 2016

Accepted: 18 March 2016

Published: 21 March 2016

ISSN: 2333-6447

Copyright

© 2016 Laayoun et al.

OPEN ACCESS

**Abstract**

**Introduction:** The corneal epithelial inclusion cyst is a rare condition that can affect all layers of the cornea that the trigger would be an old trauma.

**Materials and methods:** A 32 year old patient, admitted for a painful right eye with visual loss and leucocoria. In its history, there is a notion of former corneal trauma.

**Results:** On admission can be found on the right eye a white mass, localized in upper temporal quadrant of the cornea.

**Discussion:** The corneal epithelial inclusion cyst can develop after several events including a corneal ulcer, penetrating trauma or intraocular surgery. Its pathogenesis lies in the movement and proliferation of epithelial cells in the corneal stroma.

**Conclusion:** The aim of surgical treatment is both to eradicate the cyst and to achieve better visual results.

**Keywords**

- Corneal cyst
- Epithelial cells
- Keratectomy

## INTRODUCTION

The corneal epithelial inclusion cyst is a rare condition that can affect all layers of the cornea, the initial lesion is an incarceration of epithelial cells into stroma following intra cystic changes and accumulation of sloughed cells. The etiology of the corneal epithelial inclusion cyst remains unclear, and the relationship with a former trauma or corneal ulcer is not yet established. However, most of the reported cases have revealed the existence of surgical trauma or accidental corneal wound as trigger.

## MATERIAL AND METHODS

In our work, we report the case of a 32 year old patient, admitted for consultation of ophthalmology of the Hospital Moulay Ismail in Meknes for a painful right eye with visual loss and leucocoria in the background, there is a notion of accidental nail trauma in the right eye occurred a year before with a good clinical outcome with topical antibiotics.

## RESULTS

On admission can be found on the right eye a white mass, localized in of upper temporal quadrant of the cornea (Figure 1).

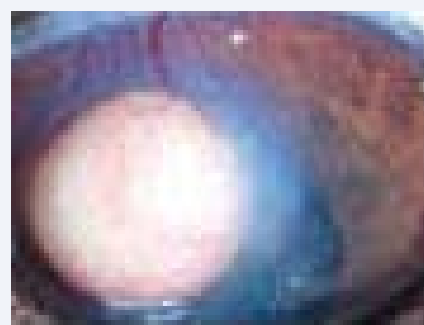This mass is measuring 6mm wide and 3mm in height. It also notes the existence of a corneal edema with vessels on and around the cyst. The examination at the slit lamp shows an invasion of the corneal epithelium and anterior stroma. The Schirmer test was 19 and 17mm to the left and right eyes respectively. The

intraocular pressure was 16 mmHg and 17 to left and right respectively. The fluorescein test was negative and the normal eye background in both eyes. The presumptive diagnosis was then to corneal epithelial cyst inclusion of the right eye. Then an excision by keratectomy was performed (Figure 2).


This is cytological study of the cyst revealed intact epithelial cells degenerate and which confirmed the diagnosis of corneal epithelial inclusion cyst. In immediate post-operative antibiotic treatment was initiated with establishment of a therapeutic lens for faster re-epithelialization. The evolution was good with disappearance of the cyst after 6 months (Figure 3).

## DISCUSSION

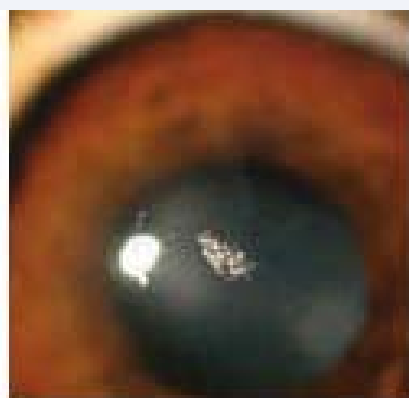
The corneal epithelial inclusion cyst can develop after



**Figure 1** Upper temporal quadrant of the Cornea.



**Figure 2** Corneal edema with vessels on and around the cyst.



**Figure 3** Cyst revealed intact epithelial cells degenerate.

several events including a corneal ulcer, penetrating trauma or intraocular surgery. Keratotomy, keratoplasty and epithelial dystrophies with recurrent erosions are also possible causes. Its pathogenesis lies in the movement and proliferation of epithelial cells in the corneal stroma. In rare cases, the cyst may

disappear spontaneously, probably by spontaneous drainage in the anterior chamber [2]. In most cases, the cysts are unique and have an oval configuration. Some cysts contain white cream materials, as in our case. Others may contain epithelial debris in the lower part of cyst resulting from pseudohypopyon [1]. If the visual axis is threatened or involved with a cyst of the corneal epithelium, surgery may be necessary. A simple drainage or suction procedure may be performed, but in most cases, cysts recur within a short time [4]. The excision of the anterior wall of the cyst (as in our case) with or without destruction of epithelial cells by chemicals can reduce the recurrence rate [3].

## CONCLUSION

While the lamellar or penetrating keratoplasty was associated with several drawbacks and requires long-term monitoring, it is recommended to use the refractive keratoplasty in the case of a cyst with extension at depth of the stroma and/or obstruction of the visual axis, and this in order both to eradicate the cyst and to achieve better visual results.

## REFERENCES

1. Rao SK, Fogla R, Biswas J, Padmanabhan P. Corneoscleral epithelial cysts: evidence of developmental etiology. *Cornea*. 1998; 17: 446-450.
2. Al-Towerki AE, Binali G. Traumatic epithelial inclusion cyst of the anterior corneal stroma. *Cornea*. 2008; 27: 368-369.
3. Ali Javadi M, Sharifi A, Hashemian SJ, Yazdani S, Parvizi G, Kanavi MR. Management of intracorneal epithelial cysts with ethanol irrigation and cyst wall excision: A clinicopathologic report. *Cornea*. 2006; 25: 479-481.
4. James C, Liu MD. Conjunctival, corneal, or scleral cyst (epithelial inclusion cyst, intrastromal corneal cysts) In: Roy F, editor. *Current Ocular Therapy*. 5th ed. Philadelphia: WB Saunders. 2000; 347-348.

### Cite this article

Laayoun J, Elmellaoui M, Iferkhas S, Zaoui K, Bouzidi A, et al. (2016) Corneal Epithelial Cyst with Inclusion: About One Case. *JSM Ophthalmol* 4(1): 1039.